

Ghazal Aarabi, Götz Thomalla, Carolin Walther, Carola Mayer, Thomas Beikler, Guido Heydecke, Udo Seedorf*

Periodontitis as potential risk factor for Alzheimer's disease

Introduction: Neuroinflammation is a hallmark of Alzheimer's disease (AD). Multiple infectious agents have been demonstrated in the brain and proposed to be involved in AD, but robust evidence of causation has not yet been established. It was hypothesized that periodontitis (PD) and infection with *Porphyromonas gingivalis* may be linked to onset and progression of AD. Although inflammation is present in both diseases, the exact mechanisms and interactions between periodontitis and AD are poorly understood.

Method: In this narrative review, we highlight recent progress in exploring potential associations of PD with AD and its surrogates (amyloid plaques) and clinical sequelae (i.e. dementia), respectively.

Discussion and Result: Recent evidence suggests that periodontitis interacts with AD to increase the severity of clinical dementia and to accelerate its manifestations. These results indicate that periodontitis may be an emerging risk factor for AD and that the risk may be mediated directly by *Porphyromonas gingivalis* and its secreted neurotoxic gingipains. The recent development of an oral gingipain inhibitor, which is currently tested in a randomized controlled trial, offers the unique opportunity to verify the infectious hypothesis of AD. If successful, this research can be expected to result in a significant improvement of prevention and treatment of PD and AD.

Keywords: periodontitis; Alzheimer's disease; *Porphyromonas gingivalis*; gingipain; neuroinflammation; dementia; oral prophylaxis; therapy

Department of Prosthetic Dentistry, Center for Dental and Oral Medicine, University Medical Center Hamburg-Eppendorf, Germany: PD Dr. Ghazal Aarabi, Dr. Carolin Walther, Prof. Dr. Guido Heydecke, Prof. Dr. Udo Seedorf

Department of Neurology, Head- and Neurocenter, University Medical Center Hamburg-Eppendorf, Germany: Prof. Dr. Götz Thomalla, Carola Meyer

Department of Periodontics, Preventive and Restorative Dentistry, University Medical Center Hamburg-Eppendorf, Germany: Prof. Dr. Thomas Beikler

* Corresponding Author

Citation: Aarabi G, Thomalla G, Walther C, Mayer C, Beikler T, Heydecke G, Seedorf U: Periodontitis as potential risk factor for Alzheimer's disease. Dtsch Zahnärztl Z Int 2021; 3: 121–128

Peer-reviewed article: submitted: 15.04.2020, revised version accepted: 22.06.2020

DOI.org/10.3238/dzz-int.2021.0014

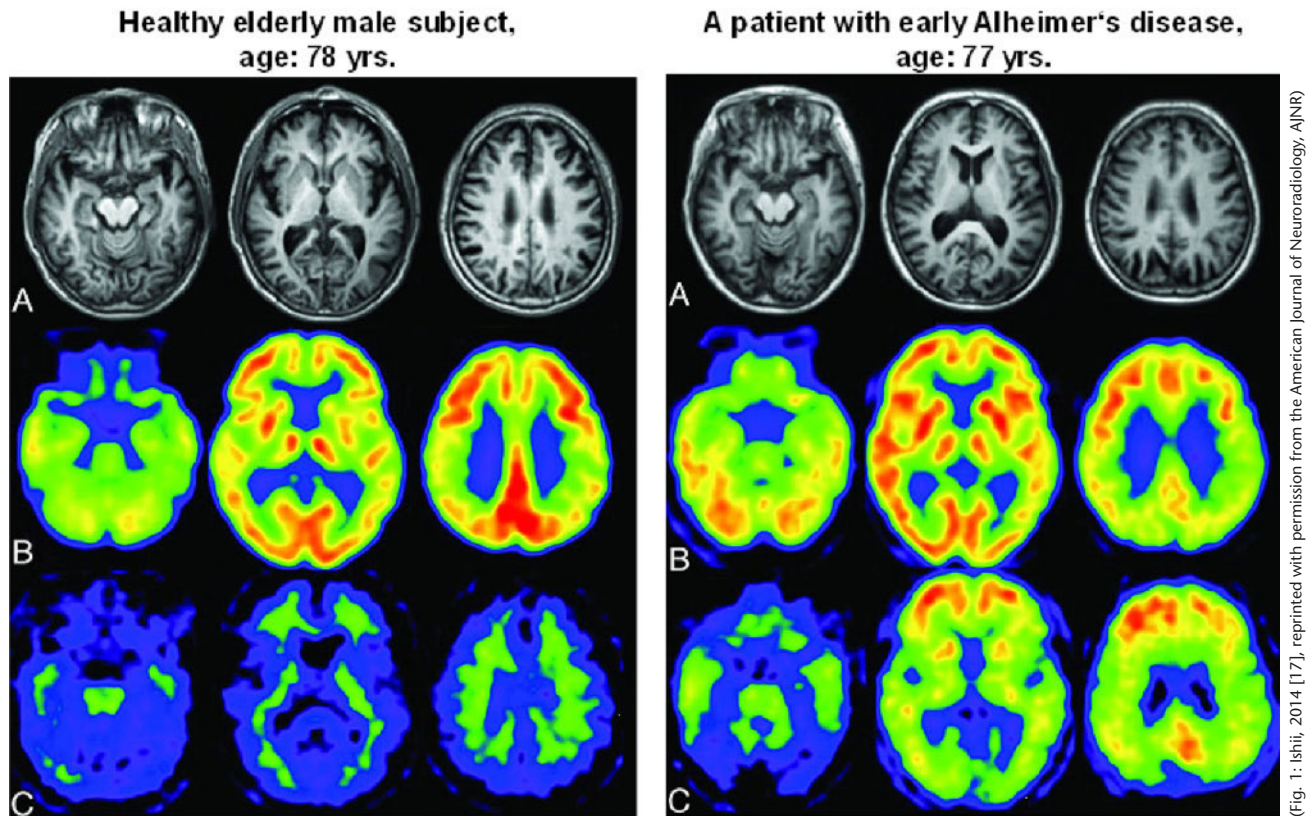


Figure 1 Diagnosis of Alzheimer's disease by non-invasive imaging. **Left:** Healthy elderly male subject, age: 78 years, Mini-Mental State Examination score: 30. **(A)** Note the slightly enlarged right inferior horn of the lateral ventricle on the T1-weighted MR image. **(B)** Note that the regional glucose metabolism is not reduced on the FDG-PET images. Note that glucose metabolism in the posterior cingulate is much larger than that in other regions. **(C)** PiB-PET reveals nonspecific accumulation in the white matter but no PiB accumulation in the gray matter. The amyloid deposit is negative. **Right:** Patient with early Alzheimer's disease, age: 77 years, Mini-Mental State Examination score: 25. **(A)** Note the slight atrophy of the right hippocampus. **(B)** FDG-PET reveals diminished glucose metabolism in the bilateral parietotemporal association cortices and posterior cingulate gyri and precuneus. **(C)** PiB accumulation is seen in the cerebral cortices except for the occipital and medial temporal regions. High PiB accumulation is present in the medial parietal and frontal regions, indicative of positive amyloid deposit [17].
FDG = [18F]-fluorodeoxyglucose; PET = positron emission tomography; PiB = Pittsburgh Compound.

Introduction

In Germany, approximately 1.2 million mostly elderly people suffer from dementia (GDB 2016 Dementia Collaborators, 2019). The number of people living with dementia has increased significantly in the last 3 decades due to ageing. Despite of some evidence of minor decreases in the age-specific incidence rates [48], further increases in the number of people affected by dementia may be expected due to the prevailing demographic trends. Limited starting points for prevention and the absence of an effective treatment suggest that the dementia-related burden on patients, caregivers, and the health-care system will likely continue to rise.

Dementia is a neurodegenerative disease in which neurons are grad-

ually lost. The most common forms are Alzheimer's disease (AD) and vascular dementia, which together account for approximately 85 % of all cases [14]. While AD is caused by protein deposits called amyloid plaques or senile plaques in the brain (Fig. 1), vascular dementia is due to a circulatory disorder resulting in a diminished cerebral oxygen supply. Well established risk factors for vascular dementia are hypertension, heart disease, diabetes, high cholesterol levels (hyperlipidemia), obesity, physical inactivity, and smoking [12]. Age and the $\epsilon 4$ allele of apolipoprotein E are major established risk factors for the frequent multifactorial forms of AD [12]. In addition, rarer familial forms exist, which are primarily due to high-penetrance mutations in amyloid precursor protein (APP), preseni-

lin 1 (PSEN1), and presenilin 2 (PSEN2). Together, these mutations explain only 5–10 % of the occurrence of early-onset AD (reviewed by [45]).

Previous research supports that chronic inflammatory processes play a pivotal role in AD dementia [24, 43, 49]; but the events that trigger inflammation in the first place are still unclear. One repeatedly postulated possibility is that AD associated inflammation may result from an infectious etiology [31]. Multiple infectious agents, including Cytomegalovirus (CMV), herpes simplex virus types 1 and 2 (HSV-1, HSV-2), *Helicobacter pylori*, *Chlamydomphila pneumoniae*, *Borrelia burgdorferi*, and *Porphyromonas gingivalis* have been demonstrated in the brain and proposed to be involved in AD, but robust evi-

dence of causation has not yet been established [28, 37]. Extracellular amyloid- β (A β) deposits, which accumulate in the gray matter of the brain, are a hallmark of the AD. It could be demonstrated A β belongs to an evolutionarily conserved family of proteins, collectively known as antimicrobial peptides (AMPs) [19, 39]. AMPs act as a first-line of defense against a large range of pathogens including bacteria, mycobacteria, viruses, fungi, and protozoans [47]. Mice lacking the amyloid precursor protein (APP) show an attenuated survival rate after bacterial infection and it is assumed that oligomerization and fibrillization is required for A β 's antimicrobial activity [25]. The recent finding that A β has antimicrobial activity has motivated the scientific community to verify a possible infectious cause of AD [25, 39, 40]. It was hypothesized that periodontitis (PD) and infection with *Porphyromonas gingivalis* may be linked to onset and progression of AD. Although inflammation is present in both diseases, the exact mechanisms and interactions between PD and AD are poorly understood. The impact of inflammation on vascular dementia and its association with PD

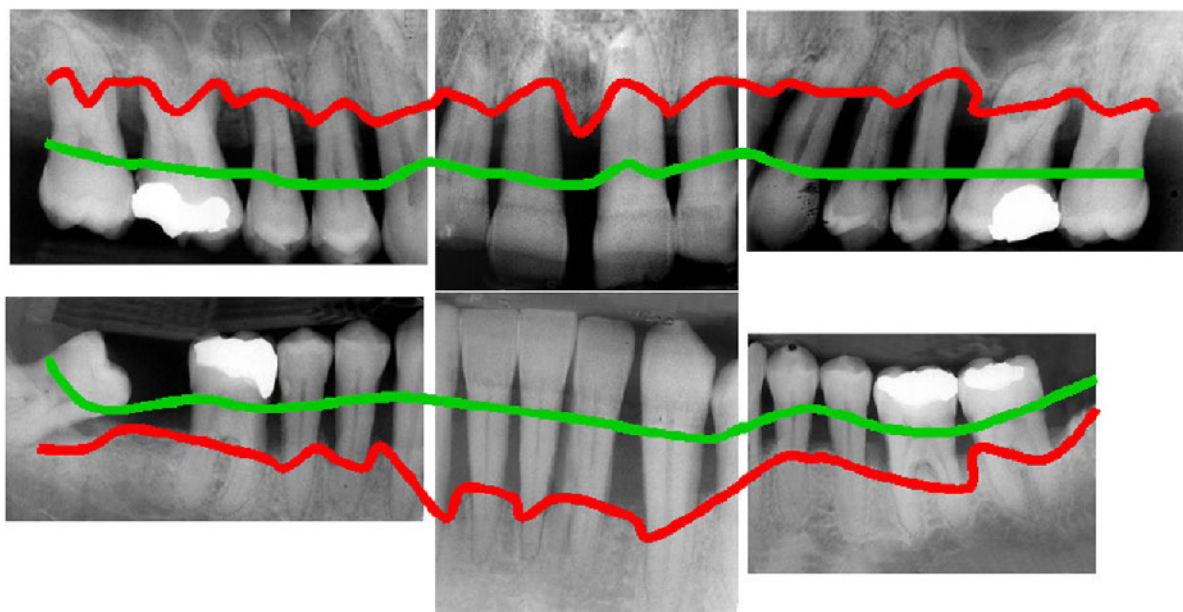
was discussed comprehensively in a recent review by Aarabi et al. [1]. Thus, this narrative review aims at presenting and evaluating recent progress in exploring potential associations of infections with *Porphyromonas gingivalis* with AD and its clinical sequelae, i.e. dementia and mild cognitive impairment (MCI). In AD, PD was shown to be associated with increased dementia severity and more pronounced cognitive decline, thus indicating a link to an increased systemic pro-inflammatory state [15]. An example of a case of severe generalized PD is shown in Figure 2.

Methodology

The search strategy for this review was developed in view of our aim to find and present recent evidence supporting an infectious etiology of AD and the potential contribution of *Porphyromonas gingivalis* to AD and its clinical sequelae, i.e. dementia and mild cognitive impairment (MCI). The literature search was restricted to PubMed, PMC (NCBI) and Web of Science SCI with the following search terms: 1) Oral medicine: oral infection, periodontitis, gingivitis, bleeding on probing, gum disease, tooth-loss, endodontic lesion OR infection,

apical OR periapical abscess, *Porphyromonas gingivalis*, *Porphyromonas endodontalis*, *Streptococcus mutans*, GroEL, lipopolysaccharide. 2) Neurology: Alzheimer's disease, dementia, cognitive decline, brain, amyloid plaques or senile plaques, magnetic resonance imaging OR tomography, CT OR computer tomography. 3) Inflammation: autoimmunity, C-reactive protein OR CRP, interleukin, periodontitis, oral infection, systemic inflammation, acute phase, endothelial AND function OR dysfunction. Other: epidemiology.

Search terms of each subject area were combined logically and resulted in 230 hits, which were recorded and screened by GA and US manually and categorized *a priori* relevant or interesting. Excluded were non-peer-reviewed studies and studies with insufficient sample sizes to yield at least a statistical power of 80 % to detect the claimed effects. Also studies that were prone to the possibility of reverse causation (typically case-control studies comparing the frequency of periodontitis in healthy subjects and dementia patients) were excluded (18 publications). Animal studies that had no direct relationship to human AD (21 publications),



(Fig. 2: T. Beikler)

Figure 2 Example of severe periodontitis with the typical presentation of loss of alveolar bone. The x-ray shows teeth exhibiting generalized severe bone loss of 30–80 %. The red line marks the actually existing bone level. The green line shows where the original bone level was before the patient developed periodontitis. Periodontitis is an inflammatory disease and *Porphyromonas gingivalis* as well as a number of other mostly Gram-negative anaerobe bacteria play a key role in its pathogenesis.

and studies that concerned with dementia rather than with AD (146 publications) were also excluded. This prescreening procedure resulted in 45 proposed references (98.3 % agreement between both authors, Cohen's kappa: 0.95), which were stored in an Endnote web database that was accessible to all authors, who decided consensually which publication should be referenced based on the article's content (41 publications) and 8 additional references resulting from manual searches were added during peer-reviewing. This procedure resulted in the 49 references cited in this review.

Association between chronic oral infections and dementias

Chronic oral infections such as PD may be able to modulate the risk of AD dementia. In the Third National Health and Nutrition Examination Survey (NHANES-III), a large representative cross sectional observational study among 2,355 participants ≥ 60 years of age, PD was associated with cognitive decline, which is considered to be a precursor of dementia [30]. However, the type of dementia was not assessed and brain MRI was not available for the study. A reduced number of teeth – a frequent cause of a past PD – increased the risk of higher prevalence and incidence of dementia of all causes in the Nun Study [27, 41]. The Nun Study is a longitudinal survey on aging and AD of nearly 700 nuns from across the United States. Its strength relates to the fact that AD diagnosis was performed *post mortem* to ensure a high sensitivity and specificity of the AD diagnosis. In addition, the dental records were complemented with results from cognitive tests longitudinally over a long period of time.

Data from the U.S. Department of Veterans Affairs Dental Longitudinal Study (VA-DLS) of almost 600 men aged 28 to 70 at entry who had been followed for up to 32 years showed that the risk of cognitive decline increased with the number of lost teeth and that also PD and caries lesions were associated with cog-

nitive decline [21]. Gatz et al. evaluated data from the Swedish Twin Registry to identify potentially modifiable risk factors for AD. The most consistent risk factor for AD was tooth loss before the age of 35. Low educational status also associated with the risk for dementia and lack of physical exercise associated with the risk for non-Alzheimer's dementia [9]. However, tooth loss is a poor outcome measure because tooth loss may have an adverse influence on diet. Thus, a poor diet and not the periodontal inflammation *per se* may have been the causal factor underlying the observed association in these studies.

The hypothesis that PD may be associated with A β deposits in the brain was also investigated by positron emission tomography imaging, which enabled non-invasive imaging of these deposits [20]. The study included 38 healthy elderly men and women. After adjusting for confounders, clinical attachment loss of ≥ 3 mm was associated with elevated A β in affected brain regions ($p = 0.002$) [20]. There are a number of additional studies that supported an association between dementia and periodontal disease or tooth loss (reviewed by [44]). Although these studies had limitations, such as small sample sizes, lack of rigorous criteria to diagnose PD and differentiate between different types of dementia, and the possibility of reverse causation, the evidence for an association between PD and dementia or AD nevertheless appears to be rather solid, thus raising questions about possible mechanisms underlying these findings.

How periodontal pathogenic bacteria cross blood-brain barriers

Key pathogens involved in the pathogenesis of PD are, amongst others, *Porphyromonas gingivalis* and *Treponema denticola* [23], which colonize deep periodontal pockets. Serum IgG antibody levels to *Porphyromonas gingivalis* were shown to be associated with an increased incidence of AD and AD progression [30, 41], suggesting an involvement of *Porphyromonas gingivalis* in AD.

In general, the blood-brain barrier protects the brain against exposure to bacteria and other toxic agents. However, there are 2 main routes *via* which bacteria may cross an impaired blood-brain barrier and enter the brain: first, by bacteremia and second, by migrating along the trigeminal nerve (mouth brain axis) [34, 43]. Pro-inflammatory cytokines that are triggered by *Porphyromonas gingivalis* and other periodontal pathogens are secreted from the infected sites at the periodontium, enter the blood stream and reach the brain via the circulation and weaken the blood-brain barrier by inducing a proinflammatory state favoring cerebral small vessel disease (CSVD). Moreover, *Porphyromonas gingivalis* can infect endothelial cells and stimulate the expression of endothelial adhesion molecules, which may promote monocyte/macrophage adhesion and infiltration into the endothelial layer of the blood-brain barrier [46]. Thus, infections with *Porphyromonas gingivalis* may contribute to the destruction of the blood-brain barrier via inflammation during CSVD. Imaging markers of CSVD were found to be associated with cognitive decline in elderly people affected by AD [7, 8]. The subgingival biofilm is composed mostly of lipopolysaccharide (LPS)-producing Gram-negative bacteria [38], some of which can trigger inflammatory responses in the brain [2], damage the blood-brain barrier in animal models of AD [18], and stimulate the production of A β peptides by neurons [26]. *Porphyromonas gingivalis* has the ability to impair the blood-brain barrier by gingipain-mediated degradation of the junctional adhesion molecule (JAM1), a tight junction-associated protein that regulates the epithelial barrier function [42]. Gingipains cleave JAM1 specifically at residues K134 and R234, resulting in permeability of the epithelium to LPS, and proteoglycan (PGN). Knockdown of JAM1 in cultured cells increased the permeability to LPS, PGN, and gingipains [42]. Thus, bacterial toxins may be able to penetrate the brain *via* the damaged blood-brain barrier. Moreover, oral bacteria may access

the brain via infection of monocytes followed by brain recruitment [5, 11] or direct infection of endothelial cells, which protect the blood-brain barrier [36].

Passage through the trigeminal nerve is supported by the observation that higher levels of periodontal pathogen *Treponema* could be detected in the brain and the trigeminal nerve of AD patients than in unaffected controls [34]. The trigeminal nerve innervates the oral cavity and connects it with the central nervous system. Compared to periodontally healthy subjects, patients with PD have a higher risk for trigeminal neuralgia, which is characterized by recurrent paroxysmal pain within the distribution of the trigeminal nerve [22].

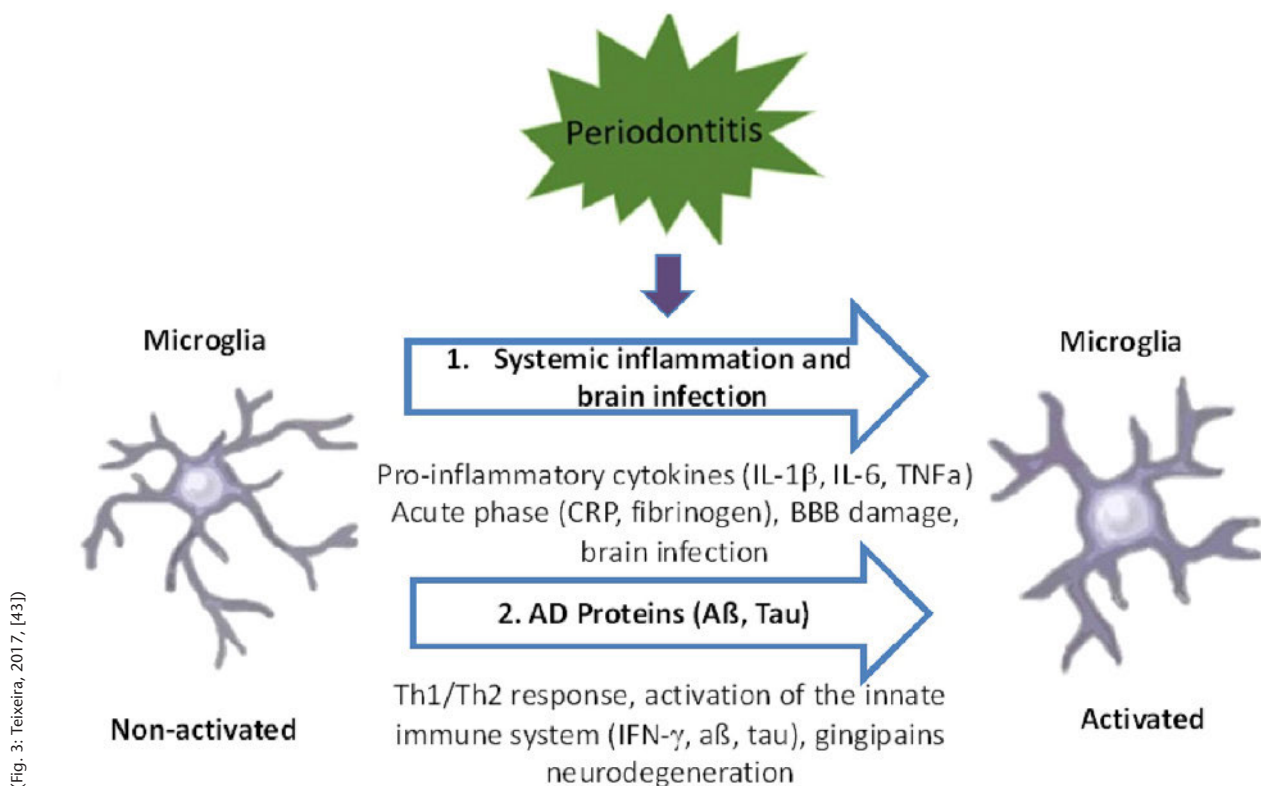
The most likely mechanism employed by *Porphyromonas gingivalis* and the gingipains for passage through the nerve is axonal transport using the axonal transport ma-

chinery. It could be demonstrated, for instance, that the rabies virus enters the central nervous system by retrograde axoplasmic flow [29], the tetanus neurotoxin is retrogradely transported towards the soma in signaling endosomes after uptake at the neuromuscular junction [3] and the HSVs are transported inside the nerve in transport vesicles along with APP [4, 35]. However, whether *Porphyromonas gingivalis* and the gingipains reach the CNS via axonal transport and whether they are also co-transported with APP is currently unclear.

Detection of *Porphyromonas gingivalis* and gingipains in the brain

Experimental disruption of the trigeminal nerve led to age-dependent loss of cholinergic neurons in learning and memory-related brain regions and impaired learning in a mouse model of AD (SAMP8 mice

[13], suggesting that the integrity of the trigeminal nerve, which may be impaired by oral infections, is crucial for these brain functions. Oral infection of ApoE knockout mice with *Porphyromonas gingivalis* led to sustained brain infections and activation of the complement pathway [32]. In transgenic mice over-expressing a mutated form of the human APP, oral infection with *Porphyromonas gingivalis* impaired the cognitive function and increased the buildup of AD-like deposits together with alveolar bone loss compared to non-infected mice [16]. *Porphyromonas gingivalis*, the key stone bacterium of PD, was recently detected in the brains of AD patients for the first time *post mortem* [6] and *Porphyromonas gingivalis* gingipains and LPS have also been detected in human AD brains [6, 33]. One of the first brain regions to be damaged in AD is the hippocampus. The study by Dominy et al. could demonstrate



(Fig. 3: Teixeira, 2017, [43])

Figure 3 Periodontitis, *Porphyromonas gingivalis*, gingipains, and Alzheimer's disease. Periodontitis is a bacteria-induced chronic inflammation of the tooth supporting structures. *Porphyromonas gingivalis* is a key pathogen involved in the pathogenesis of periodontitis. The periodontal inflammation triggers bacteremia of *P. gingivalis*, a systemic inflammation, and a pro-inflammatory acute phase reaction, which lead to blood-brain barrier (BBB) damage. *P. gingivalis* has the ability to infect the brain via the damaged BBB or other means, such as the trigeminal nerve. The brain infection, which is also linked to gingipain-mediated neurodegeneration, triggers a Th1/Th2 inflammatory response and activation of the brain's innate immune system (interferon-γ (IFN-γ) leading to accumulation of fibrillar amyloid β (Aβ), and tau. Figure adopted from figure 1 in reference [43].

gingipain RgpB in neurons of the dentate gyrus and CA3, CA2, and CA1 of the hippocampus [6]. In addition, RgpB co-localized primarily with neurons and astrocytes as well as with tau tangles, and intra-neuronal A β , but not with microglia, which was consistent with the proposed roles of *Porphyromonas gingivalis* in the pathogenesis of AD.

Implications for treatment of Alzheimer's disease

To date, several classes of gingipain inhibitors have been described. These include inhibitors from natural sources, synthetic compounds, antibiotics, antiseptics, antibodies, and bacteria. Most known synthetic compounds are potent gingipain inhibitors but have undesirable side effects because they also inhibit a wide range of host proteases. Natural inhibitors include cranberry and rice extracts, which inhibit gingipain activity and prevent the growth and biofilm formation of periodontal pathogens. Meanwhile a small molecule gingipain inhibitor, COR388, has been developed, which was safe and well-tolerated in 2 Phase 1 trials. COR388 is currently tested in a larger phase 2/3 clinical trial (the GingipAIN Inhibitor for Treatment of Alzheimer's Disease trial, GAIN, ClinicalTrials.gov ID: NCT03823404) to evaluate whether this oral drug is safe and can slow or halt the progression of AD by blocking the neurotoxic activity of gingipains. The GAIN trial follows a randomized controlled design and is looking to enroll more than 500 participants with mild to moderate AD at more than 90 clinical trial centers in the United States and Europe.

Final considerations

The results reviewed here clearly support the notion that inflammation plays an important role in PD and AD. Figure 3 shows some of the basic mechanisms and the sequence of events that may be involved in the neurodegeneration induced by PD. The hypothesis that PD and *Porphyromonas gingivalis* are causally related to AD and its progression is highly attractive. On the

other hand, gingipains were found also in healthy people and some people with AD did not have increased levels compared to these controls. People with AD reduce their oral hygiene and they tend to get leaky blood-brain barriers, which may increase their susceptibility to infections in their brains. Thus, it cannot be excluded that the brain infection is merely a by-product instead of a cause of the disease. The data from the mouse models may not be of much relevance for the situation in humans because *Porphyromonas gingivalis* is a pathogen that infects humans and has evolved alongside the human immune system. Nevertheless, animal models are essential to generate new hypotheses, which can be tested, preferentially in randomized clinical trials, to see whether a new intervention benefits people suffering from AD. Since it is highly unlikely that a single type of bacteria is the only cause of a disease as complex as AD, we need a better understanding of the potential role of the whole oral microbiota as a cause of the disease, *i.e.* microbiome studies of human brains *post mortem*. Also important are state-of-the-art brain magnetic resonance imaging studies to demonstrate a potential impact of the oral microbiota on preclinical surrogate markers of AD, such as global brain volume, atrophy of subcortical structures, like the hippocampus, cerebral white matter disintegration, and graph-theoretical measures of topology of large-scale structural brain networks.

Since PD is preventable and treatable, subjects with PD should be informed and treated in order to lower the microbial challenge and to prevent the systemic inflammatory burden, thereby promoting a higher quality of life. The recent development of an oral gingipain inhibitor, which is currently tested in a randomized controlled trial, for the first time offers the opportunity to verify the infectious hypothesis of AD. If successful, this research can be expected to result in a significant improvement of prevention and treatment of PD and PD-related AD.

Acknowledgments

Ghazal Aarabi, Götz Thomalla, Guido Heydecke and Thomas Beikler are employed at and receive salaries from the University Medical Center Hamburg-Eppendorf, Carolin Walter and Carola Mayer and Udo Seedorf are employed at the University Medical Center Hamburg-Eppendorf and their salary is funded by third party funds.

Conflicts of interest

GA, CW, CM, TB, GH, and US declare no potential conflicts of interest, GT declares that he has received consulting fees from Acandis and Stryker, grants from Bayer, and lecture fees from Bayer, Boehringer Ingelheim, Bristol-Meyers Squibb/Pfizer, Daiichi Sankyo, Portola, and Stryker.

References

1. Aarabi G, Thomalla G, Heydecke G, Seedorf U: Chronic oral infection: an emerging risk factor of cerebral small vessel disease? *Oral Dis* 2019; 25: 710–719
2. Abbayya K, Puthanakar NY, Naduwinmani S, Chidambar YS: Association between periodontitis and Alzheimer's disease. *N Am J Med Sci* 2015; 7: 241–246
3. Bercsenyi K, Schmiegi N, Bryson JB et al.: Tetanus toxin entry. Nidogens are therapeutic targets for the prevention of tetanus. *Science* 2014; 346: 1118–1123
4. Cheng SB, Ferland P, Webster P, Bearer EL: Herpes simplex virus dances with amyloid precursor protein while exiting the cell. *PLoS One* 2011; 6: e17966. doi.org/10.1371/journal.pone.0017966
5. Coureuil M, Lécuyer H, Bourdoulous S, Nassif X: A journey into the brain: Insight into how bacterial pathogens cross blood-brain barriers. *Nat Rev Microbiol* 2017; 15: 149–159
6. Dominy SS, Lynch C, Ermini F et al.: *Porphyromonas gingivalis* in Alzheimer's disease brains: Evidence for disease causation and treatment with small-molecule inhibitors. *Sci Adv* 2019; 5(1): eaau3333. doi:10.1126/sciadv.aau3333
7. Ferri CP, Prince M, Brayne C, Global prevalence of dementia: a Delphi consensus study. *Lancet* 2005; 366: 2112–2117

8. Garde E, Mortensen EL, Krabbe K, Rostrup E, Larsson HB: Relation between age-related decline in intelligence and cerebral white-matter hyperintensities in healthy octogenarians: A longitudinal study. *Lancet* 2000; 356: 628–634
9. Gatz M, Mortimer JA, Fratiglioni L et al.: Potentially modifiable risk factors for dementia in identical twins. *Alzheimers Dement* 2006; 2: 110–117
10. GDB 2016 Dementia Collaborators: Global, regional, and national burden of Alzheimer's disease and other dementias, 1990–2016: A systematic analysis for the global burden of disease study 2016. *Lancet Neurol* 2019; 18: 88–106
11. Giacona MB, Papapanou PN, Lamster IB et al.: Porphyromonas gingivalis induces its uptake by human macrophages and promotes foam cell formation in vitro. *FEMS Microbiol Lett* 2004; 241: 95–101
12. Gorelick PB: Risk factors for vascular dementia and Alzheimer disease. *Stroke* 2004; 35 (Suppl 1): 2620–2622
13. He Y, Zhu J, Huang F, Qin L, Fan W, He H: Age-dependent loss of cholinergic neurons in learning and memory-related brain regions and impaired learning in SAMP8 mice with trigeminal nerve damage. *Neural Regen Res* 2014; 9: 1985–1994
14. Hofman A, Ott A, Breteler MM et al.: Atherosclerosis, apolipoprotein E, and prevalence of dementia and Alzheimer's disease in the Rotterdam Study. *Lancet* 1997; 349: 151–154
15. Ide M, Harris M, Stevens A et al.: Periodontitis and cognitive decline in Alzheimer's disease. *PLoS One* 2016; 11: e0151081. doi.org/10.1371/journal.pone.0151081
16. Ishida N, Ishihara Y, Ishida K et al.: Periodontitis induced by bacterial infection exacerbates features of Alzheimer's disease in transgenic mice. *NPJ Aging Mech Dis* 2017; 3: 15-x. doi:10.1038/s41514-017-0015-x
17. Ishii K: PET approaches for diagnosis of dementia. *AJNR Am J Neuroradiol* 2014; 35: 2030–2038
18. Jaeger LB, Dohgu S, Sultana R et al.: Lipopolysaccharide alters the blood-brain barrier transport of amyloid beta protein: a mechanism for inflammation in the progression of Alzheimer's disease. *Brain Behav Immun* 2009; 23: 507–517
19. Kagan BL, Jang H, Capone R et al.: Antimicrobial properties of amyloid peptides. *Mol Pharm* 2012; 9: 708–717
20. Kamer AR, Pirraglia E, Tsui W et al.: Periodontal disease associates with higher brain amyloid load in normal elderly. *Neurobiol Aging* 2015; 36: 627–633
21. Kaye EK, Valencia A, Baba N, Spiro A, Dietrich T, Garcia RI: Tooth loss and periodontal disease predict poor cognitive function in older men. *J Am Geriatr Soc* 2010; 58: 713–718
22. Keller JJ, Sheu JJ, Lin HC: Chronic periodontitis and the subsequent risk of trigeminal neuralgia: A 5-year follow-up study. *J Clin Periodontol* 2012; 39: 1017–1023
23. Kinane DF, Berglundh T: Pathogenesis of periodontitis. In: Lindhe J, Lang NP, Karring T (Eds.): *Clinical Periodontology and Implant Dentistry*, 5th ed., Vol. 1, Blackwell Munksgaard, Oxford 2008, pp. 405–419
24. Kinney JW, Bemiller SM, Murtishaw AS, Leisgang AM, Salazar AM, Lamb BT: Inflammation as a central mechanism in Alzheimer's disease. *Alzheimers Dement (N Y)* 2018; 4: 575–590
25. Kumar DK, Choi SH, Washicosky KJ et al.: Amyloid- β peptide protects against microbial infection in mouse and worm models of Alzheimer's disease. *Sci Transl Med* 2016; 8: 340ra372. doi: 10.1126/scitranslmed.aaf1059
26. Lee JW, Lee YK, Yuk DY et al.: Neuroinflammation induced by lipopolysaccharide causes cognitive impairment through enhancement of beta-amyloid generation. *J Neuroinflammation* 2008; 5: 37. doi:10.1186/1742-2094-5-37
27. Lee YT, Lee HC, Hu CJ et al.: Periodontitis as a modifiable risk factor for dementia: a nationwide population-based cohort study. *J Am Geriatr Soc* 2017; 65: 301–305
28. Mawanda F, Wallace R: Can infections cause Alzheimer's disease? *Epidemiol Rev* 2013; 35: 161–180
29. Mitrabhakdi E, Shuangshoti S, Wan-nakrairot P et al.: Difference in neuropathogenetic mechanisms in human furious and paralytic rabies. *J Neurol Sci* 2005; 238: 3–10
30. Noble JM, Borrell LN, Papapanou PN, Elkind MS, Scarmeas N, Wright CB: Periodontitis is associated with cognitive impairment among older adults: analysis of NHANES-III. *J Neurol Neurosurg Psychiatry* 2009; 80: 1206–1211
31. Panza F, Lozupone M, Solfrizzi V, Watling M, Imbimbo BP: Time to test antibacterial therapy in Alzheimer's disease. *Brain* 2019; 142: 2905–2929
32. Poole S, Singhrao SK, Chukkappalli S et al.: Active invasion of Porphyromonas gingivalis and infection-induced complement activation in ApoE $^{-/-}$ mice brains. *J Alzheimers Dis* 2015; 43: 67–80
33. Poole S, Singhrao SK, Kesavalu L, Curtis MA, Crean S: Determining the presence of periodontopathic virulence factors in short-term postmortem Alzheimer's disease brain tissue. *J Alzheimers Dis* 2013; 36: 665–677
34. Riviere GR, Riviere KH, Smith KS: Molecular and immunological evidence of oral Treponema in the human brain and their association with Alzheimer's disease. *Oral Microbiol Immunol* 2002; 17: 113–118
35. Satpute-Krishnan P, DeGiorgis JA, Bearer EL: Fast anterograde transport of herpes simplex virus: Role for the amyloid precursor protein of Alzheimer's disease. *Aging Cell* 2003; 2: 305–318
36. Sheets SM, Potempa J, Travis J, Casiano CA, Fletcher HM: Gingipains from Porphyromonas gingivalis W83 induce cell adhesion molecule cleavage and apoptosis in endothelial cells. *Infect Immun* 2005; 73: 1543–1552
37. Sochocka M, Zwolińska K, Leszek J: The infectious etiology of Alzheimer's disease. *Curr Neuropharmacol* 2017; 15: 996–1009
38. Socransky SS, Smith C, Haffajee AD: Subgingival microbial profiles in refractory periodontal disease. *J Clin Periodontol* 2002; 29: 260–268
39. Soscia SJ, Kirby JE, Washicosky KJ et al.: The Alzheimer's disease-associated amyloid beta-protein is an antimicrobial peptide. *PLoS One* 2010; 5: e9505. doi.org/10.1371/journal.pone.0009505
40. Spitzer P, Condic M, Herrmann M et al.: Amyloidogenic amyloid- β -peptide variants induce microbial agglutination and exert antimicrobial activity. *Sci Rep* 2016; 6: 32228. doi:10.1038/srep32228
41. Stein PS, Desrosiers M, Donegan SJ, Yepes JF, Kryscio RJ: Tooth loss, dementia and neuropathology in the Nun study. *J Am Dent Assoc* 2007; 138: 1314–1322; quiz 1381–1312
42. Takeuchi H, Sasaki N, Yamaga S, Kuboniwa M, Matsusaki M, Amano A: Porphyromonas gingivalis induces penetration of lipopolysaccharide and peptidoglycan through the gingival epithelium via degradation of junctional adhesion molecule 1. *PLoS Pathog* 2019; 15: e1008124. doi:10.1371/journal.ppat.1008124
43. Teixeira FB, Saito MT, Matheus FC et al.: Periodontitis and Alzheimer's disease: a possible comorbidity between oral chronic inflammatory condition and neuroinflammation. *Front Aging Neurosci* 2017; 9: 327
44. Tonsekar PP, Jiang SS, Yue G: Periodontal disease, tooth loss and dementia: is there a link? A systematic review. *Gerodontology* 2017; 34: 151–163
45. Van Cauwenberghe C, Van Broeckhoven C, Sleegers K: The genetic landscape of Alzheimer disease: clinical implications and perspectives. *Genet Med* 2016; 18: 421–430

46. Walter C, Zahlten J, Schmeck B et al.: Porphyromonas gingivalis strain-dependent activation of human endothelial cells. *Infect Immun* 2004; 72: 5910–5918

47. Wiesner J, Vilcinskas A: Antimicrobial peptides: The ancient arm of the human immune system. *Virulence* 2010; 1: 440–464

48. Wu YT, Beiser AS, Breteler MMB et al.: The changing prevalence and incidence of dementia over time – current evidence. *Nat Rev Neurol* 2017; 13: 327–339

49. Wyss-Coray T, Rogers J: Inflammation in Alzheimer disease—a brief review of the basic science and clinical literature. *Cold Spring Harb Perspect Med* 2012; 2: a006346. doi:10.1101/cshperspect.a006346



(Photo: Löffler Foto, Schiffstr. 5–7, 79098 Freiburg)

**PD DR. MED. DENT.
GHAZAL AARABI, MSc.**
Department of Prosthetic Dentistry,
Center for Dental and Oral Medicine,
University Medical Center
Hamburg-Eppendorf
Martinistr. 52, 20251 Hamburg
g.aarabi@uke.de



(Photo: private, Udo Seedorf)

**PROF. DR.
UDO SEEDORF**
Department of Prosthetic Dentistry,
Center for Dental and Oral Medicine,
University Medical Center
Hamburg-Eppendorf
Martinistr. 52, 20251 Hamburg
u.seedorf@uke.de