5 | 2020
2. VOLUME

DZZ INTERNATIONAL

German Dental Journal International – **www.online-dzz.com**
International Journal of the German Society of Dentistry and Oral Medicine

This journal is regularly listed in CCMED / LIVIVO.

Deutscher Ärzteverlag

PRACTICE

RESEARCH

Title picture: From the case report of Karin Groß and Stefan Wolfart, here Figure 1: Fixation of the lateral incisors – dimensioned and shaped according to the wax-up – for attaining a harmonious dental arch in the congenital absence of 12 and 22, p. 160–167; (Fig. 1: K. Groß)
Online-Version of DZZ International: www.online-dzz.com

Are mini-implants an alternative to standard-diameter implants?

What must I be aware of when using mini-implants?

Dental implants are an indispensable part of the dental treatment spectrum and represent an integral component of contemporary prosthodontic treatment concepts. The use of implants for both removable and fixed prosthodontics offers clinically relevant advantages, which have been recorded for patients in the form of an improvement in the oral health-related quality of life and masticatory function, as well as, better long-term restorative treatment prognosis [9].

Implant-prosthetic concepts

The prognosis for fixed restorations on implants is very good (5-year prognosis 96.4 %, 10-year prognosis 93.9 %) and corresponds to the prognosis for short-span restorations on teeth [29]. Thus, through the use of implants, the grinding of the natural teeth and long-span bridges can be avoided, while free-end edentulous spaces can also be treated. Moreover, it is possible to restore the edentulous jaw with a complete denture using 4–8 implants [25, 26].

In the case of removable dentures, the use of implants in the edentulous jaw (1–6 implants in the mandible and 4–8 implants in the maxilla) can significantly improve the masticatory function and satisfaction with dental restorations. Patients prefer good fixation and low rotation of dentures [9]: special consideration is needed to provide an utmost quadrangular support, while the axes of rotation and selection of the attachment system concept must be thoroughly thought out. In order to achieve the best possible retention and support for a denture in a partially edentulous dentition, so-called strategic implants, which are placed in strategically important positions, can be used. In cases of complete edentulism, one or two implants may be used to reduce the the denture's rotation. A rigidly supported, removable denture, or more specifically, a denture that wobbles less, not only leads to better patient satisfaction, but also to less wear and tear of the attachment systems, and thus to a better long-term prognosis. The prognosis of strategic implants is very good and comparable to that of single-tooth implants [22].

The use of implants is thus recommended in many cases requiring prosthetic rehabilitation. This has been documented for almost 20 years in the McGill Consensus Statement, which describes the rehabilitation of an edentulous patient with a complete denture as being an inadequate restoration and therefore demands the use of at least 2 implants in the mandible [16]. According to current data, the minimum number of implants in the edentulous mandible can be defined as a single implant placed near the mandibular symphysis [23].

Narrow-Diameter-Implants (NDIs)

The described implant-prosthetic concepts for standard diameter implants (> 3.5 mm) have been investigated and are evidence-based. The results, however, cannot be generalized 1:1 with regard to reduced diameter implants.

Reduced diameter implants are also called Narrow-Diameter-Implants (NDIs). They have diameters that range between 1.8–3.5 mm and can be divided into 3 categories based on their diameter [20]:

Category 1 is comprised of mini-implants (MDI, 1.8–2.5 mm) which are basically one-piece. Category 2 (diameter 2.5–3.25 mm) and category 3 (diameter 3.3–3.5 mm) consist of two-piece implants.

Category 3 NDIs that are made of pure titanium (titanium grade IV) have only one fifth of the mechanical load capacity (200 N vs. 1000 N) in comparison to standard-diameter implants (4.1 mm) [5]. This reduction of implant diameter consequently leads to an increased risk of fracture, at least in theory. Therefore, the susceptibility to fracture of the two-piece category 2 and 3 implants can be reduced by making modifications to the implant-abutment connection, which allows for thicker implant wall thickness, or by employing titanium-zirconium alloys with a higher fracture resistance. Category 1 implants cannot be made of pure titanium due to the high fracture potential; instead, they are produced from a titanium alloy (Titanium Grade V, Ti6Al-4V ELI) and are a single piece, as a two-piece design would reduce the wall thickness.

Translation from German: Cristian Miron
Citation: Enkling N: Are mini-implants an alternative to standard-diameter implants? Dtsch Zahnärztl Z Int 2020; 2: 155–159
DOI.org/10.3238/dzz-int.2020.0155–0159

It is also known from materials science and finite element studies that a change in implant geometry leads to a changed force distribution into the peri-implant cortical bone [19]. In this regard, a change in implant diameter has a greater effect than a change in implant length [8]: an increase in diameter from 2.5 mm to 3.3 mm reduces the stress on the cortical bone by 30.7 %, whereas an increase in implant length from 8.5 mm to 15 mm reduces it by only 1.7 %.

This raises the question of the survival prognosis of reduced diameter implants, especially in cases of compromised bone supply. It should be noted that in spite of the fact that very good implant survival and success rates have been documented for standard-diameter implants [24], these were not achieved in cases of poor bone quality and quantity [7, 15].

The scientific data published to date on NDIs shows very good results with regard to implant survival and success which is comparable to that of standard implants (90–100 %) [6, 35, 36]. Nonetheless, a recent review indicates that there are significant differences between the 3 categories of NDIs in terms of failure rates: category 2 and 3 show very good prognoses, which are comparable to standard-diameter implants. In contrast, category 1 implants which are mini-implants with a diameter of 2.5 mm or less, show a significantly higher risk of implant loss with an odds ratio of 4.54 (CI: 1.51–13.65) [33]. Therefore, if possible, a category 2 and 3 NDI or a category 1 implant which is thicker should preferably be chosen.

Modern category 3 NDIs show very good results and, with regard to the prosthetic concepts described above, can probably be employed similarly to standard implants in many cases. The use of category 2 and 3 NDIs is unproblematic for the indication of lower incisor and upper lateral incisor single-tooth implants, but their use in the molar region, where high masticatory loads exist, is not recommended [19, 33]. If these principles are followed, a very good implant survival rate (90–100 %) has been documented for fixed restorations on reduced diameter implants [36].

Mini-implants

The extremely resorbed alveolar bone can be so thin, however, that only category 1 implants are possible without bone augmentation. There are thus clinically relevant indications for this implant group: in a recent review of category 1 implants, very good survival rates (98 %) and success rates (93 %) were reported for the indication stabilization of a complete mandibular denture [27]. For the same indication, in a recently published prospective 5-year study performed at the University of Bern, a survival and success rate of 100 % for immediately loaded 1.8 mm diameter implants [12, 13] was documented. However, the use of category 1 NDIs for the indication of fixed restorations does not seem advisable. Although mini-implants can function well as described above, they should not be taken lightly. The success of therapy with mini-implants depends on patient selection and the experience of the dental practitioner [31]. In a study conducted in 5 centers and on 1029 examined implants, it was shown that the average implant survival rate was 91 %. When the data was assessed for each particular center, however, the situation was as follows: Four centers achieved success rates of over 90 % while the fifth achieved a success rate of only 69 %, as 13 from 42 implants were lost [10]. An intensive analysis of the surgical procedure therefore seems advisable: the surgical procedure is in principle very straightforward, but the drilling

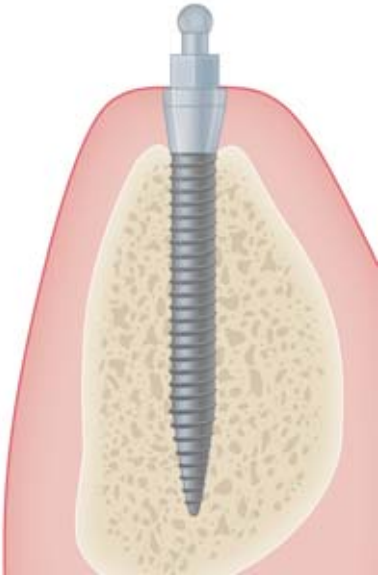

(Fig. 1 and 2: Ines Badertscher, University Bern)

Figure 1 The mini-implant (1.8 mm diameter)

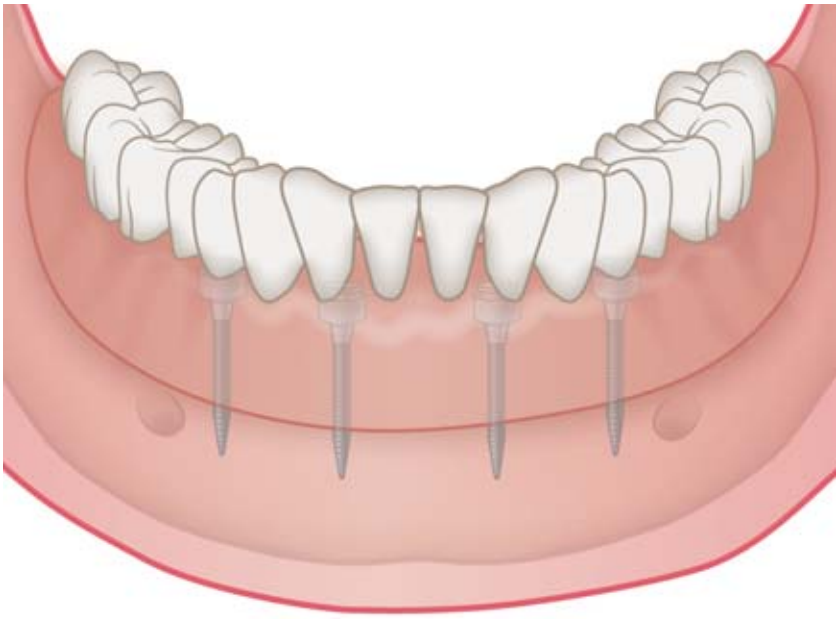

Figure 2 Four interforaminal mini-implants with corresponding overdenture

protocol must be adapted to each individual patient [35]. Conventional drilling is not performed, but rather a perforation of the cortical bone, as the implant always has a self-drilling and self-cutting feature. For 1.8 mm diameter implants, a torque of 45 Ncm should by no means be exceeded because the risk of fracture increases considerably: based on the scientific data published to date, it is evident that thin implants are somewhat susceptible to fracture during insertion. In a prospective study performed at the University of Belgrade, implant surgery was accompanied by a 2.5 % implant fracture rate (3 of 120) [32], and in a retrospective evaluation from the USA, a 0.8 % fracture rate was documented during implant insertion [35]. An increased implant fracture rate after loading with the removable denture could not be demonstrated thus far: the implant fracture rate of 1 % in the mandible, which was determined in a recent multicenter study from Germany (4 of 402 MDI implants) [28] corresponds to the reported data on standard-diameter implants [18]. This positive data on the clinical fracture stability of MDIs in removable prosthetics is probably due to the way the denture is connected to the implant: MDIs are one-piece implants with 1.8 mm ball attachments that are connected to the denture by means of polymerized matrices (metal housings with an inserted rubber O-ring). The only contact which is permitted, however, is between the ball and the rubber O-ring; no contact between the metal matrix housing and the ball-shaped patrix is allowed. This design feature means that the denture is only retained and not supported on the mini-implants. As with conventional complete dentures, mucosal support on the alveolar process mucosa occurs. In this manner, the matrices serve to increase retention and reduce denture rotation. Wear is also limited to the rubber O-ring of the matrix in every matrix and patrix system in the oral cavity [1]. This is an advantageous feature because the wear of the patrix cannot be compensated, as it is fixed to the implant body and cannot be replaced. On the other hand, the rubber ring is easily replaceable. The rubber O-rings display a retention force of 5–9 N; this is comparable to blue and pink locator inserts (Zest-Anchors, Escondido, USA) [2]. Normally, 20 % of the rubber O-rings must be replaced after one year [28]. The precision of the O-rings is very good which means that the original retention force after replacement can be restored predictably [2].

The use of mini-implants has been shown to considerably improve the masticatory function and biting power in both older and younger patients [14], although elderly patients needed more time to attain the improvements in masticatory function [12]. In spite of these benefits, the retention of the implant overdentures using the O-rings of the MDI matrices is less rigid than the anchorage provided by a milled parallel-walled bar. This represents a certain loss of comfort which must be taken into account during individual therapy planning. Nevertheless, in a prospective 5-year study, it was shown that the oral health-related quality of life improved significantly through the use of 4 interforaminal implants [30]. The mobility can also bring about a clinically relevant benefit: the spherical ball-shaped patrices of the mini-implants display hardly any tartar build-up and the peri-implant mucosa is usually healthy, which can be attributable to the self-cleaning effect of the rubber O-rings [37]. It should be emphasized that the absence of peri-implant keratinized mucosa did not lead to increased bone resorption rates [13]. For prophylactic reasons, however, a peri-implant keratinized mucosa is still recommended for easier implant hygiene.

In the edentulous mandible, mini-implants have been proven to be a safe therapy option for better retention of removable dentures. [10, 13, 35]. In addition to their indication in edentulous patients, partially edentulous patients can also benefit from the use of mini-implants.

Corresponding concepts for mini-supportive implants have been published: 1–4 implants could be used in the lower jaw and 1–6 implants in the upper jaw depending on the number and distribution of the remaining teeth [3]. However, the characteristics of the above described ball attachments must be taken into account for the mini-strategic implants: The attachments on the teeth are always more rigid than those on the 1.8 mm balls. The effect of the mini-strategic implants is that the denture is better retained, but not better supported. This implies that the restoration in the area of the mini-strategic implants is still supported by the mucosa and the natural attachment teeth can then act as a fulcrum. Thus, the denture exhibits a certain degree of mobility and this should be taken into account during planning and patient education.

Clinical tips for mini-implant use

The simple surgical and prosthetic procedure, which requires minimal material and time, coupled with less follow-up care, is highly valued by dental practitioners [34]. For prosthetic planning, it is important to note that mini-implants should be well distributed and respect a minimum distance of 4 mm from each other. If the distance is less than 4 mm, difficulties arise in positioning the matrices side by side due to the matrix housing size. In patients with strong masticatory forces and thin mandibular dentures, where the plastic coating of the matrix is less than 2 mm thick, there is an increased denture fracture risk in the area of the matrix housing [11]. In a study by Mundt et al., a fracture rate of 20 % was determined for MDI-implant-overdentures which had no model cast reinforcement [28]. The incorporation of a lingual 1 mm thick reinforcement band made of cast alloy is recommended in such cases [13]. In a recent prospective study with 5-year results, a 35 % fracture rate was determined for mandibular dentures without model cast reinforcement. After the model cast reinforcement was adopted, no further fractures occurred [13]. A lingual reinforcement, or more specifically, a lingual thickening of a mandibular prosthesis by about 2–4 mm is well tolerated by many patients and is not perceived as disturbing [4].

The recommendation of a model cast prosthesis after a fracture has oc-

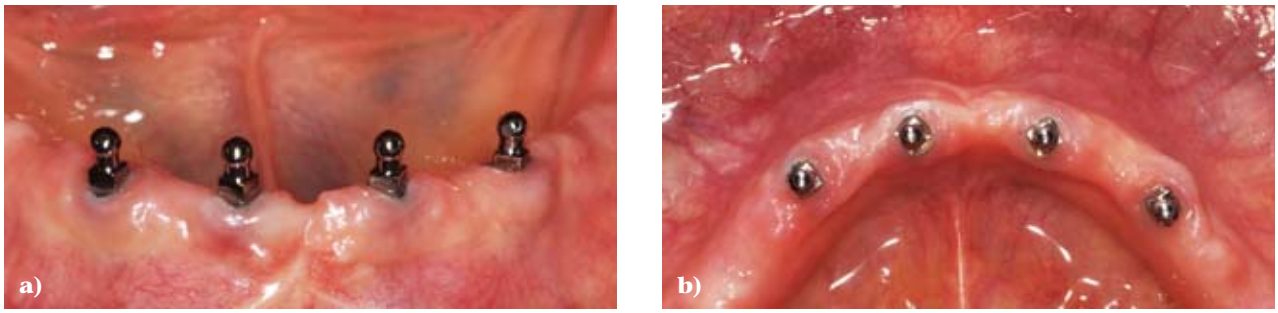

(Fig. 3a and 3b: N. Enkling, University Bern)

Figure 3a and. 3b Example case from the mini-implant study performed at the University of Bern, 5 years after implant placement: 4 immediately loaded interforaminal implants 1.8 mm x 1.3 mm/overdenture; **a)** frontal view; **b)** top view

curred can lead to disagreements with the patient: therefore, it is advisable to offer a model cast reinforcement as a matter of principle, which can even be integrated at a later point in mandibular dentures. In the maxilla, a model cast reinforcement should be planned from the outset, as the thickness of the denture is consistently reduced.

According to the clinical protocol for mini-implant systems, 4 implants in the mandible and 6 implants in the maxilla are needed for implant overdenture retention. If a minimum insertion torque of 35 Ncm is achieved, mandibular MDIs may be loaded immediately. In the case of lower primary stability values, immediate loading in the mandible is not advisable and a soft relining is recommended instead; just after a 3-month healing period, the matrix housings can be polymerized and the delayed loading of the implants performed. In the maxilla, a 6-month healing period is generally recommended before loading. However, data from the University of Montreal in Canada show that in the mandible, a torque of 15 Ncm would be sufficient for immediate loading [21].

Despite the good implant survival outcomes in the mandible, the same results should not readily be assumed for the maxilla, as the rates of implant loss are higher in the edentulous maxilla. Shatkin et al. report a survival rate of 95.1 % for mandibular and 83.2 % for maxillary overdentures [35]. The working group for implantology and biomaterials research at the University of Bonn reported similar results with respect to the differences between the upper and lower jaws, although these are momentarily still being scientifically evaluated. With regard to the increased rates of implant loss in the maxilla, there appears to be a cluster effect, meaning that more implants are lost in single patients. Increased caution is therefore required in the edentulous maxilla. This assessment is consistent with the recommendations of the International Team for Implantology (ITI) and its SAC system: the edentulous mandible is classified surgically as being straightforward and the edentulous maxilla as being complex.

Conclusion

The simplicity of treatment and low material costs result in the fact that social indications can also be treated with mini-implants. Using MDIs, it is possible to come close to the goal, as formulated in various scientific statements, of restoring the edentulous mandible in patients using implant-supported overdentures [16]. Treatment with 4–6 mini-implants also opens up new possibilities for a minimally invasive approach. Future scientific studies are necessary in order to explore the limits for mini-implant indication. Mini-implants already represent an established and well documented treatment option for treating the edentulous mandible. On the other hand, they are not suitable for the indication of fixed restorations in masticatory load bearing areas. Their mechanical inferiority compared to standard-diameter implants has been proven and it must be taken into account when determining their indication [5, 17, 19].

Conflicts of interest

In the past, Prof. Dr. Norbert Enkling has given paid lectures at scientific conferences and lectures with workshops for implant companies such as Nobel Biocare, SIC Invent, Dentaurum Implants, 3M Espe and Condent.

References

1. Abou-Ayash S, Enkling N, Srinivasan M, Haueter M, Worni A, Schimmel M: Evolution of in vivo assessed retention forces in one-piece mini dental implant-retained mandibular overdentures: 5-year follow-up of a prospective clinical trial. Clin Implant Dent Relat Res 2019; 21: 968–976

2. Abou-Ayash S, Schimmel M, Worni A, Enkling N: O-ring attachments on one-piece mini dental implants: in-vitro analysis of retention force reproducibility using different pristine matrix-O-ring combinations. The International Journal of Prosthodontics. 2020;

3. Al Jaghsi A, Heinemann F, Biffar R, Mundt T: Immediate versus delayed loading of strategic mini-implants under existing removable partial dentures: patient satisfaction in a multi-center randomized clinical trial. Clin Oral Investig 2020; Jun 12. doi: 10.1007/s00784–020–03360-y

4. Albrecht D, Ramierez A, Kremer U, Katsoulis J, Mericske-Stern R, Enkling N: Space requirement of a prefabricated bar on two interforaminal implants: a prospective clinical study. Clin Oral Implants Res 2015; 26: 143–148

5. Allum SR, Tomlinson RA, Joshi R: The impact of loads on standard diameter, small diameter and mini implants: a comparative laboratory study. Clin Oral Implants Res 2008; 19: 553–559

6. Alrabiah M: Comparison of survival rate and crestal bone loss of narrow diameter dental implants versus regular dental implants: a systematic review and

meta-analysis. J Investig Clin Dent 2019; 10: e12367

7. Alsaadi G, Quirynen M, Michiles K, Teughels W, Komarek A, van Steenberghe D: Impact of local and systemic factors on the incidence of failures up to abutment connection with modified surface oral implants. J Clin Periodontol 2008; 35: 51–57

8. Anitua E, Tapia R, Luzuriaga F, Orive G: Influence of implant length, diameter, and geometry on stress distribution: a finite element analysis. Int J Periodontics Restorative Dent 2010; 30: 89–95

9. Bassetti RG, Mericske-Stern R, Enkling N: Are there differences in the changes in oral-health-related quality of life (OHRQoL) depending on the type (rigidity) of prosthetic treatment? Quintessence Int 2016; 47: 749–757

10. Bulard RA, Vance JB: Multi-clinic evaluation using mini-dental implants for long-term denture stabilization: a preliminary biometric evaluation. Compend Contin Educ Dent 2005; 26: 892–897

11. Choi M, Acharya V, Berg RW et al.: Resinous denture base fracture resistance: effects of thickness and teeth. Int J Prosthodont 2012; 25: 53–59

12. Enkling N, Haueter M, Worni A, Müller F, Leles CR, Schimmel M: A prospective cohort study on survival and success of one-piece mini-implants with associated changes in oral function: Five-year outcomes. Clin Oral Implants Res 2019; 30: 570–577

13. Enkling N, Moazzin R, Geers G, Kokoschka S, Abou-Ayash S, Schimmel M: Clinical outcomes and bone-level alterations around one-piece mini dental implants retaining mandibular overdentures: 5-year follow-up of a prospective cohort study. Clin Oral Implants Res 2020; 31: 549–556

14. Enkling N, Saftig M, Worni A, Mericske-Stern R, Schimmel M: Chewing efficiency, bite force and oral health-related quality of life with narrow diameter implants – a prospective clinical study: results after one year. Clin Oral Implants Res 2017; 28: 476–482

15. Esposito M, Hirsch JM, Lekholm U, Thomsen P: Biological factors contributing to failures of osseointegrated oral implants. (II). Etiopathogenesis. Eur J Oral Sci 1998; 106: 721–764

16. Feine JS, Carlsson GE, Awad MA et al.: The McGill consensus statement on overdentures. Mandibular two-implant overdentures as first choice standard of care for edentulous patients. Montreal, Quebec, May 24–25, 2002. Int J Oral Maxillofac Implants 2002; 17: 601–602

17. Flanagan D, Ilies H, McCullough P, McQuoid S: Measurement of the fatigue life of mini dental implants: a pilot study. J Oral Implantol 2008; 34: 7–11

18. Goodacre CJ, Bernal G, Rungcharassaeng K, Kan JY: Clinical complications with implants and implant prostheses. J Prosthet Dent 2003; 90: 121–132

19. Hasan I, Heinemann F, Aitlahrach M, Bourauel C: Biomechanical finite element analysis of small diameter and short dental implant. Biomed Tech (Berl) 2010; 55: 341–350

20. Jung RE, Al-Nawas B, Araujo M et al.: Group 1 ITI Consensus Report: The influence of implant length and design and medications on clinical and patient-reported outcomes. Clin Oral Implants Res 2018; 29 (Suppl 16): 69–77

21. Kanazawa M, Feine J, Esfandiari S: Clinical guidelines and procedures for provision of mandibular overdentures on 4 mini-dental implants. J Prosthet Dent 2017; 117: 22–27

22. Kaufmann R, Friedli M, Hug S, Mericske-Stern R: Removable dentures with implant support in strategic positions followed for up to 8 years. Int J Prosthodont 2009; 22: 233–241; discussion 242

23. Kern M, Att W, Fritzer E et al.: Survival and complications of single dental implants in the edentulous mandible following immediate or delayed loading: a randomized controlled clinical trial. J Dent Res 2018; 97: 163–170

24. Laurell L, Lundgren D: Marginal bone level changes at dental implants after 5 years in function: a meta-analysis. Clin Implant Dent Relat Res 2011; 13: 19–28

25. Maló P, de Araújo Nobre M, Lopes A, Ferro A, Botto J: The all-on-4 treatment concept for the rehabilitation of the completely edentulous mandible: a longitudinal study with 10 to 18 years of follow-up. Clin Implant Dent Relat Res 2019; 21: 565–577

26. Maló P, de Araújo Nobre M, Lopes A, Ferro A, Nunes M: The all-on-4 concept for full-arch rehabilitation of the edentulous maxillae: a longitudinal study with 5–13 years of follow-up. Clin Implant Dent Relat Res 2019; 21: 538–549

27. Marcello-Machado RM, Faot F, Schuster AJ, Nascimento GG, Del Bel Cury AA: Mini-implants and narrow diameter implants as mandibular overdenture retainers: a systematic review and meta-analysis of clinical and radiographic outcomes. J Oral Rehabil 2018; 45: 161–183

28. Mundt T, Schwahn C, Stark T, Biffar R: Clinical response of edentulous people treated with mini dental implants in nine dental practices. Gerodontology 2015; 32: 79–187

29. Pjetursson BE, Brägger U, Lang NP, Zwahlen M: Comparison of survival and complication rates of tooth-supported fixed dental prostheses (FDPs) and implant-supported FDPs and single crowns (SCs). Clin Oral Implants Res 2007; 18 (Suppl 3): 97–113

30. Reissmann DR, Enkling N, Moazzin R, Haueter M, Worni A, Schimmel M: Long-term changes in oral health-related quality of life over a period of 5 years in patients treated with narrow diameter implants: A prospective clinical study. J Dent 2018; 75: 84–90

31. Renouard F, Nisand D: Impact of implant length and diameter on survival rates. Clin Oral Implants Res 2006; 17 (Suppl 2): 35–51

32. Scepanovic M, Calvo-Guirado JL, Markovic A et al.: A 1-year prospective cohort study on mandibular overdentures retained by mini dental implants. Eur J Oral Implantol 2012; 5: 367–379

33. Schiegnitz E, Al-Nawas B: Narrow-diameter implants: A systematic review and meta-analysis. Clin Oral Implants Res 2018; 29 (Suppl 16): 21–40

34. Shatkin TE, Petrotto CA: Mini dental implants: a retrospective analysis of 5640 implants placed over a 12-year period. Compend Contin Educ Dent 2012; 33 (Spec 3): 2–9

35. Shatkin TE, Shatkin S, Oppenheimer BD, Oppenheimer AJ: Mini dental implants for long-term fixed and removable prosthetics: a retrospective analysis of 2514 implants placed over a five-year period. Compend Contin Educ Dent 2007; 28: 92–99; quiz 100–101

36. Sohrabi K, Mushantat A, Esfandiari S, Feine J: How successful are small-diameter implants? A literature review. Clin Oral Implants Res 2012; 23: 515–525

37. Worni A, Hicklin SP, Mericske-Stern R, Enkling N: Performance and marginal bone level alteration around immediately loaded narrow-diameter implants. A prospective clinical study: Results after 1 year. Quintessence Int 2018; 49: 267–276

(Photo: Norbert Enkling)

PROF. DR. NORBERT ENKLING, MAS
Head of Working Group Oral Implantology and Biomaterial Research
Department of Prosthodontics, Preclinical Education and Dental Materials Science,
Medical Faculty, University of Bonn
&
Department of Reconstructive Dentistry and Gerodontology,
University of Bern, Switzerland

c/o Eichenklinik- Praxisklinik für Zahnmedizin, Eichener Strasse 69,
57223 Kreuztal
enkling@uni-bonn.de

Karin Groß, Stefan Wolfart

Interfaces between orthodontics and prosthodontics: interdisciplinary possibilities and "innovations"

Introduction: This article presents possibilities regarding how orthodontists and prosthodontists can cooperate together to create conditions for an esthetically pleasing and functionally oriented treatment result. When planning the prosthetic treatment of anterior gaps, the gaps can be adjusted in advance by means of orthodontic treatment so that they can subsequently be treated in the best possible esthetic and functional manner.

Material and Methods: Adhesive bridges represent a suitable treatment option in adolescents for congenitally missing lateral incisors or after anterior tooth loss due to trauma. When designed with one wing, adhesive bridges can be used before the completion of jaw bone development and, if necessary, they can be orthodontically positioned together with the abutment tooth. Prior to complex prosthetic rehabilitation in the esthetic area, malpositioned abutment teeth can be orthodontically positioned or aligned to generate space for an ideal restoration design. Moreover, orthodontic extrusion provides the possibility of achieving sufficient abutment heights in the case of deeply destroyed or fractured teeth, thus permitting the adequate treatment of these critical teeth according to prosthetic guidelines. Oftentimes, in the case of tilted, protruded or retruded teeth, an orthodontic intervention previous to tooth preparation is useful for tooth substance conservation and maintaining the vitality of abutment teeth.

Conclusion: It can be concluded that a specific combination of orthodontic and prosthetic treatment measures can achieve a better restorative treatment result in terms of function, esthetics and long-term stability. Often, this is accompanied by a reduction in treatment duration and costs.

Keywords: interdisciplinary treatments; gap management; extrusion; esthetics; adhesive bridges

Clinic for Prosthodontics, Center for Implantology, Medical Center of RWTH Aachen University: Dr. Karin Groß; Prof. Dr. Stefan Wolfart
Translation from German: Christian Miron
Citation: Groß K, Wolfart S: Interfaces between orthodontics and prosthodontics: interdisciplinary possibilities and "innovations". Dtsch Zahnärztl Z Int 2020; 2: 160–167
Peer-reviewed article: submitted: 13.03.2020, revised version accepted: 07.06.2020
DOI.org/10.3238/dzz-int.2020.0160–0167

Introduction

In order to achieve esthetically pleasing and functionally optimized treatment results in complex treatment cases, close cooperation between the orthodontist and prosthodontist is often advisable. In ideal circumstances, this teamwork extends from treatment planning to joint treatment implementation and is rewarded by satisfied patients and high-quality treatment results. The overlap, or interface, between the two disciplines is multifaceted. This article discusses 4 of these interfaces and presents clinical examples to illustrate them:

1. If individual teeth are missing, the question of which specialty domain should have pre-eminence, and accordingly the responsibility, often arises: Should an existing dental gap be orthodontically closed, or be restored by prosthetic means, such as a bridge, adhesive bridge or implant? Each of these approaches has advantages and disadvantages; they can best be discussed in a joint consultation between the dentist, orthodontist and patient.
2. In the case that a dental gap is to be treated by prosthetic means, it is necessary to first check the gap size and decide whether or not it is acceptable, as corrective orthodontic treatment may be required beforehand for an esthetically pleasing or functionally reasonable solution. The same applies for the restoration of multiple teeth in the esthetic zone. Often, this is only useful if the abutments are spaced at a distance that allows esthetically pleasing length-width ratios to be anticipated for each individual restoration and between adjacent anterior teeth.
3. For the crowning of teeth, it is necessary to have adequate abutment height and sufficient healthy tooth structure after tooth preparation. If this is not the case due to biological width considerations and a high degree of destruction, an orthodontic extrusion can be considered.
4. Following a crowning procedure, approximately 15 % of teeth show a negative response to sensitivity testing after 10 years [12]. A remaining dentin thickness of 0.5 mm should be aimed for in order to reduce the risk of pulp damage [15]. Therefore, it is important to remove as little healthy tooth structure as possible during preparation. Currently, preparation designs which preserve tooth substance have gained in importance. In this respect, the position and axial inclination of teeth play a decisive role. In clinical situations where the prospective abutment teeth require a common insertion path, but differ greatly in their axial inclinations, a conservative tooth preparation design is not attainable. In these cases, in order to avoid exceedingly invasive tooth preparations, orthodontically active components can be used in combination with interim dentures. By combining the temporary prosthetic phase with

Figure 1 Fixation of the lateral incisors – dimensioned and shaped according to the wax-up – for attaining a harmonious dental arch in the congenital absence of 12 and 22

Figure 2 Situation after removal of the brackets; width of the gaps optimally shaped

Figure 3 Placement of adhesive bridges to replace teeth 12 and 22

Figure 4 Two mesially interconnected adhesive bridges simultaneously adopt the function of a retainer.

Figures 5–7 Initial situation with multiple diastemas between the maxillary front teeth in the presence of a strongly abraded dentition; occlusal, frontal views and the patient's smile

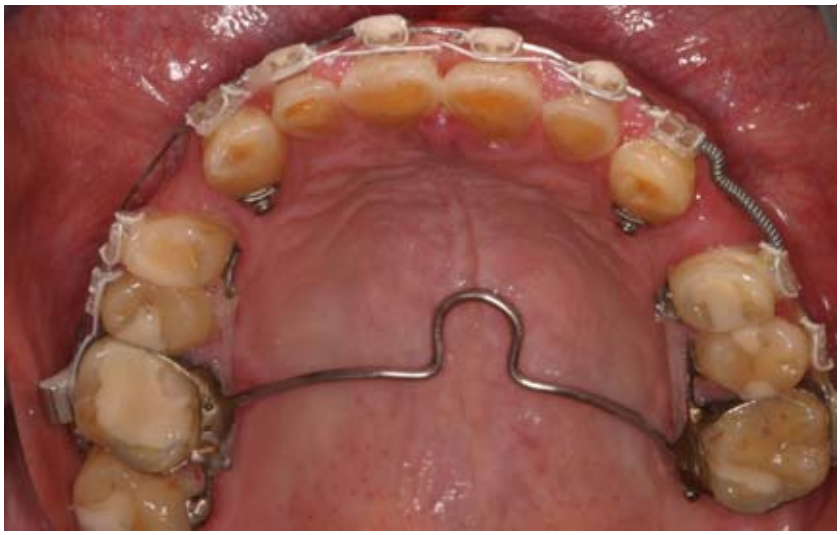

Figure 8 Gap closure mesially and gap opening in the area of the first premolars (orthodontic treatment performed by Prof. Dr. Fischer-Brandis, Kiel)

orthodontic dental alignment, a lower amount of tooth substance removal can be facilitated.

First interface: missing teeth

Anterior region gaps are most frequently caused by the congenital absence of teeth, especially maxillary lateral incisors, or traumatic loss. Around one quarter of young people experience front tooth trauma by the age of 14 and about 7 % of these front teeth are lost [23]. Circa 1.5–1.8 % of people in Germany are affected by upper lateral incisor agenesis [17]. Hence, it can be assumed that approximately 3–3.5 % of young people aged 14 years old are missing anterior teeth [7]. A number of treatment options can then be chosen. If the lateral incisors are congenitally missing, patients, or rather their parents, are often presented with the options of either an orthodontic gap closure or an implant-supported restoration. Orthodontists often favor gap closure by means of canine mesialization. Gap closure not only has functional implications, but also esthetic ones. This is because canines differ noticeably from lateral incisors, in both shape and color, as canines usually appear darker than incisors. Consequently, in the majority of cases, the treatment is not fully complete after orthodontic gap closure due to esthetic reasons; for a natural appearance, canines then require corrective treatment to imitate the appearance of lateral incisors. This implicates adapting the tooth's shape and color by means of applying a veneer, preparation of the enamel or whitening of the enamel by bleaching [18, 20, 26]. Particularly in the case of unilateral agenesis, asymmetrical tooth positions may lead to esthetic impairments. For this reason, the symmetrical alignment of the front teeth should always be an important objective.

Implant-supported restorations are contraindicated in adolescence. Nevertheless, even after transversal bone growth and canine eruption have been completed, vertical bone growth may continue into adulthood

Figure 9–11 Prosthetic restoration with metal-ceramic crowns and bridges in the upper jaw; occlusal, frontal views and the patient's smile

Figure 12 Fractured tooth 21 with adapted, fixed magnet

Figure 13 Miniplast splint with integrated magnet (B); magnet A fixed to the abutment

Figure 14 Abutment after successful extrusion; the incisal third of the abutment was built up with composite

Figure 15 Definitive zirconia crown half a year after cementation

Figure 16 Forced extrusion of abutment 26

Figure 17 Forced extrusion of the root of tooth 11; a metal-reinforced cantilever bridge on implant 12 serves as an extrusion aid.

[21, 22]. Implants which are placed too early are often located in an infra position after a few years, which not only results in step formation at the incisal edges, but also in poor red-white esthetics in the area of the gingival line. Especially in the case of a high smile line, the timing for implant placement should be carefully considered. Adhesive bridges are often overlooked, or are solely considered a more or less temporary solution, until the age is reached when implants can be inserted. Lately, however, very good long-term results have been reported when using adhesive bridges. One-wing adhesive bridges have proven to be more reliable than two-wing bridges [2, 4, 10, 19, 24]. The clinical survival rate of one-wing adhesive bridges made of aluminum or zirconium oxide ceramics is between 95.4 and 98 % after 10 years [6, 9]. Thus, the survival rates of implant-supported crowns and one-wing adhesive bridges can therefore be regarded as being equivalent [11].

With reference to legally consistent patient education, the law governing the improvement of patients' rights, anchored in the Federal Law Gazette 2013, specifies that the patient should be completely informed regarding all possible treatment options [1]. Accordingly, adhesive bridges must definitely be discussed as a treatment option. This necessity is also underlined by the fact that adhesive bridges are listed as a standard care procedure in the service catalogue of statutory health insurance companies since 2016. The key advantages of one-wing adhesive bridges are the minimally invasive preparation design which is only confined to the enamel and the fact that the restoration can be applied regardless of the stage of jaw bone development. The requirement is the presence of a completely erupted, caries-free neighboring tooth which borders the gap, having an adhesive surface in the enamel of at least 30 mm^2, as well as, sufficient space relative to the antagonist jaw for the purpose of being able to design a connector with a height of at least 3 mm [8]. Additionally, sufficient space should be generated for wing insertion in the case of maxillary adhesive bridges. For this purpose, the corresponding abutment tooth is protruded by approximately 0.7 mm using an aligner or multiband therapy. This creates sufficient space to attach the wing of the bridge without the need to perform any occlusal adjustments by grinding of antagonist teeth in the antagonist jaw. These necessary space conditions should be taken into consideration early on when planning an orthodontic treatment.

If only one incisor is missing, the contralateral tooth in the same jaw determines the size and shape of the intended restoration. A timely consultation with the prosthodontist is helpful here. Thus, a wax-up/set-up can be prepared at an early stage in order to model a suitable tooth. A try in of the tooth wax-up can be made, which is thereafter converted into composite. The model tooth is fixed in the dental arch in order to give the orthodontist the chance to adjust the dental gap exactly to the desired size and position for the subsequent esthetic restoration. A similar procedure is useful if both lateral incisors are missing (Fig. 1). In this case, too, an ideal situation can be created through precise prosthetic planning

Figure 18 Extrusion of approximately 4 mm after 4 weeks

Figure 19 Initial situation, distally inclined canines

before, or at the latest, during orthodontic treatment (Fig. 2). Above all, the ideal width of the lateral incisors must be carefully considered. When the width of the lateral incisors is between 50 and 74 % of that of the central incisors, they are perceived as being esthetic [25] (Fig. 3). However, if the gaps are set-up as being too small or too large, the dental restoration can either

- then be too narrowly or too widely designed,
- arranged in an overlapping position,
- be fitted in, but with a remaining gap
- or orthodontic measures must be carried out once again after the prosthetic treatment.

Directly after the removal of the multiband appliance, a retention splint must be worn; it is essential to ensure that the patient wears it continuously until the adhesive bridge is introduced. Otherwise, there is a risk that the teeth could move in the short time it takes for the adhesive bridge to be finished. Directly after the adhesive bridge is cemented, a retainer must be applied, as is common for all orthodontic treatments. The splinting together of the two adhesive wings can take over this function (Fig. 4).

Second interface: setting ideal tooth spaces before beginning with the restoration

Provided that several teeth in the esthetic zone must be restored with crowns, or veneers, it is always useful to prepare a wax-up in advance to check if the ideal length-width ratios and proportions of the teeth with respect to each other can be achieved. In the abrasive dentition shown here, conspicuous diastemas existed between all anterior teeth. Given the tooth positions, it was not possible to close the spaces and make sufficient vertical bite correction, and yet, still be able to create esthetically pleasing anterior esthetics (Fig. 5–7). For this purpose, anterior tooth lengths averaging 11.7 mm for the central incisors, 9.5 mm for the lateral incisors and 10.8 mm for the canines are desirable [13]. Additionally, a harmonious anterior overjet, a length-to-width ratio of the central incisors corresponding to 75–85 %, and a central to lateral incisor width ratio between 50 and 74 % should be present [25]. In order to achieve this, a gap closure by means of mesialization and a gap expansion in the premolar region took place. Based on this orthodon-tic pre-treatment, which lasted about 1 year, an esthetically pleasing and functionally appropriate prosthetic restoration could be created (Fig. 8–11).

Third interface: orthodontic extrusion for tooth preservation

The extrusion of roots often makes it possible to preserve and restore fractured or deeply destroyed teeth [3, 5]: The background behind this has to do with the planned/existing dental post in non-vital teeth having to be surrounded by at least 2 mm of healthy hard substance (adequate ferrule design). For vital abutment teeth, however, a remaining abutment height

Figures 20 and 21 Interim denture with attached elastic bands at the beginning of treatment; frontal and occlusal views.

Figures 22 and 23 Uprighting of canines after 9 weeks of wear. A clear gap is visible between the clasp and tooth 33; frontal and occlusal views

of at least 3 mm is required. Furthermore, an adequate biological width must be maintained around the abutment teeth. In the existing case, the ceramic crown on tooth 21 was paragingivally fractured. The remaining abutment did not fulfill the conditions just described for a new crown which would have a favorable long-term prognosis. The neighboring teeth 11 and 22 displayed adequate restorations. Surgical crown lengthening was not an option due to esthetic reasons, as the previous gingival profile showed a harmonious appearance. In order to preserve the tooth, the root was extruded with the help of magnets. For this purpose, a magnet with flowable composite was attached to the vital abutment tooth. The magnet had to be reduced in size beforehand so that it matched the remaining abutment tooth (Fig. 12). Using a 1 mm thick placeholder, a second magnet was positioned on top of the first magnet and fixed to a previously fabricated Miniplast splint (Fig. 13). The supracrestal periodontal fibers were additionally cut with a scalpel under local anesthesia. In one to two weeks, the root was orthodontically extruded to the desired millimeter using magnetism. By moving the magnet twice inside the splint, with a renewed adjustment of 1 mm space between the magnets, the root could be extruded approximately 3 mm over a period of 6 weeks. The costs of this preliminary measure are not included in the service catalogue of the statutory health insurance companies, and must therefore, like any other orthodontic treatments in adulthood, be covered by the patients themselves. Subsequent to this procedure, a core build-up with composite, preparation of the abutment and fabrication of a temporary crown ensued (Fig. 14). In order to prevent the tooth from migrating again, the temporary crown was fixed to the adjacent teeth with retainer wire for 4 months. After the retention period, the definitive zirconia crown could be fabricated with vestibular veneering and adhesively bonded to the abutment. Figure 15 shows the restoration half a year after placement. The tooth continues to react positively to the cold sensitivity test.

Another method to mobilize teeth is through forced extrusion using rubber bands. For this purpose, if required, bars are fixed occlusally to the adjacent teeth [14, 16]. The abutment itself is fitted with a dumbbell-shaped device in the oro-vestibular direction. Elastic bands can then be hooked in with varying amounts of force (Fig. 16–18), so that the tooth root usually extrudes within a few weeks. The supracrestal separation of the gingival fibers prevents the fixed gingiva from moving with the root. When a coronal displacement of the soft tissue is also desired, the supracrestal fibers are not cut [16]. This applies to all extrusions, regardless of the procedure.

(Fig. 1–4, 12–23: K. Groß, Fig. 5–11: S. Wolfart, Fig. 24: L. Waltenberger)

Figure 24 Appearance 3 years after cementation.

Fourth interface: conservative preparation by uprighting teeth before crown preparation

A well-known procedure and typical example includes the classical

uprighting of a molar that is inclined towards a mesial gap. We would like to present the case of an innovative, simple, and patient-oriented approach for aligning two canines. A 67-year-old patient with a remaining dentition consisting of 33, 43, and 44 in the lower jaw required a new prosthetic restoration. Owing to the inclination of the canines, the patient could hardly insert and remove the existing clasp-retained removable partial denture (Fig. 19). Besides this, the patient no longer wished for the new restorative treatment to have visible clasps. After a detailed consultation, he chose a telescopic denture. In order to have achieved a common insertion path during the preparation of the 3 abutment teeth, the canines should have been devitalized. A treatment alternative was represented by the uprighting of the two teeth in a mesial direction. The orthodontic appliance could be integrated into the already existing interim denture by applying orthodontic elements into its structure. Also, in this case, the orthodontic treatment had to be privately covered by the patient and an additional private agreement for the treatment and cost plan was created, which contained just the orthodontic measures. In order to use the time to test the new vertical bite position by means of the interim denture, a guide groove for the elastic band was prepared in cooperation with the department of orthodontics on the canines in the distal, lingual and vestibular areas. In addition, the denture teeth 31 and 41 each received a knob vestibularly to avoid protrusion or retrusion. In this way, the patient was able to attach elastics on his own, which he changed daily (Fig. 20 and 21). After 3 months, the two canines were upright enough so that their preparation could be successfully accomplished, while maintaining a common insertion path and the vitality of the pulp (Figs. 22 and 23). The retention of the two teeth was ensured by the telescopic restoration. Figure 24 shows the patient after 3 years. The two canines still respond positively to sensitivity testing.

Conclusion

In summary, a purposeful combination of prosthetic and orthodontic treatment measures can achieve better esthetics and function in many cases. This is often accompanied by a reduction in treatment duration and costs. For optimal treatment outcomes, coordinated treatment planning between the orthodontist and prosthodontist is recommended before beginning treatment.

Conflicts of Interest

The authors declare that there is no conflict of interest as defined by the guidelines of the International Committee of Medical Journal Editors.

References

1. Gesetz zur Verbesserung der Rechte von Patientinnen und Patienten. Bundesgesetzblatt 2013; 9: 277–282

2. Botelho MG, Chan AW, Leung NC, Lam WY: Long-term evaluation of cantilevered versus fixed-fixed resin-bonded fixed partial dentures for missing maxillary incisors. J Dent 2016; 45: 59–66

3. Brawek P, Schley J, Wolfart S: Zahnerhalt durch forcierte Magnetextrusion – eine Falldarstellung. Dtsch Zahnärztl Z 2013; 68: 456–462

4. Djemal S, Setchell D, King P, Wickens J: Long-term survival characteristics of 832 resin-retained bridges and splints provided in a post-graduate teaching hospital between 1978 and 1993. J Oral Rehabil 1999; 26: 302–320

5. Harder S, Mehl C, Kern M: Behandlungsmöglichkeiten bei tief frakturierten Pfeilerzähnen. Quintessenz 2010; 61: 1485–1494

6. Kern M: Fifteen-year survival of anterior all-ceramic cantilever resin-bonded fixed dental prostheses. J Dent 2017; 56: 133–135

7. Kern M: Einflügelige Adhäsivbrücken. Kieferorthopädie 2018; 32: 123–134

8. Kern M: Adhäsivbrücken: Minimalinvasiv – ästhetisch – bewährt. Quintessenz, Berlin 2018

9. Kern M, Passia N, Sasse M, Yazigi C: Ten-year outcome of zirconia ceramic cantilever resin-bonded fixed dental prostheses and the influence of the reasons for missing incisors. J Dent 2017; 65: 51–55

10. Kern M, Sasse M: Ten-year survival of anterior all-ceramic resin-bonded fixed dental prostheses. J Adhes Dent 2011; 13: 407–410

11. Kern M, Wolfart S: Kontrovers diskutiert: Versorgung von Frontzahnlücken bei Jugendlichen nach Abschluss der kieferorthopädischen Therapie. Dtsch Zahnärztl Z 2018; 73: 330–337

12. Kerschbaum T: Das Risiko des Vitalitätsverlustes nach Überkronung. DGZMK Statement 1998

13. Magne P, Gallucci GO, Belser UC: Anatomic crown width/length ratios of unworn and worn maxillary teeth in white subjects. J Prosthet Dent 2003; 89: 453–461

14. Mörig G, Svoboda R, Podolsky L: Forcierte Extrusion – ein Behandlungskonzept für bisher ausweglose Fälle. ZMK-aktuell 2017; 33: 42–50

15. Murray PE, Smith AJ, Windsor LJ, Mjor IA: Remaining dentine thickness and human pulp responses. Int Endod J 2003; 36: 33–43

16. Neumeyer S: Extrusions- und Implantationstechniken. Grundlegende Aspekte des Tissue Master Concepts (TMC) – ein biologisches Gewebemanagement. BZB 2013; November: 54–60

17. Polder BJ, Van't Hof MA, Van der Linden FP, Kuijpers-Jagtman AM: A meta-analysis of the prevalence of dental agenesis of permanent teeth. Community Dent Oral Epidemiol 2004; 32: 217–226

18. Priest G: The treatment dilemma of missing maxillary lateral incisors-Part I: Canine substitution and resin-bonded fixed dental prostheses. J Esthet Restor Dent 2019; 31: 311–318

19. Saker S, El-Fallal A, Abo-Madina M, Ghazy M, Ozcan M: Clinical survival of anterior metal-ceramic and all-ceramic cantilever resin-bonded fixed dental prostheses over a period of 60 months. Int J Prosthodont 2014; 27: 422–424

20. Schneider U, Moser L, Fornasetti M, Piattella M, Siciliani G: Esthetic evaluation of implants vs canine substitution in patients with congenitally missing maxillary lateral incisors: Are there any new insights? Am J Orthod Dentofacial Orthop 2016; 150: 416–424

21. Thilander B: Dentoalveolar development in subjects with normal occlusion. A longitudinal study between the ages of 5 and 31 years. Eur J Orthod 2009; 31: 109–120

22. Thilander B, Odman J, Jemt T: Single implants in the upper incisor region and their relationship to the adjacent teeth. An 8-year follow-up study. Clin Oral Implants Res 1999; 10: 346–355

23. Tuli T, Hachl O, Rasse M, Kloss F, Gassner R: [Dentoalveolar trauma. Analysis of 4763 patients with 6237 injuries in

10 years]. Mund Kiefer Gesichtschir 2005; 9: 324–329

24. van Dalen A, Feilzer AJ, Kleverlaan CJ: A literature review of two-unit cantilevered FPDs. Int J Prosthodont 2004; 17: 281–284

25. Wolfart S, Thormann H, Freitag S, Kern M: Assessment of dental appearance following changes in incisor proportions. Eur J Oral Sci 2005; 113: 159–165

26. Zachrisson BU, Rosa M, Toreskog S: Congenitally missing maxillary lateral incisors: canine substitution. Point. Am J Orthod Dentofacial Orthop 2011; 139: 434, 436, 438 passim

(Photo: private, Karin Groß)

DR. KARIN GROß
Clinic for Prosthodontics,
Center for Implantology, Medical
Center of RWTH Aachen University
Pauwelstr. 30
52074 Aachen
kgross@ukaachen.de

Richard J. Wierichs*, Celine Kobbe*, Hendrik Meyer-Lückel

Estimating the masking effect of post-orthodontic white spot lesions before resin infiltration

Introduction: Orthodontic treatment with fixed elements increases the risk of developing white spot lesions due to additional retention opportunities for biofilm. One approach for the esthetic treatment of these lesions is caries infiltration. In order to estimate the final masking effect of the resin infiltration, re-wetting with water or ethanol is often performed just after the etching procedure.

Patient cases: Four patients who were diagnosed with white spot lesions in the esthetically visible area during treatment with fixed orthodontic appliances were informed about the possibility of optically masking these lesions using resin infiltration. The infiltration (Icon, DMG) was performed according to the manufacturer's instructions, but the etching procedure was performed up to three times. The decision regarding whether to repeat the etching procedure was made subjectively by the practitioner during the re-wetting test with ethanol. The masking effect generated by ethanol and resin infiltration was analyzed using digital photographs before treatment, before and during the first 9 sec of re-wetting as well as one week after treatment.

Result: In all 4 patient cases, the observed minimum color difference during re-wetting appears to be a good indicator for assessing whether a satisfactory masking effect can be achieved. Furthermore, in the total of 55 treated white spot lesions, lesions with higher color value differences were etched more frequently than lesions with less pronounced color value differences. Overall, the masking effect one week after resin infiltration was satisfactory in all cases.

Discussion: During the re-wetting test, the minimum color difference between the initial lesion and the intact enamel which surrounds the lesion seems to be a good predictor of the final outcome of resin infiltration of post-orthodontic white spot lesions. Furthermore, white spot lesions with a higher initial color difference appear to require multiple etching procedures.

Conclusion: Resin infiltration is a useful microinvasive method for masking white spot lesions which develop during orthodontic treatment with fixed appliances. Moreover, the temporary masking effect achieved by the re-wetting test with ethanol can be used as an indicator for estimating the number of etching procedures required.

Keywords: caries infiltration; post-orthodontic treatment; enamel lesion; white spot lesion; esthetics

*shared first authorship Richard J. Wierichs and Celine Kobbe
Department of Restorative, Preventive and Pediatric Dentistry, University of Bern, Bern, Switzerland: Dr. Richard Wierichs; Celine Kobbe, Prof. Dr. Hendrik Meyer-Lückel
Translation from German: Christian Miron
Citation: Wierichs RJ, Kobbe C, Meyer-Lückel H: Estimating the masking effect of post-orthodontic white spot lesions before resin infiltration. Dtsch Zahnärztl Z Int 2020; 2: 168–173
Peer-reviewed article: submitted: 09.07.2020, revised version accepted: 27.07.2020
DOI.org/10.3238/dzz-int.2020.0168–0173

Introduction

Orthodontic treatment with fixed appliances increases the risk of developing initial non-cavitated carious lesions – also called white spot lesions [3]. The more difficult oral hygiene around the brackets represents an additional retention opportunity for biofilm and therefore increases the caries risk [2]. A rapid and progressive development of white spot lesions could then potentially become an esthetic concern for patients [15]. The characteristic white, opaque appearance of the lesions can be physically explained by the stronger scattering of light within the lesion's body as a result of air and saliva inclusions in comparison to the surrounding healthy enamel [13]. In literature, the prevalence of white spot lesions after treatment with fixed elements varies between 23 %, 50 % and even 97 % [10].

White spot lesions remineralize once the brackets, which represent a retention site for plaque, have been removed. Although fluoride-containing agents can be used to enhance remineralization, the esthetic appearance is usually not sufficiently improved [19]. For this reason, different prevention strategies have been employed during treatment with fixed elements, e.g. fluoride-releasing sealants or bonding materials as well as the daily use of fluoride-containing or chlorhexidine-containing mouthwashes. However, these strategies cannot prevent the development of white spot lesions [21]. After removal of the fixed elements, microabrasion represents another treatment option which is most suitable for very superficial lesions because concave tooth surfaces can develop in the case of deeper lesions [22]. Direct and indirect restorations also lead to satisfactory and predictable results, but they should only be used in cavitated lesions due to their invasive nature [18].

Another therapeutic approach for the treatment of initial, non-cavitated carious lesions is caries infiltration. This involves the obturation of the microporous enamel areas of a caries by means of flowable resins („infiltrants") so as to arrest further caries progression [17]. Furthermore, the optical appearance is positively changed by caries infiltration [11]. Yet, it is difficult to predict the masking effect during the clinical application of the procedure. The varying masking results can be explained in relation to the variable thickness of the surface layer [8, 14]. In inactive lesions, the layer is usually thicker and less permeable than in newly formed active ones [1]. In contrast, the pores of active carious lesions appear larger and the surface layer less mineralized, thus allowing the resin to penetrate deeper into the lesion's body [13]. However, to date, there is no way of estimating the ability of the infiltrant to diffuse into the (remaining) surface layer after etching. This would be desirable because it is difficult to remove the infiltrant after its application if the final result is considered not satisfactory. At the same time, a high degree of demineralization of the carious lesion is also unfavorable for attaining the most complete masking result possible.

The refractive indices of liquids are closer to the refractive index of healthy enamel than to the refractive index of air. Therefore, the application of a liquid after the etching process should permit a (temporary) assessment of whether the surface layer has been sufficiently removed in order to allow a sufficiently deep diffusion [6]. Consequently, a liquid could theoretically be used to assess the masking effect before the infiltrant is applied. In this context, based on the four cases presented in this study, it was investigated if the final infiltration result is predictable using the re-wetting test.

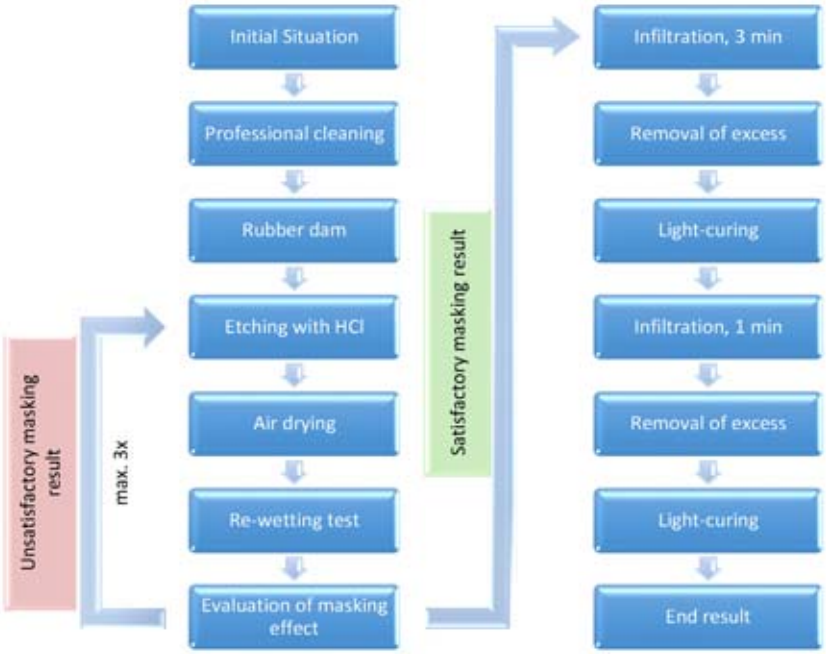

Figure 1 The treatment scheme for resin infiltration of white spots. The subjective examination of whether the masking effect was satisfactory was made during the re-wetting test. If the result was not satisfactory, the etching procedure was repeated. The etching procedure was performed up to a total of three times. Afterwards, the treatment scheme was continued.

Case studies

Four patients who complained about „white spots" on their teeth in the esthetically visible area after the removal of the fixed appliance were treated in a clinical study [10]. The white enamel areas were diagnosed as post-orthodontic white spot lesions. After the patient's consent, the infiltration procedure was performed according to the following treatment scheme (Fig. 1):

- a. Cleaning the teeth with fluoride-free polishing paste (Cleanic; Kerr, Bioggio, Schweiz)

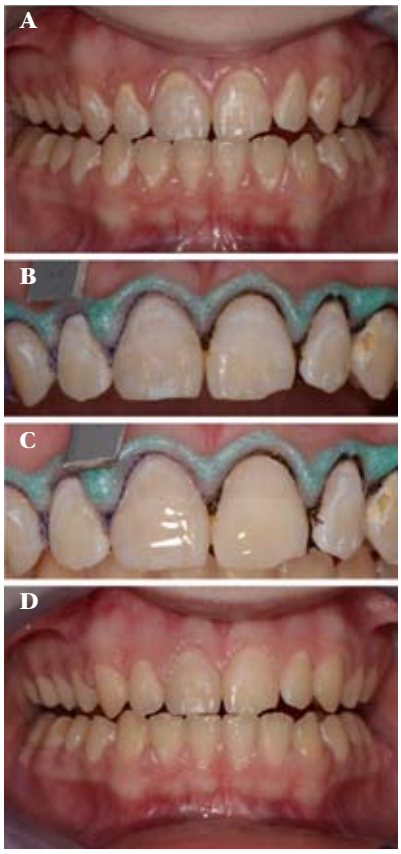

Figure 2A–D After orthodontic treatment with fixed elements, multiple white spot lesions dominated the appearance of the upper and lower jaw **(A)**. Appearance after the etching procedure **(B)**. Estimation of the masking effect during the re-wetting test **(C)**. A satisfactory final result was obtained one week after infiltration **(D)**. The color difference one week after infiltration at the cervical margins of teeth 11 and 21 **(D)** is even lower than the minimum color difference during re-wetting **(C)**. It should be noted that the partial image **(C)** only shows the re-wetting test on teeth 11 and 21. Before recording the final result **(D)**, the cavitated lesion on tooth 23 was treated with a restoration.

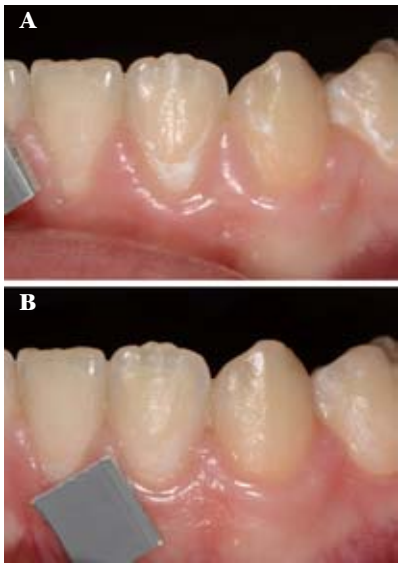

Figure 3A/B Cervical white spot lesion on tooth 33. The gray chart on the images was used to standardize colorimetric evaluation. **A:** initial situation: **B:** situation one week after resin infiltration.

- b. Application of a resin-based, light-curable barrier (OpalDam; Ultradent, South Jordan, USA) to keep the working area dry and protect the gingiva.
- c. Etching the teeth with 15 % HCl gel – 2 min per lesion (ICON etch; DMG, Hamburg, Deutschland)
- d. Removing the HCl gel and spraying with water – 30 sec per tooth
- e. Air drying the teeth with compressed air – 30 sec per tooth
- f. Re-wetting the teeth with ethanol – 30 sec per tooth (ICON dry; DMG, Hamburg, Deutschland)
- g. Air drying the teeth with compressed air – 10 sec per tooth

During the re-wetting process, the practitioner (C.K.) decided if the masking result was satisfactory. If the subjective assessment was not satisfactory, steps c–g were repeated. The etching process was performed a maximum of three times. Afterwards, the treatment scheme was continued:

- h. Application of the infiltrant – 3 min exposure time (ICON Infiltrant; DMG, Hamburg, Deutschland)
- i. Removing the excess with a foam pellet
- j. Light-curing – 40 sec per tooth
- k. Application of the infiltrant – 1 min exposure time
- l. Removing excess with a foam pellet
- m. Light-curing – 40 sec per tooth
- n. A final polishing of the infiltration area was performed (Sof-Lex; 3 M, Saint Paul, USA and Occlubrush; Kerr, Orange, USA).

In order to evaluate the masking effect, standardized digital photographs (shutter speed: 1/250, aperture: F29, ISO sensitivity: 100, white balance: 6250 K, tooth/lens distance: 20 cm) were taken at the following times: before treatment, 1 sec before ethanol application (treatment step f), in the following 9 sec (1 image per second) and one week after treatment (Fig. 2–4). Care was taken to avoid a color change due to the dehydration of the teeth.

Results

After removal of the brackets, 55 white spot lesions (ICDAS code 2, upper jaw: n = 29; lower jaw: n = 26) were diagnosed on the anterior teeth and first premolars in the 4 patients (14–16 years). The initial situation and the final treatment result are shown in Figure 2 and Figure 5. Satisfactory masking effects were achieved in all cases. This was independent of the number of etching procedures. The evaluation of the digital images after treatment showed that the number of etching procedures correlated with the initial color differences. The stronger the (remaining) color difference was estimated during the treatment, the more etching procedures were performed. Furthermore, it was shown that the subjectively perceived minimum color difference during the re-wetting test is well suited for estimating the color difference one week after infiltration. Teeth which did not show a satisfactory masking result during the first 3–5 sec of the re-wetting test were etched again (Fig. 4). Furthermore, the evaluation of the digital images confirmed that a difference in the practitioner's color perception existed; it was significantly lower one week after infiltration as compared to during re-wetting (Fig. 5).

Discussion

Based on the presented cases, the color change during the re-wetting tests, their influence on the number of etching procedures and their correlation with the masking results one week after infiltration were described. It was observed that the minimum color difference during re-wetting seems to be suitable for estimating the color difference one week after infiltration. Especially during the first

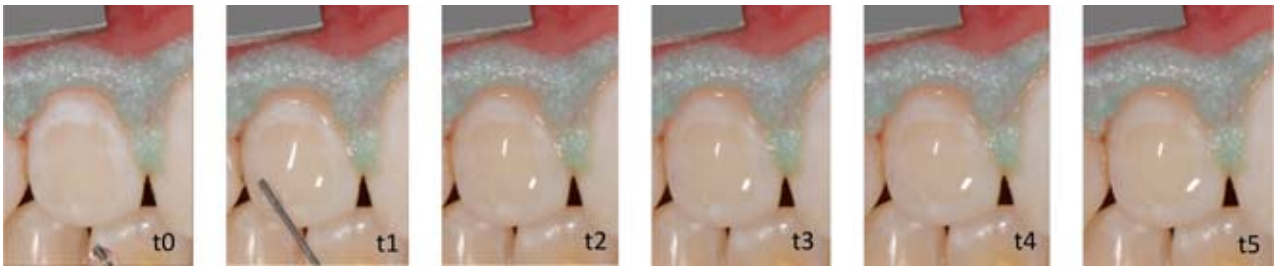

Figure 4t0–t5 Using the re-wetting test with ethanol before subsequent infiltration, it can be assessed whether the success of masking will be satisfactory for previously etched lesions **(t0)**. If masking is not satisfactory within the first 3–5 sec **(t1–t5)**, as in this case, etching with hydrochloric acid for 2 min should be repeated.

3 sec of re-wetting, there is a strong reduction in the color difference. If no considerable reduction in the color difference is subjectively detected, etching should be repeated. In any case, after resin infiltration the color difference is (even) further reduced when compared to the color difference during re-wetting. This might be explained by the higher refractive index of the infiltrant (RI = 1.51), which is closer to the refractive index of healthy enamel (RI = 1.63) than to the refractive index of ethanol (RI = 1.36). Furthermore, it could be observed that the number of etching procedures correlated with the initial color difference. The data showed a positive albeit weak correlation between the number of etching procedures and the subjective evaluation of the severity of the white spot lesion [10].

In order to achieve an esthetically satisfactory masking result for white spot lesions, it is necessary to infiltrate the body of the lesion as completely as possible [13]. For this purpose, the surface layer of the lesion has to be modified during the etching procedure so that the resin or ethanol can diffuse into the lesion. However, the thickness of this surface layer varies greatly [14]. This may help explain why the number of etching procedures, and thereby the length of the etching procedure varied, not only in these patient cases, but also in other studies [7, 8]. Depending on the esthetic appearance, the number of etching procedures and the duration of etching varied both in the previous studies and in the present patient cases. However, the maximum number of etching procedures was limited to three in order to not remove too much enamel. This was also done if the esthetic result of the re-wetting test was not satisfactory after the third etching procedure. Since each etching procedure removes between 35 µm and 45 µm of the enamel surface [14], 3 etching procedures lead to a maximum removal of 105–135 µm. This probably results in the complete removal of the surface layer in most active and also inactive lesions. A further etching procedure would therefore remove an unnecessary amount of enamel because, after the removal of the surface layer, the success of masking is likely to depend on the depth, or degree of mineralization of the lesion, instead of the remaining less porous surface layer.

The cases presented here were treated within the framework of a study which had been approved by the Ethics Committee of the RWTH Aachen University (EK 110/13) and which had already been published [10]. In this study, a total of 221 lesions in 29 patients were infiltrated and resin infiltration noticeably reduced the color difference of white spot lesions after treatment both subjectively and objectively. The final color differences were only slightly above the perceivable thresh-

Figure 5A1–C1 and A2–C2 Overview images of 3 patients with post-orthodontic white spot lesions. **A1, B1, C1:** initial situation. **A2, B2, C2:** respective clinical situation one week after infiltration. A satisfactory masking result was achieved in all 3 cases.

Authors	Year of publication	Time interval until follow-up examination	Number of patients treated/number of infiltrated lesions	Treated teeth	Results
Kim et al. [7]	2011	1 week	9 patients, 18 teeth	Anterior teeth	61 % complete, 33 % partial, 6 % no masking effect
Hammad et al. [4]	2012	Immediately	18 patients, 108 teeth	Maxillary anterior teeth (ICDAS 2+3)	Significant increase of gray scale value (= masking)
Knosel et al. [8]	2013	6 months	20 patients, 111 infiltrated and 108 control teeth	Anterior teeth and canines	ΔΔE: Infiltration -2,3 Controls +0,2 Significant improvement
Knösel et al.# [9]	2019	2 years	8 patients, 45 teeth	Anterior teeth and canines	ΔΔE: Infiltration -3,2
Senestraro et al. [20]	2013	8 weeks	20 patients, 46 infiltrated and 20 control teeth	Maxillary anterior teeth	Reduction of lesion's surface 61 % Infiltration 1 % Controls

(Fig. 1–5, Tab. 1: R. J. Wierichs and C. Kobbe)

#Post evaluation of Knösel et al. 2013

Table 1 Clinical studies investigating the masking success of white spot lesions, mostly after orthodontic treatment.

old [5]. These color differences are not perceived by the human eye from a normal social distance. Furthermore, a subgroup analysis showed that the color difference was below this threshold for 73 % of lesions that were etched just once, whereas lesions that were etched two or three times were below the threshold in only 62 % and 32 % of the cases, respectively. The final result, for lesions etched two or three times, was therefore less satisfactory than for lesions etched once. Furthermore, a strong correlation between the minimum color difference during re-wetting and the final color value one week after infiltration could be observed. It was also demonstrated that the minimum color difference during re-wetting is also well suited to assess if another etching step is necessary. The results are also consistent with previous studies [7, 8], which also showed a good masking effect using this treatment procedure for post-orthodontic white spot lesions. Further clinical studies which investigated the masking effect after resin infiltration and their results are also shown in Table 1.

Interestingly, the studies also suggest that the time interval between bracket removal and resin infiltration appears to play an important role for the successful masking of white spot lesions [8]. The shorter this time interval, the more successful the masking effect seems to be. Consequently, patients who had undergone orthodontic treatment more than 12 months ago were excluded in the present study. Furthermore, the question as to how the masking effect could be further optimized by infiltrating the white spot lesions during orthodontic treatment was raised. Thus far, however, this question has only been investigated in a non-controlled study [16] and a case report [12]. In both publications white spot lesions were infiltrated immediately after detection without interrupting orthodontic treatment. Although the results in both publications were promising, this approach has not yet been widely explored.

Conclusion

The patient cases illustrate that the temporary masking effect during the re-wetting test with ethanol, before subsequent resin infiltration, seems to be a good predictor of the final masking result and can be used to determine the necessary number of etching procedures. Furthermore, white spot lesions with a higher initial color difference seem to require more etching procedures. Overall, resin infiltration has been shown to be a useful method for masking white spot lesions occurring during orthodontic treatment.

Note from the authors

The cases presented in this article have been treated in a clinical study published in the Journal of Dentistry titled „Evaluation of the value of re-wetting prior to resin infiltration of post-orthodontic caries lesions" [10].

Conflicts of interest

R. Wierichs and C. Kobbe declare that there is no conflict of interest as defined by the guidelines of the International Committee of Medical Journal Editors.

The Charité – Universitätsmedizin Berlin (Germany) holds US and European patent for an infiltration technique for dental caries lesion in which one of the authors (Hendrik Meyer-Lückel, HML) is appointed as inventor. HML receives royalties as well as research funding from DMG (Hamburg, Germany), the manufacturer of Icon.

References

1. Ando M, Fontana M, Eckert GJ, Arthur RA, Zhang H, Zero DT: Objective and quantitative assessment of caries lesion activity. J Dent 2018; 78: 76 –82

2. Boersma JG, van der Veen MH, Lagerweij MD, Bokhout B, Prahl-Andersen B: Caries prevalence measured with QLF after treatment with fixed orthodontic appliances: influencing factors. Caries Res 2005; 39: 41–47

3. Gorelick L, Geiger AM, Gwinnett AJ: Incidence of white spot formation after bonding and banding. Am J Orthod 1982; 81: 93–98

4. Hammad SM, El Banna M, El Zayat I, Mohsen MA: Effect of resin infiltration on white spot lesions after debonding orthodontic brackets. Am J Dent 2012; 25: 3–8

5. Johnston WM, Kao EC: Assessment of appearance match by visual observation and clinical colorimetry. J Dent Res 1989; 68: 819–822

6. Kidd EA, Fejerskov O: What constitutes dental caries? Histopathology of carious enamel and dentin related to the action of cariogenic biofilms. J Dent Res 2004; 83 Spec No C:C35–38

7. Kim S, Kim EY, Jeong TS, Kim JW: The evaluation of resin infiltration for masking labial enamel white spot lesions. Int J Paediatr Dent 2011; 21: 241–248

8. Knosel M, Eckstein A, Helms HJ: Durability of esthetic improvement following Icon resin infiltration of multi-bracket-induced white spot lesions compared with no therapy over 6 months: a single-center, split-mouth, randomized clinical trial. Am J Orthod Dentofacial Orthop 2013; 144: 86–96

9. Knosel M, Eckstein A, Helms HJ: Long-term follow-up of camouflage effects following resin infiltration of post orthodontic white-spot lesions in vivo. Angle Orthod 2019; 89: 33–39

10. Kobbe C, Fritz U, Wierichs RJ, Meyer-Lueckel H: Evaluation of the value of rewetting prior to resin infiltration of post-orthodontic caries lesions. J Dent 2019; 91: 103243

11. Meyer-Lückel H, Paris S: Kariesinfiltration. In: Meyer-Lückel H, Paris S, Kim E (Hrsg): Karies: Wissenschaft und Klinische Praxis. Thieme, Stuttgart 2012, 271–283

12. Meyer-Lückel H, Wierichs R, Sheikh Ali F: Masking and arresting of caries during treatment with brackets. In: DMG Dental-Material Gesellschaft mbH (Hrsg): Icon smooth surfaces – case reports. DMG Eigenverlag, Hamburg 2019, 16–19

13. Meyer-Lueckel H, Paris S: Infiltration. In: Meyer-Lueckel H, Paris S, Ekstrand KR (Hrsg): Caries management – science and clinical practice. Thieme, Stuttgart, New York 2013, 245–258

14. Meyer-Lueckel H, Paris S, Kielbassa AM: Surface layer erosion of natural caries lesions with phosphoric and hydrochloric acid gels in preparation for resin infiltration. Caries Res 2007; 41: 223–230

15. Ogaard B: Prevalence of white spot lesions in 19-year-olds: a study on untreated and orthodontically treated persons 5 years after treatment. Am J Orthod Dentofacial Orthop 1989; 96: 423–427

16. Ogodescu A, Ogodescu E, Talpos S, Zetu I: [Resin infiltration of white spot lesions during the fixed orthodontic appliance therapy]. Rev Med Chir Soc Med Nat Iasi 2011; 115: 1251–1257

17. Paris S, Schwendicke F, Keltsch J, Dorfer C, Meyer-Lueckel H: Masking of white spot lesions by resin infiltration in vitro. J Dent 2013; 41 (Suppl 5): e28–34

18. Sadowsky SJ: An overview of treatment considerations for esthetic restorations: a review of the literature. J Prosthet Dent 2006; 96: 433–442

19. Sardana D, Zhang J, Ekambaram M, Yang Y, McGrath CP, Yiu CKY: Effectiveness of professional fluorides against enamel white spot lesions during fixed orthodontic treatment: A systematic review and meta-analysis. J Dent 2019; 82: 1–10

20. Senestraro SV, Crowe JJ, Wang M et al.: Minimally invasive resin infiltration of arrested white-spot lesions: a randomized clinical trial. J Am Dent Assoc 2013; 144: 997–1005

21. Wiechmann D, Klang E, Helms HJ, Knosel M: Lingual appliances reduce the incidence of white spot lesions during orthodontic multibracket treatment. Am J Orthod Dentofacial Orthop 2015; 148: 414–422

22. Wong FS, Winter GB: Effectiveness of microabrasion technique for improvement of dental aesthetics. Br Dent J 2002; 193: 155–158

(Photo: Richard J. Wierichs)

DR. RICHARD J. WIERICHS
Department of Restorative, Preventive and Pediatric Dentistry, University of Bern, Bern, Switzerland
Freiburgstr. 7
3010 Bern, Switzerland
richard.wierichs@zmk.unibe.ch

Lukas Brämswig, Tamara Pollak, Marie-Theres Richter, Isabel Knaup, Michael Wolf

Orthodontics for adults – current innovations and interdisciplinary possibilities

Introduction: At this point in time, treatment of adult patients is part of the everyday lives of orthodontists. There is no difference when determining the indication for therapy in children and adolescents: the goal is the prevention and treatment of misalignments of jaws and teeth, as well as maintaining a healthy masticatory system.

Discussion: Nevertheless, there are some characteristics that need to be taken into consideration: The biomechanics should be adjusted in accordance to the progressing loss of attachment. Simultaneously, there is a great desire for preferably subtle treatment options. Furthermore, interdisciplinary treatment concepts play a more important role in adults compared to children and adolescents.

Results: The digitalization in orthodontics resulted in new and innovative therapy options for all these requirements. Generated data records using intraoral scans offer various options in diagnosis as well as planning in order to improve treatments and patient comfort. Special orthodontic software solutions were necessary to establish individualized therapy concepts. Treatment appliances with different systems can be printed using the export of STL data and made available for orthodontists. Further advances are expected in the next few years, which makes digital orthodontics an exciting work field.

Keywords: digital orthodontics; orthodontics for adults; 3D-print; CAD/CAM restorations; interdisciplinary orthodontics

Clinic for Orthodontics, University Hospital of the RWTH Aachen: Dr. Lukas Brämswig, Tamara Pollack, Dr. Marie-Theres Richter, Dr. Isabel Knaup, University Prof. Dr. Michael Wolf
Translation from German: Yasmin Schmidt-Park
Citation: Brämswig L, Pollak T, Richter MT, Knaup I, Wolf M: Orthodontics for adults – current innovations and interdisciplinary possibilities. Dtsch Zahnärztl Z Int 2020; 2: 174–180
Peer-reviewed article: submitted: 18.03.2020, revised version accepted: 15.04.2020
DOI.org/10.3238/dzz-int.2020.0174–0180

Introduction

Orthodontics is no longer limited to the treatment of children and adolescents. At this point, the treatment of adult patients is part of the clinical everyday life of this field of dentistry. In the years 2012 to 2014, every fourth patient undergoing orthodontic treatment in the US and Canada was over 18 years old [1]; the tendency is increasing. There are a number of reasons that explain this tendency:

An increased awareness for oral health exists in today's society and tooth position is also especially important for adult patients. It is socially established that straight and white teeth are considered healthy and attractive, whereas dysgnathia can lead to negative reactions in the social environments [18].

The optimized dental supply situation in the last several decades and the demographic change leads to the inevitable increase in average age in the orthodontic practice: an aging patient collective has a higher demand to optimize the position of their own natural teeth. However, adults do not just turn to orthodontists for aesthetic reasons: From a prophylactic periodontal point of view, it is advisable for older patients to correct misaligned teeth in order to prevent changes in bone structure caused by unequal load distribution.

Even with interdisciplinary questions such as pre-prosthetic distribution or pre-surgical formation of dental arches, the dental disciplines should work hand in hand in order to achieve the best possible results for the patients.

Orthodontic treatment can be subtly designed by using established treatment methods such as lingual therapy or aligner therapy, which is desired by patients that reject a conventional therapy due to the temporary unaesthetic impairment. With the advances in digital orthodontics, new exciting approaches for individualized treatment planning and execution are available [6, 10, 11, 23].

Special requirements in orthodontics for adults

The orthodontic treatment of adult patients has underlying special features. Generally, as with any patient, a periodontal screening should be done before orthodontic treatment and the patient should be referred to a dentist if there is any demand for treatment. This is indispensable, because otherwise the orthodontic therapy contributes to a progression of periodontal destruction on inflamed periodontium [20].

Usually, there is a thicker compact bone, increased attachment loss and less vascularisation of the bone with increasing age, which can to some extent be accompanied with restriction of tooth movement. Additionally, adults more often take medications that can affect the bone metabolism and therefore also impact the orthodontic therapy (Tab. 1).

Following the attachment loss, the center of resistance of the teeth is displaced more apically, and the orthodontic forces have to be adjusted. Further anchoring measures should be taken into consideration, because periodontally weakened teeth cannot compensate for the opposing forces in orthodontic therapy anymore. Mini implants can provide remedy, and will be discussed further down in this article.

The adult patients' desire

Adult patients seek out orthodontists especially with the desire to carry out a subtle treatment in a foreseeable time period. The lingual multi bracket therapy offers patients a very popular alternative to vestibular braces. Tooth movements can be carried out efficiently in all 3 spatial planes using a completely individualized apparatus (Fig. 1–3).

By establishing aligner therapy, orthodontists were given another tool to reach the desired treatment result step-by-step in a gentle manner. Nevertheless, it shall be noted that a selection of suitable patients as well as the dentists' experience with the system are imperative for successful treatment using aligners.

Current innovations in orthodontics

In order to meet the desire of adult patients, digital technologies are useful to carry out accurate and individualized planning. Digital orthodontics consists of 3 components:

1. Scan system (intraoral scanner or model scanner)
2. CAD software
3. 3D-print

Scan systems

The basis for a digital workflow is always a three-dimensional data set, usually generated by an intraoral scan. If no intraoral scanner is available, a model scanner can always be used as well. Different scan systems have been established for a few years in orthodontics and contribute to drive out the conventional impressions further and further. The precision of powder-free intraoral scans complies with that of the classic impression [13], however, it offers significantly greater patient comfort.

CAD software

This generated data set can then be imported into a suitable CAD-soft-

Figure 1–3 Treatment of an adult patient with a complete individualized lingual applicance

Figure 4 Segmented digital model after intraoral scan (3Shape TRIOS 3)

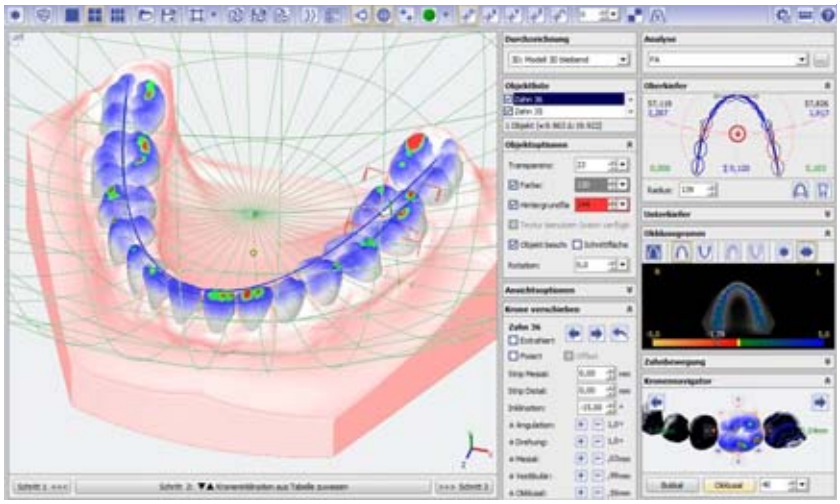

Figure 5 Orthodontic analysis of a digital model using the orthodontic software OnyxCeph^{3TM}

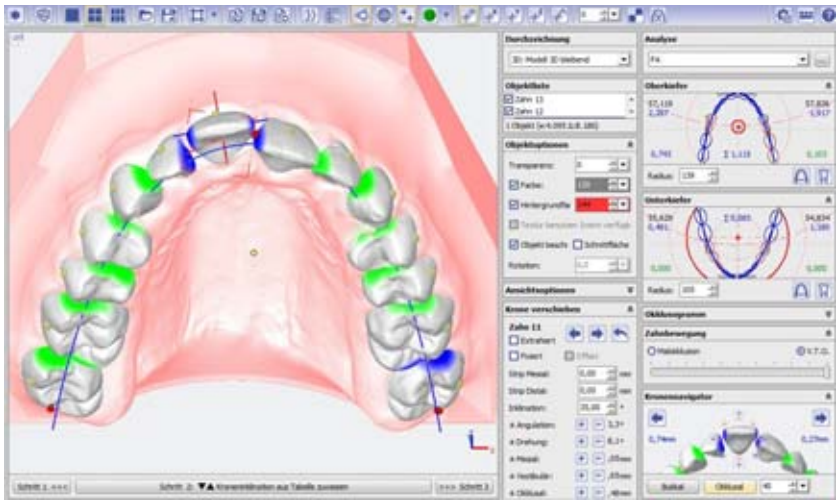

Figure 6 Creation of a digital set-up using the orthodontic software OnyxCeph^{3TM}

ware that takes care of further processing (Fig. 4). The all-digital procedure of the diagnosis, the planning and the subsequent implementation of the therapy is sketched out below and the advantages of digitalization are shown.

In our clinic we use the software OnyxCeph^{3TM} (image instruments). The workflow in digital orthodontic diagnosis includes digital photography, digital x-rays and the digital impressions mentioned above.

A full evaluation of patient documents can be done based on the generated data and then has to be supplemented with a clinical examination. The intraoral and extraoral images as well as the cephalometric x-rays can be measured and analyzed on a computer. Also the three-dimensional model can be evaluated via software (Fig. 5). Studies show that the accuracy of digital models is equal to the conventional evaluation of plaster models and sooner or later will depict the new gold standard in orthodontic diagnosis [17].

When diagnosis is completed and a type of therapy has been chosen, it can be planned and designed digitally. Lingual therapy and aligner therapy belong to the subtle treatment methods that are preferred by adult patients as described above. These usually assume a set-up which simulates the desired final position of the teeth. In the past, the well known and complex manual steps using a saw-cut model was necessary.

This is now digitally possible in a substantially precise and effective approach (Fig. 6). Teeth can be individually segmented and subsequently moved freely in the spatial planes according to the desired target position using the appropriate software.

In lingual therapy, individualized arches can be calculated using the set-up produced specifically for the patient. These can be manually bent using a printed drill template. Alternatively, the arch geometry in the CSV format can be transmitted to a bending robot, which leads to a reduction in time and increase in precision. The therapeutic transversal expansion of dental arches depicts a risk in stabilization of orthodontic

Type	Substance	Appearance/ Application	Effects	Impact on bone and tooth movement
Medication	NSAID (Aspirin, Ibuprofen)	Analgesic, anti-inflammatory	Bone resorption ↓	Tooth movement ↓
	Paracetamol	analgelsic	No effects	No impact
	Bisphosphonates	Osteoporosis, cancer treatment	Bone resorption ↓	Tooth movement ↓
	Insulin, Metformin	Diabetes mellitus	Bone stabilization ↑	Tooth movement ↓
	Vitamin D	Pregnancy, breastfeeding period, depressions	Bone resorption ↑	Tooth movement ↑
	Eicosanoids (prostaglandins, leukotrienes etc.)	mediators	Bone resorption ↑	Tooth movement ↑
	Flouride	Osteoporosis, caries prophylaxis	Bone resorption ↓ Bone mass ↑ Bone density ↑	Tooth movement ↓

Table 1 Medications and their effect on the bone and tooth movement
(Fig. 1–16; Tab. 1: L. Brämswig)

treatments [22]. First initial data show that a more stabilized tooth position can be achieved following individualized therapy [Wolf et al., submitted].

Clinical expertise is indispensable for digital planning of aligner therapy in order to assess limits of movements and plan helpful tools such as attachments correctly. Furthermore, in many cases an additional anchoring is required. Should this anchoring demand be maximal, a skeletal anchoring in the form of mini implants (TAD; temporary anchorage device) can be chosen. Because of this, tooth movements can be executed that usually can only be carried out with severe side effects. Examples of this are mesial and distal movements of molars, intrusions of individual elongated teeth, mass retractions and distractions of individually impacted teeth [3].

Ideally, the insertion of such a TAD is planned digitally. Depending on the intended application, the mini implant must be inserted in another region. Anatomic structures in the immediate topographic surroundings such as roots of teeth, inferior alveolar nerve and palatal artery have to be spared.

In order to guarantee this, a drilling template can be used. These can be manufactured conventionally in the lab or using CAD/CAM procedure. For this, an x-ray is super-

Figure 7 Superimposition of intraoral scans of the upper jaw with a cephalometric x-ray

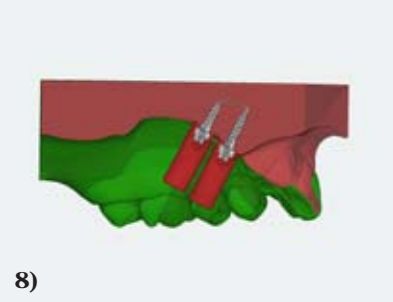

8)

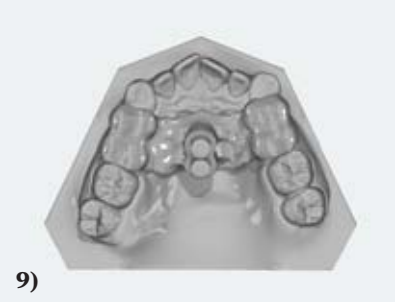

9)

10)

Figure 8–10 Digital positioning of the mini implants with subsequent design of the drill template

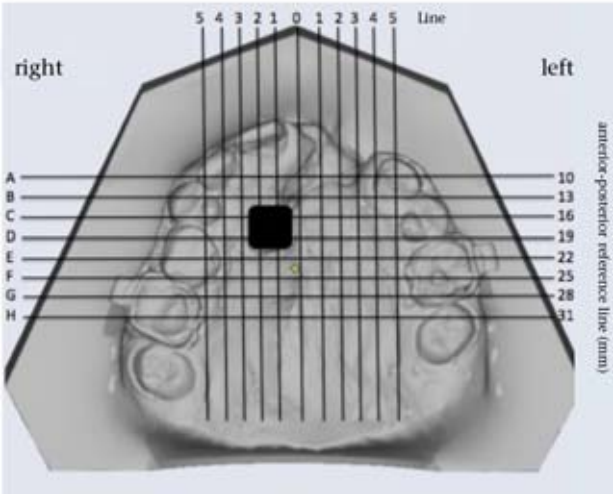

Figure 11 Best possible place of insertions for mini implants on the unaffected side

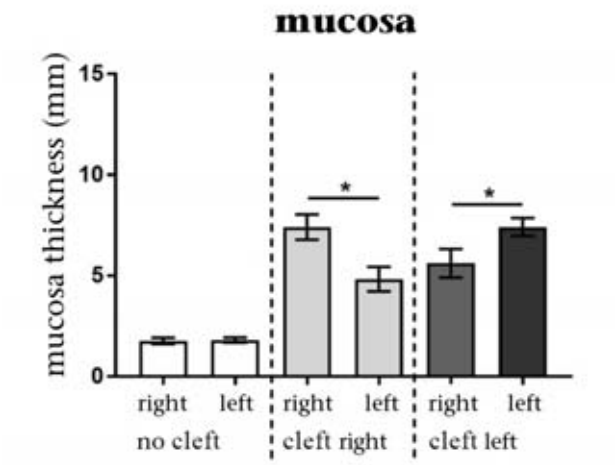

Figure 12 Small mucosa thickness in non-cleft patients in comparison to cleft-patients

imposed with the intraoral scan (Fig. 7). For palatal mini implants a cephalometric x-ray is usually used. If a TAD is inserted interradicular, a CBCT (cone beam CT) is required for the superimposition process. With this, an accurate positioning of the mini implants can be planned digitally under consideration of the immediate anatomic structures. As soon as the desired position and angulation of the mini implant is determined, a separate model is generated that defines the direction of insertion. It can then be used to design a drilling template in the desired extent (Fig. 8–10).

Using a CAD/CAM-drilling template guarantees better control during insertion and reduces the risk of deviation of the planned path of insertion, especially with inexperienced practitioners [2].

Difficult anatomic structures are another indication for a CBCT while planning mini implants.

In our own investigations we were able to show significant superimposition of mucosa of the anterior palate in patients with unilateral cleft lip and palate. The best region of insertion on the affected half of the jaw is the transition of premaxilla and maxilla [14] (Fig. 11 and 12).

A combination of mini pins and aligners has been proven to be clinically practical and therefore broadens the indication spectrum of aligner treatments in selected cases [21].

Digital tools are available for the traditional vestibular bracket treatment. The correct positioning of the brackets at the beginning of the treatment have a significant influence on the orthodontic treatment success. The conventional tooth banding of the patient is usually done adhesively on the patient directly, where every bracket is placed on each tooth individually, positioned, and then cured. Alternatively, transfer trays can be manufactured to transfer into the patient's mouth. This requires a previous laboratory process, however, it offers advantages for patient and practitioner by reducing chair time. Studies could also show that indirect adhesion guarantees a more precise bracket positioning in the vertical plane [12].

Meanwhile, a transfer tray such as this can also be planned and designed digitally. The basis here is also a segmented model via software that simulates the roots of teeth. Based on the axis of the tooth, brackets can be positioned correctly virtually. On top of the correct position of the bracket, a positioning template can be designed, saved as an STL data set and submitted to the printer (Fig. 13). The brackets can be placed In the CAD-CAM drilling template and transferred indirectly into the patient's mouth. Initial investigations from our clinic show that a good transfer of the digitally planned bracket position can be achieved.

The planning and design of individualized metallic devices is another option to design treatment devices using a suitable software offer. A patient-specific adjustment of treatment devices was already possible before, however, the usage of pre-fabricated goods in anatomic conditions that vary widely from the norm is always associated with restrictions.

Digital methods also show efficient solution approaches, so that, ideally, delicate devices can be ad-

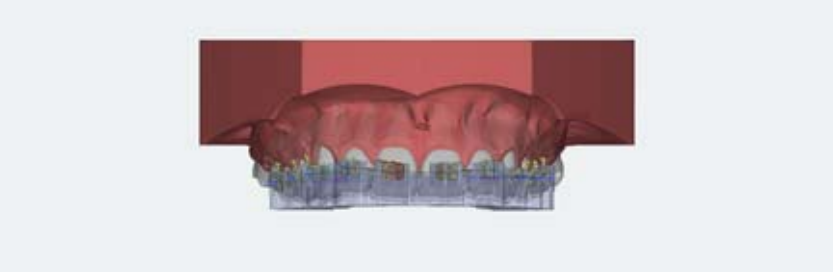

Figure 13 Digital positioning of brackets with subsequent design of a transfer tray

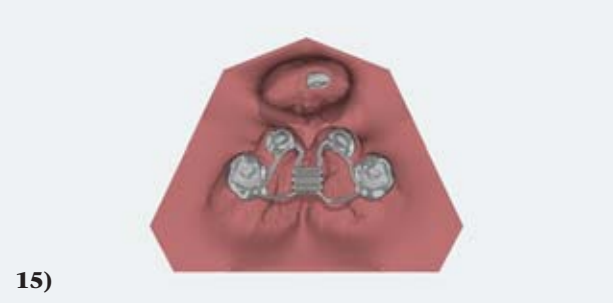

Figure 14 and 15 Individualized design of an appliance for palate expansion in a patient with double-sided cleft lip palate

justed individually and subsequently manufactured (Fig. 14 and 15). Besides the advantage of the highly precise fit, it can also lead to shortened appointments because the separation for conventional bands is not necessary in digitally produced devices.

3D-print

All previously depicted procedures of therapy planning and design of treatment devices via a CAD software lead to a 3D print. Sprockets for aligners, drill templates for mini implants or bonding trays for bracket transfers can be saved as STL data sets and submitted to a printer. Depending on the indication there are various procedures available, and in dentistry especially the SLA (stereolithography), DLP (Digital Light Processing) and the FDM print (Fused Deposition Modeling) have become established. Resin-printers can usually impress with shorter printing times, whereas the post processing in form of alcoholisation and post-curing of filament printers is omitted. Orthodontic questions can be achieved with any of the systems [5, 9], even though further advances can be expected in the next few years. Another form of the 3D print is the SLM Printing (selective laser melting), which can be used to manufacture metallic devices. The acquisition of a printer like that is currently extremely cost-intensive for the single practice, but an external printer on larger labs is already provided. In an additive production process the material to process in powder form is melted layer by layer. A cobalt chrome alloy is usually used in orthodontic devices.

Interdisciplinary orthodontics

Besides digital innovations in orthodontics mentioned above, there are also benefits offered in the interdisciplinary exchange. Dental colleagues can simultaneously consult on corresponding questions in their workspace using a digital model without having to refer to the plaster model.

Not only the purely orthodontic treatments, but also interdisciplinary treatment of patients offer interfaces that have led to treatment progress thanks to digital technologies.

Thus, operation splints were designed and subsequently printed using a 3D-data set in a CAD/CAM procedure. Studies could show that an equal or higher precision in production was achieved in less time compared to conventional splints [7, 8, 24, 25].

Furthermore, a VTO (visual treatment objective) can be created in patients treated by orthognathic surgery in order to set up a pre-therapeutic prognosis for the soft tissue profile after corrective osteotomy. This tool can be used for demonstration and patient communication, however, it should be implemented carefully to not incite unrealistic expectations [15]. Such a VTO can be generated either using two-dimensional or three-dimensional data sets, where the latter produces more precise prognoses [19].

In addition, in another working field between surgical dentists and orthodontists, there are new and exciting approaches to improve care of patients. In patients with agenesis or premature tooth loss, orthodontic space closure is not always the first choice. Prosthetic restorations, which definitely yield great results, are often needed to completely close such spaces. In selected cases, the autogenous transplantation of a tooth into the aplastic region offers a great predictable therapy option [16]. If a three-dimensional x-ray is present, that tooth that is to be transplanted can be deducted and printed pre-operatively using a DICOM data set of the CBCT. The generated template is then tried on in the region that needs to be treated during the surgery. This has the advantage, that the bone can be prepared optimally, which is accompanied with little bone loss. Also, the extra-alveolar time of the tooth as well as the damage of PDL cells is minimized during the operation, which leads to an improved prognosis of the treatment [4].

There are also new paths of treatment seen in other dental treatments. If a dentist wishes to treat

Figure 16 Individualized straightening appliance to extrude the tooth 37 for subsequent restoration of a subgingival defects

subgingival defects of a tooth by extruding that tooth, a strong anchoring should be chosen in patients that are not banded in order to avoid unwanted side effects on neighboring teeth. Through the SLM printing, the rigid and also delicate apparatus as described above can be designed with the desired tooth movements without loss of anchoring (Fig. 16). After successful extrusion the dentist can proceed with the treatment of the tooth.

Conclusions

Using digital treatment methods, various new approaches are given in orthodontics that facilitate and improve therapy. Moreover, new ranges of treatment appeared that could be used in interdisciplinary questions and therapy planning and therefore contribute to treatment success. Thanks to the advances in 3D-print-technology it will lead to exciting innovations in the future.

Conflicts of interest

The authors declares that there is no conflict of interest within the meaning of the guidelines of the International Committee of Medical Journal Editors.

Literatur

1. American Association of Orthodontists (2014). Adults are seeking orthodontic treatment in record numbers. https://us.dental-tribune.com/news/adults-are-seeking-orthodontic-treatment-in-record-numbers/

2. Cassetta M, Altieri F, Di Giorgio R, Barbato E: Palatal orthodontic miniscrew insertion using a CAD-CAM surgical guide: description of a technique. Int J Oral Maxillofac Surg 2018; 47: 1195–1198

3. Chang HP, Tseng YC: Miniscrew implant applications in contemporary orthodontics. Kaohsiung J Med Sci 2014; 30: 111–115

4. Curtis JMT, Foster EC, Ananth S et al.: Autotransplantation of a surgically removed canine using a customised 3D-printed surgical template. J Orthod 2020; 47: 82–90

5. Dawood A, Marti Marti B, Sauret-Jackson V, Darwood A: 3D printing in dentistry. Br Dent J 2015; 219: 521–529

6. Elnagar MH, Aronovich S, Kusnoto B: Digital workflow for combined orthodontics and orthognathic surgery. Oral Maxillofac Surg Clin North Am 2020; 32: 1–14

7. Gateno J, Xia J, Teichgraeber JF, Rosen A, Hultgren B, Vadnais T: The precision of computer-generated surgical splints. J Oral Maxillofac Surg 2003; 61: 814–817

8. Hammoudeh JA, Howell LK, Boutros S, Scott MA, Urata MM: Current status of surgical planning for orthognathic surgery: traditional methods versus 3D surgical planning. Plast Reconstr Surg Glob Open 2015; 3: e307

9. Hazeveld A, Huddleston Slater JJ, Ren Y: Accuracy and reproducibility of dental replica models reconstructed by different rapid prototyping techniques. Am J Orthod Dentofacial Orthop 2014; 145: 108–115

10. Knaup I, Wagner Y, Wego J, Fritz U, Jäger A, Wolf M: Potential impact of lingual retainers on oral health: comparison between conventional twistflex retainers and CAD/CAM fabricated nitinol retainers: a clinical in vitro and in vivo investigation. J Orofac Orthop 2019; 80: 88–96

11. Knösel M, Klang E, Helms HJ, Wiechmann D: Lingual orthodontic treatment duration: performance of two different completely customized multi-bracket appliances (Incognito and WIN) in groups with different treatment complexities. Head Face Med 2014; 10: 46

12. Koo BC, Chung CH, Vanarsdall RL: Comparison of the accuracy of bracket placement between direct and indirect bonding techniques. Am J Orthod Dentofacial Orthop 1999; 116: 346–351

13. Kurz M, Attin T, Mehl A: Influence of material surface on the scanning error of a powderfree 3D measuring system. Clin Oral Investig 2015; 19: 2035–2043

14. Moscarino S, Scholz J, Bastian A, Knaup I, Wolf M: Bone and soft tissue palatal morphology and potential anchorage sides in cleft palate patients. Ann Anat 2019; 224: 41–46

15. Peterman RJ, Jiang S, Johe R, Mukherjee PM: Accuracy of Dolphin visual treatment objective (VTO) prediction software on class III patients treated with maxillary advancement and mandibular setback. Prog Orthod 2016; 17: 19

16. Regoje A: Erfolgsraten nach Zahntransplantation. Eine retrospektive Studie. Diplomarbeit Medizinische Universität Graz (2014)

17. Rossini G, Parrini S, Castroflorio T, Deregibus A, Debernardi CL: Diagnostic accuracy and measurement sensitivity of digital models for orthodontic purposes: a systematic review. Am J Orthod Dentofacial Orthop 2016; 149: 161–170

18. Scheffel DLS, Jeremias F, Fragelli CMB, Dos Santos-Pinto LAM, Hebling J, de Oliveira OB Jr.: Esthetic dental anomalies as motive for bullying in schoolchildren. Eur J Dent 2014; 8: 124–128

19. Van Hemelen G, Van Genechten M, Renier L, Desmedt M, Verbruggen E, Nadjmi N: Three-dimensional virtual planning in orthognathic surgery enhances the accuracy of soft tissue prediction. J Craniomaxillofac Surg 2015; 43: 918–925

20. Wennström JL, Stokland BL, Nyman S, Thilander B: Periodontal tissue response to orthodontic movement of teeth with infrabony pockets. Am J Orthod Dentofacial Orthop 1993; 103: 313–319

21. Wilmes B, Nienkemper M, Drescher D: Der Beneslider zur Distalisierung im Oberkiefer. Inf Orthod Kieferorthop 2013; 45: 42–50

22. Wolf M, Schulte U, Küpper K et al.: Post-treatment changes in permanent retention. J Orofac Orthop 2016; 77: 446–453

23. Wolf M, Schumacher P, Jäger F et al.: Novel lingual retainer created using CAD/CAM technology: evaluation of its positioning accuracy. J Orofac Orthop 2015; 76: 164–174

24. Wrzosek MK, Peacock ZS, Laviv A et al.: Comparison of time required for traditional versus virtual orthognathic surgery treatment planning. Int J Oral Maxillofac Surg 2016; 45: 1065–1069

25. Zinser M, Zoeller J: Computer-designed splints for surgical transfer of 3D orthognathic planning. Facial Plast Surg 2015; 31: 474–490

(Photo: Lukas Brämswig)

DR. LUKAS BRÄMSWIG
Clinic for Orthodontics, University Hospital of the RWTH Aachen
Pauwelstr. 30
52074 Aachen
sbraemswig@ukaachen.de

Philipp Winterhalder, Nassim Ayoub, Stephan Möhlhenrich, Ali Modabber, Frank Hölzle

Advances and limits in planning and implementing orthognathic surgery

Introduction: Orthognathic surgery has steadily developed since its establishment in 1849, and is characterized by consistent collaboration with orthodontics.

Materials and Methods: Computer-based operation planning, that also takes resulting changes in soft tissue into account, can now be carried out through three-dimensional X-ray imaging, face scans and powerful data processing. This procedure can also be used to produce individualized osteosynthesis material and osteotomy templates, which in combination even enable orthognathic surgery without the use of an occlusal wafer. Piezo surgery represents a minimally invasive alternative to conventional methods for the osteotomy. As an alternative to titanium, resorbable polymers can also be used as osteosynthesis material.

Conclusion: Due to modern orthodontics and computer-based operation planning, the surgery-first concept enables orthognathic surgery without prior orthodontic treatment for eligible cases. The effects of orthognathic surgery on the upper airway must be considered during planning. In addition to treating dysgnathia, orthognathic surgery expands the upper airway and has become established as a treatment option for obstructive sleep apnea.

Keywords: computer-based surgery planning; prediction of soft tissue changes; individualized osteosynthesis material; resorbable osteosynthesis material; surgery first; piezosurgical osteotomies; effects on the upper airways

Clinic of Oral and Maxillofacial Surgery of the University Hospital RWTH Aachen: Dr. Dr. Philipp Winterhalder, Dr. Dr. Nassim Ayoub, PD Dr. Dr. Ali Modabber, Univ.-Prof. Dr. Dr. Frank Hölzle
Department of Dental, Oral and Orthodontic Medicine, University Hospital Witten/Herdecke: PD Dr. Stephan Möhlhenrich
Translation from German: Yasmin Schmidt-Park
Citation: Winterhalder P, Ayoub N, Möhlhenrich S, Modabber A, Hölzle F: Advances and limits in planning and implementing orthognathic surgery. Dtsch Zahnärztl Z Int 2020; 2: 181–187
Peer-reviewed article: submitted: 16.03.2020, revised version accepted: 09.07.2020
DOI.org/10.3238/dzz-int.2020.0181–0187

Introduction

Orthognathic surgery has been characterized by continuous advancement since its origin. In order to classify the current advancements and limitations, it is worth taking a brief look at the history of orthognathic surgery [38]. The first orthognathic surgery was performed by the American surgeon Hullihen in 1849. He normalized the mandibular length of a female patient with burn-related deformities with anterior segmental osteotomy [13]. Among others, two principle pioneers of early orthognathic surgery are considered to be Angle and Blair, who together described standardized mandibular osteotomies in 1907 as a treatment for mandibular prognathism [5, 38]. Blair also began classifying types of dysgnathia and realized the importance of orthodontics [38]. Many other surgeons described various different procedures for mandible correction, however, due to high rate of recurrence and significant risks they were unable to implement these at the time [38].

This was followed by the development of osteotomies that are used today (Fig. 1): Wassmund displaced the maxilla with an anterior segmental osteotomy in 1935 to treat maxillary protrusion [43]. In 1955, Trauner performed the reversed L-shaped osteotomy of the mandibular ramus to treat mandibular prognathism with shortened mandibular ramus [41]. Schuchardt described the posterior maxillary osteotomy in the same year, as well as the diagonal, sagittal osteotomy of the mandibular ramus to increase bone apposition [33]. Köle performed osteotomies of the alveolar process in both jaws in 1959, as well as genioplasty in 1968 [20, 21]. In 1955, Obwegeser developed the revolutionary sagittal split osteotomy of the mandibular ramus [30], which was modified by Dal Pont in 1958 [9] and von Hunsuck in 1968 [14]. In 1969, Obwegeser performed the protrusion of the maxilla with a Le Fort-I osteotomy and combined this with a mandible correction in 1970, making this the first corrective osteotomy of both jaws [28, 29]. In addition to the development of the effective osteotomies, the postoperative stability of the jaws is mainly due to the advancement of osteosynthesis procedures. A working party for osteosynthesis founded in 1958 in Switzerland is still at the forefront of this research today.

In addition to surgical aspects, orthodontic treatment and interdisciplinary treatment planning is absolutely crucial for a successful therapy of dysgnathia. Major progress in orthodontics was described in 1984, specifically the possibility of using mini screws as means of skeletal anchoring [8]. When compared to its beginnings, modern day orthodontics is more gentle, faster and can even supersede lengthy preoperative tooth movement in certain cases.

The basis of interdisciplinary treatment planning is still individualized cephalometry, which was introduced in 1974 by Hasund and further developed with Segner [10, 35]. Additionally, detailed model analyses and clinical investigations were also carried out. Treatment plans tend to mostly structure in preoperative measures, for example orthodontic pretreatment, followed by orthognathic surgery to displace one or both jaws, and orthodontic follow-up treatment. Close collaboration between orthodontics and maxillary surgery is necessary during all treatment stages. After completing pretreatment, a model operation is performed to plan the orthognathic surgery, where the planned displacement can be implemented from previous analysis. Besides the reliable model operation using plaster models in articulators, digital operation planning is gaining more importance. Current progress in orthognathic surgery is characterized by digitalization, new materials, minimal invasiveness and an individually optimized treatment result. In the following, computer-based operation planning, prediction of soft tissue changes, individualized and absorbable osteosynthesis material, the surgery-first concept, piezosurgical orthognathic surgery and the effects on the upper airways are explained.

Computer-based operation planning

The analog operation planning using plaster models, face bow, articulators and wax bites has proven itself reliable over decades. Computer-based operation planning has become established as an alternative in research and patient care due to the increasing availability and advancement of digital technologies.

Apart from the analog and digital approach, the exact recording of dental, skeletal, functional and aesthetic difficulties is an absolute necessity for



Figure 1A–C Course of common osteotomy lines in jaw corrections, lateral view **(A)**, semi-profile **(B)** and frontal view **(C)**: on maxilla in Le Fort-1 plane (blue), on mandible via bilateral sagittal split osteotomy (green) and if needed with additional genioplasty (red).

successful planning. In addition to orthodontic and maxillofacial expertise, individualized cephalometry, model analysis and the clinical investigation are the basis of the treatment planning.

The operation planning should not be viewed as an isolated part, but rather as part of the treatment plan. Similar to analog operation planning, the digital method leads to success when the practitioner has the ability to gather and understand the underlying individual dental, skeletal, aesthetic and functional parameters and their deviation. Recent findings of cephalometric fundamental principles, such as the harmony box, enable the optimal use of benefits of 3-dimensional, computer-based dysgnathia-planning.

The individualized cephalometry sets the basis for a successful treatment, despite new analysis and planning methods. The holistic diagnosis to differentiate between dental and skeletal causes is made possible with individualized cephalometry. Furthermore, this enables the analysis of facial proportions as well as the assessment of mutual dependencies in sagittal and vertical direction. The individualized cephalometry helps to adjust the Curve of Spee and Wilson, correctly plan the axial position of the front teeth in jaw rotations and estimate the autorotatory effects when changing the vertical relation. However, software programs for digital operation planning offer reduced determination of cephalometric parameters, or parameters that are not comparable with classic parameters. Program designers should offer a complete cephalometric analysis. After completing comprehensive diagnostics, it is not only possible to create operation splints, but also to create analyses and predictions for soft tissue. Especially in the case of asymmetries digital operation planning is helpful because mirror images can be made for optimal adjustment. Movements of the skeletal bases can only be assessed roughly, which is why cephalometric analysis of required movements ist helpful at the beginning of treatment planning. The patient should be informed about measurement and prediction errors of the used equipment and programs during the analysis and prediction of soft tissue changes, in order to avoid unrealizable, specific expectations and even legal concerns. The computer-based operation planning combined 3-dimensional x-ray data from a DVT or CT with a digital impression of the dental arches. Additionally, a face scan was done to analyze the soft tissue. These data sets are used to create a complete model which simulates the operation using a planning software.

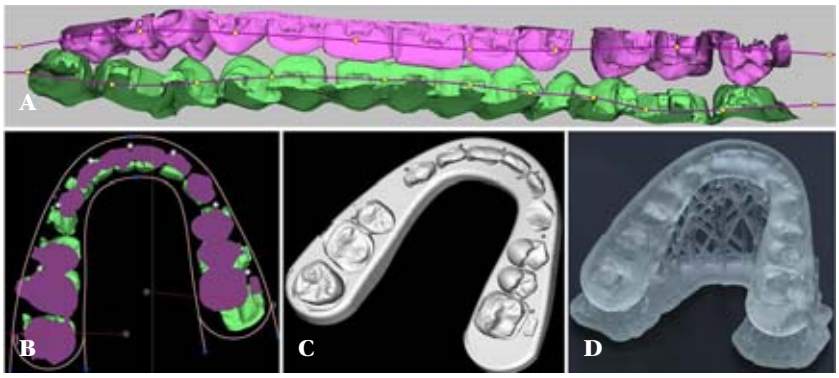

(Fig. 2–4 from [44]; With friendly permission of teamwork media GmbH)

Figure 2A–D Digital production of splints with dental arches after the planned displacement **(A** and **B)**. The splint is produced as an STL-file **(C)** and is printed in 3-D **(D)**.

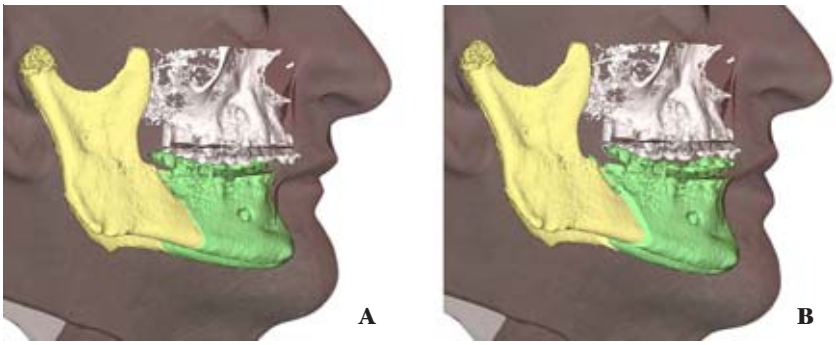

Figure 3A and B Simulation of soft tissue in a patient with class-II malocclusion. Preoperative situation **(A)**, planning of mandibular protrusion **(B)**.

After successful virtual displacement of the jaws the operation splints are created digitally and 3D-printed and after the osteotomy, the new jaw positions can be defined using teeth impressions (Fig. 2, 3 and 4). During planning, the jaw movements can be positioned in the 1/100 mm-range, which can lead to successful treatment of complex cases, such as vertical height correction [15]. The benefits of computer-based operation planning regarding the quality of results include the consideration of the individual temporomandibular joint axis and the expected change of the soft tissue. The planning time period can be shortened in computer-based operation planning compared to analog planning. For the planning of a sole mandibular displacement, the planning time period of 195 minutes can be reduced by 41 % and when displacing both jaws, the planning time period of 385 minutes can be reduced by 62 % [31].

Shortening of the planning period described in literature compared to analog operation planning is questionable when considering the additional survey of fundamental dysgnathia parameters and creating splints in 3D print. In the alternative definition of the necessary movements and submission of implementation to a service provider or software program, the planning know-

how and understanding of specific surgical circumstances would be lost. A shortened planning period would therefore reduce the practitioners influence and produce additional costs. Other disadvantages of computer-based operation planning are high investment costs and the necessary staff training in the new workflow.

Prediction of soft tissue changes

Displacement of the jaws also causes displacement of the soft tissue. While the displacement of the jaws can be planned and implemented precisely, the resulting displacement of the soft tissue is more difficult to predict. The reason for this is that the soft tissues do not follow the displacement in a 1:1 ratio but rather in a different ratio depending on their anatomic region. Even with the knowledge of these specific displacement factors, the individual patients' reaction complicates a prediction and does not allow a precise statement concerning displacement of soft tissues. Because soft tissues play an important role in the aesthetic and functional result, it is rewarding to consider the most optimal estimated displacement during planning and evaluating. The mean values of displacement factors were determined for anatomic regions in many studies. Lateral x-rays and photographs were used as underlying two-dimensional data, whereas new studies are mostly based on three-dimensional data from CT, DVT and face scans. Displacement factors were described as follows, whereas a displacement factor smaller than 1 means a smaller displacement than the according bone reference point: 0.78 in the upper lip region, 0.77 in the lower lip region, 0.74 on the tip of the nose 0.70 at the base of the nose and 0.73 on the cheeks [23] as well as 0.94 on the chin [6].

Due to the postoperative swelling, an assessment of the actual soft tissue displacement is advisable after a few weeks. An investigation of prediction accuracy of 3 planning programs showed a mean error of 1.8 mm +/- 0.8 mm for 3D (Dolphin Imaging & Management Solutions, Chatsworth, CA, USA), 1.2 mm +/- 0.4 mm für ProPlan CMF (Dentsply-Sirona, York, PA, USA) and 1.3 mm +/- 0.4 mm for the prediction based on a Finite-Elemente-Simulation [18]. However, the measurement of the soft tissues already has a rather high error, which is why a mean error of up +/- 2 mm is needed to collect 90 % of the measurement points in a face scan [17].

Individualized osteosynthesis material

New manufacturing technologies have made it possible to create patient-specific osteosynthesis material and osteotomy templates. The basis for this is computer-based operation planning. Osteosynthesis material can therefore be directly created based on the virtual shaping via laser sintering. A less complex alternative is to print synthetic 3D models of the bone using the virtual situation and to individualize ready-made osteosynthesis materials by bending it into the correct position. With computer-based operation planning, osteotomy templates from synthetic materials can be 3D-printed and used to implement osteotomies. These osteotomy templates can additionally help keep the safety distance to the dental roots or nerves. Using patient-specific osteosynthesis materials and osteotomy templates is supposed to make exact implementation of planned jaw displacement possible. This is an advantage in the vertical dimension, because the implementation of pure splint-based methods is surgically demanding. In combination with fitting laser sintering osteosynthesis materials, the screw holes of the osteotomy templates can be used after the osteotomy for osteosynthesis material. Thus, the position is transferred accurately and an operation splint is not absolutely essential [39]. However, templates and individually manufactured osteosynthesis materials, especially when sintered when splintered, are inapplicable with minimally-invasive surgical access because of the larger measurements. Another possibility for surgery without splints is using intraoperative navigation [4]. There are optical and electromagnetic systems available that are not widely applied due to high equipment costs despite good results. The disadvantage of an operation without splints is that the occlusion is unstable right after the displacement, because the orthodontic follow-up treatment still has to take place. Therefore, a splint is useful in many cases to ensure postoperative results during the healing phase, eve n when it is not essential for intraoperative positioning.

A significant disadvantage of patient-specific osteosynthesis material and osteotomy templates is the increased planning effort. Specifically, the laser sintering of patient-specific osteosynthesis material for orthognathic surgery may be the equivalent of the entire case compensation and has not yet established itself as a standard process. With further developments of manufacturing technologies and more frequent implementation, cost reduction and a wider application of these innovative processes is anticipated in the future.

Resorbable osteosynthesis material

Back in 1932 an absorbable osteosynthesis material with pure magnesium was available, which did not stand the test of time due to its biochemical instability. Absorbable osteosynthesis material took a back seat, because the introduction of stainless steel in the 1940s and titanium in the 1950s has been successful until today [34]. However, persisting osteosynthesis material can lead to foreign body sensation, bacterial colonization and growth limitation. Titanium causes artefacts in x-ray or MRI imaging, which complicates diagnosis. Even with new accidents or other necessary surgeries, persisting osteosynthesis materials can be a source of complications. The osteosynthesis material is often removed after bone healing is completed, however, this second procedure also comes with all the risks of surgery and is more complicated due to the existing scars. The biochemical industry has developed absorbable polymers since the 1960s and absorbable osteosynthesis material since the 1990s, among other things based on lactic acid, glycolic acid and polydioxanone. Depending on the composition, the degradation period takes weeks to years, whereas the

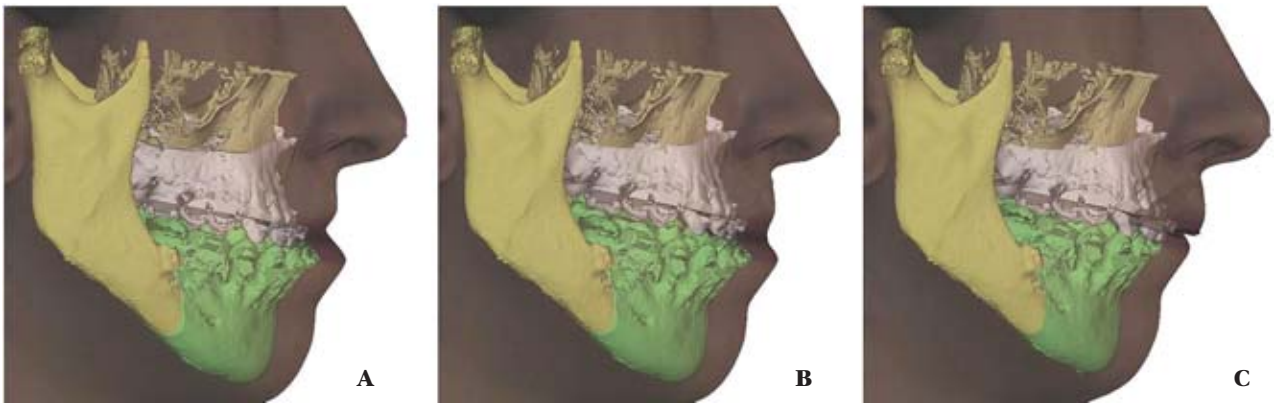

(Fig. 1–4: P. Winterhalder)

Figure 4A–C Simulation of soft tissue in a patient with class-III malocclusion. Preoperative Situation **(A)**, planning of maxillary protrusion **(B)** and the subsequent mandibular retrusion **(C)**.

degradation is mostly based on hydrolysis of ester bonds [34]. In order to partially compensate reduced stability when compared to titanium, absorbable osteosynthesis material is designed larger and requires more invasive surgical access. In clinical studies, the osteosynthesis material made out of resorbable polymer in orthognathic surgeries in the maxilla or mandible is sufficiently stable and causes similar complication rates like osteosynthesis material made out of titanium [1, 16, 32].

Resorbable osteosynthesis made out of polymers has the additional special feature that it is not radiopaque. This offers the benefit that no artefacts are created in imaging, however, it also prevents position and integrity control. Another option are new magnesium alloys with zirconium and strontium, which are significantly more stable compared to polymers, but need to be improved concerning biocompatibility [34].

Surgery first

When developing dysgnathia, the position of the teeth usually changes to compensate the underlying skeletal cause. For example, in mandibular retrognathia the incisors are often severely protruded. In such a compensated situation a normalization of the skeletal base by jaw displacement would cause a malocclusion. Therefore, in the conventional treatment concept the tooth positions are normalized with regard to the alveolar ridge and the dental arch. This causes the dysgnathia-based malocclusion to become fully visible. The dental arches that now match each other are optimally aligned when planning the surgery and relocated accordingly during the operation.

In contrast to this, a treatment concept called surgery first has been used since 2009, where no or minimal orthodontic treatment occurres before the orthognathic surgery [7]. The best and definite occlusion is aspired after surgery, with orthodontic treatment. The procedure was made possible with advances in orthodontic treatment, often using skeletal anchoring elements such as mini screws. Benefits of the surgery-first concept include shortening the treatment period by several months as well as reduced strain on the patient by skipping the pretreatment phase [36]. The surgery-first concept is used in class-II and class-III dysgnathia patients for displacement of one or both jaws. The treatment planning is demanding and often involves computer-supported operation planning. There is no consensus of indications of the surgery-first concept. Patients with mandibular prognathism, less teeth crowding and little dental compensation are particularly suitable [7, 22]. Patients with a mandibular retrognathia, deep bite, narrow palate or pronounced axis deviation of the front teeth seem unsuitable for the surgery-first concept [7, 22]. Treatment using the surgery-first concept should be critically questioned with increasing asymmetry of the patient case [11], even though successful treatments of pronounced asymmetry have also been described [42]. The treatment procedures of the surgery-first concept are continually being developed, which can lead to extended indications. For example, the treatment of protrusion of lower incisors as a surgery-first concept was described as a piezosurgical subapical osteotomy [12]. In order to facilitate the extensive, postoperative orthodontic treatment in a surgery-first concept, intraoperative skeletal anchoring elements such as mini-plates or mini-screws were inserted if needed. Postoperative, combined with increased bone remodeling [36], tooth movements can occur within a few months. Orthodontists and surgeons must individually discuss every patient to decide if the surgery-first concept depicts a promising therapy option. Even though all dislocations in digital operation planning are done very precisely, the spatial positioning of the segments provides a challenge for the user. Besides surgical aspects, orthodontic expertise is indispensable to determine positions of the jaws and to assess the postoperative orthodontic movements. Based on the absent preoperative decompensation the postoperative occlusion is only minimally supported in the surgery-first concept. Unfavorable occlusion contacts can even lead to postoperative mandibular malpositions [7]. Postoperative stabilizing with an operation splint is therefore recommended especially during multiple segmentations of the maxilla. The splint can be strengthened additionally for intraoperative application

with an incorporated transpalatal bow.

Piezosurgical osteotomies

The basis of piezosurgery is the observation by the brothers Pierre and Jaques Curie in 1880, that a crystal converts electrical energy into micromovements, which is considered the piezoelectric effect (Greek, piezein, 'to push'). The clinical use has developed since the 1950s from isolated applications in dentoalveolar surgery to the modern piezosurgery gadgets used today, where the first one in Germany was approved in 2002 [40].

In piezosurgery, micro movements of the piezo crystal are transferred to the tissue with different serrated or grained top pieces. The vibrations amount to 60–210 µm with a frequency of 25–29 kHz [2]. Hereby, only hard tissue is removed and soft tissue such as nerves are spared. Piezosurgery can be used to displace the maxilla in the Le Fort-I level as well as the displacement of the mandible in sagittal segmental osteotomy. A significant reduction of operation time is possible by piezosurgical osteotomies [19], while in addition the saw cuts can be designed more delicately. A review with 799 patients showed no prolonged duration of the piezosurgical segmental osteotomy of the mandible [37]. The frequency of nerve impairment at least 6 months after the surgery with 4.7 % of the patients was significantly less compared to the 61.6 % when a saw was used. In another study, the impact of piezosurgery on the fracture pattern of sagittal segmental osteotomy was examined, whereby no difference to conventional osteotomy was found in comparison [27]. The selection of different osteotomy top pieces makes piezosurgery versatile, and a curved top piece was used to weaken the base of the lower jaw. However, similarly to conventional weakening, this showed a poorer fracture pattern.

Effects on upper airways

Repositioning of the jaws with the adjacent soft tissues inevitably affects the upper respiratory tract. A measurement of the upper airways and their transformations is possible using three-dimensional imaging with DVT or CT and has presented superior to measurements based on lateral radiographs [25]. In case of impaired nasal breathing the airway resistance in this region can be determined with rhinomanometry. A palate expansion causes an expansion of the main nasal cavity and a reduced airway resistance during nasal breathing [3].

A mandibular retrusion reduces the airways and bears the risk of respiratory problems in patients with pronounced class-III malocclusions. This is particularly true, when the tongue is large compared to the jaw. As an alternative to the sole mandibular retrusion in patients with class-III malocclusion, an additional maxillary protrusion should be considered. Even this approach causes changes in the airways, which was described in a study with 22 patients [24]. The volume of the nasopharynx changed from 5,4 cm³ preoperative to 5,2 cm³ postoperative. The volume of the oropharynx reduced from 17,8 cm³ to 11,9 cm³, and the hypopharynx from 7,2 cm³ to 4,6 cm³. Despite the significant changes no patient presented respiratory problems 6 months postoperative.

The effects of jaw corrections on the airways are not only of importance in orthognathic patients. In obstructive sleep apnea syndrome reduced muscle tone causes blocked upper airways due to the weight of the soft tissues. The patient wakes up repeatedly because of respiratory distress, often without even realizing. Although there are usually only a few symptoms besides fatigue, it can lead to serious health issues such as arterial hypertension, heart disease or diabetes mellitus. In therapy-resistant obstructive sleep apnea the protrusion of both jaws is an important treatment option [26]. In order to displace the mandibular soft tissues even more anteriorly, an additional genioplasty is often performed.

Conflicts of interest

The authors declares that there is no conflict of interest within the meaning of the guidelines of the International Committee of Medical Journal Editors.

Literatur

1. Agnihotry A, Fedorowicz Z, Nasser M, Gill KS: Resorbable versus titanium plates for orthognathic surgery. Cochrane Database Syst Rev 2017; 10: CD006204

2. Aly LAA: Piezoelectric surgery: Applications in oral and maxillofacial surgery. Future Dental Journal 2018; 4: 105–111

3. Baratieri C, Alves M, Souza MMG de, Souza Araújo MT de, Maia LC: Does rapid maxillary expansion have long-term effects on airway dimensions and breathing? Am J Orthod Dentofacial Orthop 2011; 140: 146–156

4. Berger M, Kallus S, Nova I et al.: Approach to intraoperative electromagnetic navigation in orthognathic surgery: A phantom skull based trial. J Craniomaxillofac Surg 2015; 43: 1731–1736

5. Blair VP: Operations on the jaw-bone and face. Surg Gynecol Obstet 1907; 4: 67–78

6. Chang Y-J, Ruellas ACO, Yatabe MS, Westgate PM, Cevidanes LHS, Huja SS: Soft tissue changes measured with three-dimensional software provides new insights for surgical predictions. J Oral Maxillofac Surg 2017; 75: 2191–2201

7. Choi D-S, Garagiola U, Kim S-G: Current status of the surgery-first approach (part I): concepts and orthodontic protocols. Maxillofac Plast Reconstr Surg 2019; 41: 10

8. Creekmore TD, Eklund MK: The possibility of skeletal anchorage. J Clin Orthod 1983; 17: 266–269

9. Dal Pont G: L'osteotomia retromolare per la correzione della progenia. Minerva Chir 1, 1958

10. Hasund A: Klinische Kephalometrie für die Bergen-Technik. Universität in Bergen, Kieferorthopädische Abteilung des zahnärztlichen Institutes 1974

11. Hernández-Alfaro F, Guijarro-Martínez R, Peiró-Guijarro MA: Surgery first in orthognathic surgery: what have we learned? A comprehensive workflow based on 45 consecutive cases. J Oral Maxillofac Surg 2014; 72: 376–390

12. Hernández-Alfaro F, Nieto MJ, Ruiz-Magaz V, Valls-Ontañón A, Méndez-Manjón I, Guijarro-Martínez R: Inferior subapical osteotomy for dentoalveolar decompensation of class III malocclusion in ‚surgery-first' and ‚surgery-early' orthognathic treatment. Int J Oral Maxillofac Surg 2017; 46: 80–85

13. Hullihen SP: Case of elongation of the under jaw and distortion of the face and neck, caused by a burn, successfully treated. Am J Dent Sci 1849; 9: 157–165

14. Hunsuck EE: A modified intraoral sagittal splitting technic for correction of

mandibular prognathism. J Oral Surg 1968; 26: 250–253

15. Jaisinghani S, Adams NS, Mann RJ, Polley JW, Girotto JA: Virtual surgical planning in orthognathic surgery. Eplasty 2017; 17:ic1. eCollection 2017

16. Kanno T, Sukegawa S, Furuki Y, Nariai Y, Sekine J: Overview of innovative advances in bioresorbable plate systems for oral and maxillofacial surgery. Jpn Dent Sci Rev 2018; 54: 127–138

17. Knoops PGM, Beaumont CAA, Borghi A et al.: Comparison of three-dimensional scanner systems for craniomaxillofacial imaging. J Plast Reconstr Aesthet Surg 2017; 70: 441–449

18. Knoops PGM, Borghi A, Breakey RWF et al.: Three-dimensional soft tissue prediction in orthognathic surgery: a clinical comparison of Dolphin, ProPlan CMF, and probabilistic finite element modelling. Int J Oral Maxillofac Surg 2019; 48: 511–518

19. Koba A, Tanoue R, Kikuta S, Hirashima S, Miyazono Y, Kusukawa J: The usefulness of piezoelectric surgery in sagittal split ramus osteotomy. Kurume Med J 2018; 64: 57–63

20. Köle H: Surgical operations on the alveolar ridge to correct occlusal abnormalities. Oral Surg Oral Med Oral Path 1959; 12: 277–288

21. Köle H: Die chirurgische Behandlung von Formveränderungen des Kinns. Wien, Med Wschr 1968; 118: 331–334

22. Kwon T-G, Han MD: Current status of surgery first approach (part II): precautions and complications. Maxillofac Plast Reconstr Surg 2019; 41: 23

23. Lai H-C, Denadai R, Ho C-T, Lin H-H, Lo L-J: Effect of Le Fort I maxillary advancement and clockwise rotation on the anteromedial cheek soft tissue change in patients with skeletal class III pattern and midface deficiency: a 3D imaging-based prediction study. J Clin Med 2020; Jan; 9(1): 262; doi: 10.3390/jcm9010262

24. Lee W-Y, Park Y-W, Kwon K-J, Kim S-G: Change of the airway space in mandibular prognathism after bimaxillary surgery involving maxillary posterior impaction. Maxillofac Plast Reconstr Surg 2016; 38: 23

25. Lenza MG, Lenza MMdO, Dalstra M, Melsen B, Cattaneo PM: An analysis of different approaches to the assessment of upper airway morphology: a CBCT study. Orthod Craniofac Res 2010; 13: 96–105

26. Liu SY-C, Awad M, Riley RW: Maxillomandibular advancement: contemporary approach at stanford. Atlas Oral Maxillofac Surg Clin North Am 2019; 27: 29–36

27. Möhlhenrich SC, Ayoub N, Peters F et al.: Evaluation of the lingual fracture patterns after bilateral sagittal split osteotomy according to Hunsuck/Epker modified by an additional inferior border osteotomy using a burr or ultrasonic device. Int J Oral Maxillofac Surg 2019; 48: 620–628

28. Obwegeser HL: Surgical correction of small or retrodisplaced maxillae. The „dish-face“ deformity. Plast Reconstr Surg 1969; 43: 351–365

29. Obwegeser HL: Die einzeitige Vorbewegung des Oberkiefers und Rückbewegung des Unterkiefers zur Korrektur der extremen Progenie. Schweiz Mschr Zahnheilk 1970; 80: 347–356

30. Obwegeser HL, Trauner R: Zur Operationstechnik bei der Progenie und anderen Unterkieferanomalien. Dtsch Zahn Mund Kieferheilkd 1955; 23: 11–26

31. Park S-Y, Hwang D-S, Song J-M, Kim U-K: Comparison of time and cost between conventional surgical planning and virtual surgical planning in orthognathic surgery in Korea. Maxillofac Plast Reconstr Surg 2019; 41: 35

32. Park Y-W: Bioabsorbable osteofixation for orthognathic surgery. Maxillofac Plast Reconstr Surg 2015; 37: 6

33. Schuchardt K: Formen des offenen Bisses und ihre operativen Behandlungsmöglichkeiten. In: Schuchardt K, Wassmund M (Hrsg): Fortschritte der Kiefer- und Gesichts-Chirurgie, Bd. I., Thieme, Stuttgart 1955, S. 222

34. Schumann P, Lindhorst D, Wagner MEH, Schramm A, Gellrich N-C, Rücker M: Perspectives on resorbable osteosynthesis materials in craniomaxillofacial surgery. Pathobiology 2013; 80: 211–217

35. Segner D, Hasund A: Individualisierte Kephalometrie. Segner 1991

36. Sharma VK, Yadav K, Tandon P: An overview of surgery-first approach: recent advances in orthognathic surgery. J Orthod Sci 2015; 4: 9–12

37. Silva LF, Carvalho-Reis ENR, Bonardi JP et al.: Comparison between piezoelectric surgery and conventional saw in sagittal split osteotomies: a systematic review. Int J Oral Maxillofac Surg 2017; 46: 1000–1006

38. Steinhäuser EW: Historical development of orthognathic surgery. J Craniomaxillofacial Surg 1996; 24: 195–204

39. Suojanen J, Leikola J, Stoor P: The use of patient-specific implants in orthognathic surgery: a series of 32 maxillary osteotomy patients. J Craniomaxillofac Surg 2016; 44: 1913–1916

40. Thomas M, Akula U, Ealla KKR, Gajjada N: Piezosurgery: a boon for modern periodontics. J Int Soc Prev Community Dent 2017; 7: 1–7

41. Trauner R: Zur Progenieoperation. Ost Z Stomat 1955; 52: 361

42. Villegas C, Uribe F, Sugawara J, Nanda R: Expedited correction of significant dentofacial asymmetry using a „surgery first“ approach. J Clin Orthod 2010; 44: 97–103; quiz 105

43. Waßmund M: Lehrbuch der praktischen Chirurgie des Mundes und der Kiefer, Bd. 1., H. Meußer, Leipzig 1935

44. Winterhalder P, Ayoub N, Modabber A, Hölzle F: Dysgnathiechirurgie im digitalen Workflow. teamwork 2020; 01: 34–39

(Photo: Philipp Winterhalder)

DR. DR. PHILIPP WINTERHALDER
Clinic of Oral and Maxillofacial Surgery of the University Hospital of the RWTH Aachen
Pauwelstr. 30
52074 Aachen, Germany
pwinterhalde@ukaachen.de

Katrin Hertrampf, Martin Kunkel

S2k guideline "Diagnostics and management of precursor lesions of oral squamous cell carcinoma in dental and oral medicine"

Overview: The update of the guideline on "diagnostics and management of precursor lesions of oral squamous cell carcinoma in dental and oral medicine" began in 2017 and was finalized in April 2020 after a total of 3 formal consensus processes. It was coordinated by the German Society of Dental and Oral Medicine (DGZMK) and the German Society for Oral and Maxillofacial Surgery. Specifically, the guideline updates the knowledge and recommendations, particularly the following aspects:
– the classification of potentially malignant oral lesions considering the updated WHO classification of 2017
– special status of proliferative verrucous leukoplakia
– definition of "suspicious" lesions under observation of clinical evidence of a malignant transformation
– specific designation of examinations, whose significance is not supported with reliable study data
– topical corticoid therapy of lichen, especially intralesional therapies
Furthermore, the existing recommendations were updated and complemented by statements and new recommendations.

Keywords: precursor lesion; dental and oral medicine; malignant transformation; early detection; screening; oral mucosa; WHO classification

Clinic for Oral and Maxillofacial Surgery, University Hospital Schleswig-Holstein, Campus Kiel, Germany: Prof. Dr. Katrin Hertrampf
Clinic for Oral and Maxillofacial Surgery, University Hospital Knappschaftskrankenhaus Bochum, Germany: Prof. Dr. Dr. Martin Kunkel
Translation from German: Yasmin Schmidt-Park
Citation: Hertrampf K, Kunkel M: S2k guideline "Diagnostics and management of precursor lesions of oral squamous cell carcinoma in dental and oral medicine". Dtsch Zahnärztl Z Int 2020; 2: 188–195
DOI.org/10.3238/dzz-int.2020.0188–0195

WHO 2017: Dysplasia	WHO 2005: Dysplasia	Ljubljana classification squamous intraepithelial lesions (SIL)	Squamous intraepithelial neoplasia (SIN)	Reduced squamous intraepithelial neoplasia (SIN)
–	squamous hyperplasia	(simple) squamous hyperplasia	–	
low grade dysplasia	low grade dysplasia	basal and parabasal hyperplasia	SIN I	SIN: low risk
moderate dysplasia	moderate dysplasia	atypical hyperplasia (risk epithelium)	SIN II	SIN: high risk
high grade dysplasia	high grade dysplasia		SIN III	
carcinoma in situ	carcinoma in situ	carcinoma in situ		
invasive carcinoma	invasive carcinoma			

*Since both moderate dysplasia and high grade dysplasia are considered "high risk" lesions, the graduation can be modified to a binary structure "low grade" and "high grade" (with "high grade" including moderate and high grade dysplasia)

Overview 1 Synopsis of classifications of potentially malignant oral lesions [6, 7, 10, 25]

Introduction

It's the guidelines' aim to record the current state of knowledge for a relevant problem in health care and if possible, draft key statements in the form of clear recommendations for action. For this, regular updates are necessary in order to keep up with the development of scientific knowledge. Having said this, the update of the guideline "diagnostics and management of precursor lesions of oral squamous cell carcinoma in dental and oral medicine" was started in 2017 and finalized in April 2020. It was carried out by the German Society for Dental and Oral Medicine (DGZMK) and the German Society for Oral and Maxillofacial Surgery. The update of the guideline was added to the list of prioritized topics of the task force of DGZMK, BZÄK and KZBV, which consisted of representatives of DGZMK, KZBV and BZÄK.

The authors of the guideline conducted current literature research (Medline) until 2018 to draft the recommendations and background text and included the relevant literature in the guidelines. Based on the existing guidelines, the coordinators revised the document in the first step and added current literature. Simultaneously, certain wordings were clarified that had led to misunderstandings in the past, and a formal division between recommendations and statements was included. The referencing of other guidelines was also updated.

This draft was the basis of a formal Delphi method with two Delphi rounds and a conclusive consensus conference with the participation of elected representatives of professional societies on 23.01.2019 in Cologne (see Tab. 1) under methodical moderation of AWMF. Within this consensus conference, the key statements and additions in the context of literature were discussed and a formal and structured consent added to the methodology of a nominal group process. Because this is an S2k guideline, a more detailed evaluation of studies in the sense of an evidence grading or even weighting and synthesis of study results did not take place.

Updated precisely, the guideline specifies the current knowledge and recommendations, particularly the following aspects:

- classifications of potentially malignant oral lesions regarding the updates WHO classifications of 2017
- special status of proliferative verrucous leukoplakia
- definition of "suspicious" lesions under observation of clinical evidence of a malignant transformation
- specific designation of examinations, whose significance is not supported with reliable study data
- topical corticoid therapy of lichen ruber mucosa, especially intralesional therapy
- recommendations

The state of research and the decision criteria of recommendations were renewed in form of background texts as in the previous version, which were included in the extended version of the guideline. Since these texts create references to relevant literature, they are displayed here for information.

Classifications of potentially malignant oral lesions in consideration of the upgraded WHO classification of 2017

In the current WHO classification of head and neck tumors 2017 [7], mostly classification of dysplasia degrees are used. However, the term squamous intraepithelial neoplasia (abbreviated: SIN) will continue to be used as a synonym of potentially malignant lesions (previously: oral precursor lesions) of squamous cell carcinoma. The potentially neoplastic character of the lesion is depicted in

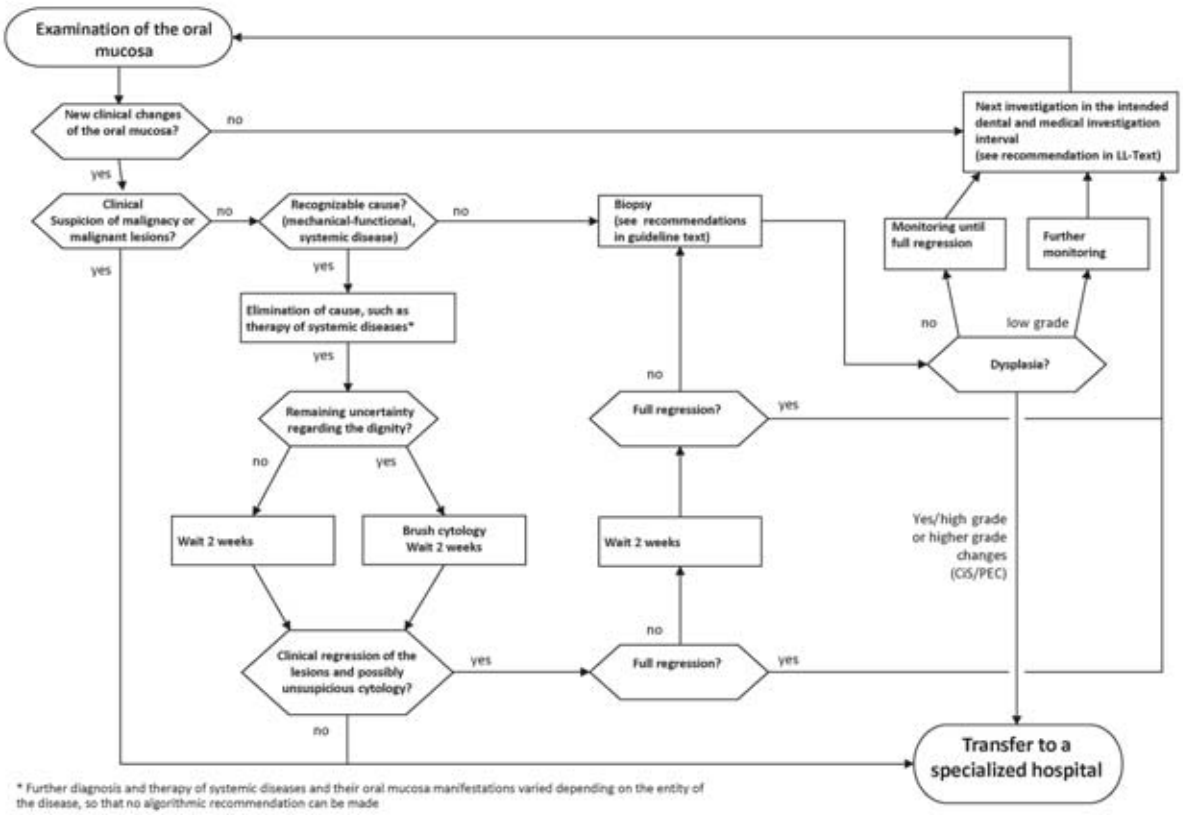

(Overview 1, Fig. 1 and Tab. 1: K. Hertrampf, M. Kunkel)

Figure 1 Algorithm for the guideline "diagnostics and management of precursor lesions of oral squamous cell carcinoma in dental and oral medicine"

the nomenclature. In the following, the term of potentially malignant oral lesions classification (2017) instead of precursor lesions and other terms is used according to WHO (precancerous condition, precancerous lesion, potentially malignant lesion, precursor lesion etc.).

Compared to earlier versions of the WHO classification, a reduction of degrees of dysplasia is introduced in the form of a binary classification. Ultimately, the three traditional degrees of dysplasia are reduced to a "low grade" group and a "high grade" group, which essentially corresponds to the clinical risk assessment and signals a distribution into "low risk" SIN and "high risk" SIN. In earlier nomenclature, high grade intraepithelial neoplasia (SIN 3) included the carcinoma in situ of earlier classifications (carcinoma risk of 90 %) [3, 5, 15, 27], (see overview 1).

Special status of proliferative verrucous leukoplakia

The proliferative verrucous leukoplakia (PVL) has a special status, because the morphological degree of dysplasia does not correlate with the clinical risk potential. Even though low degrees of dysplasia are typically found in PVL or can be missing completely, a highly malignant transformation rate (about 70 %) and consecutively high tumor-related mortality is expected with this entity.

Definition of "suspicious" lesions while describing clinical features of a malignant transformation

The recommendations for action are based on the fact that oral lesions that are evaluated as "suspicious" for malignant transformation. Apart from the chronological development (persistence of a lesion for more than 2 weeks) the following clinical criteria should be regarded as indicators suggestive of a malignant transformation, specifically:

- newly occurred and of unknown duration
- thick hyperkeratosis
- inhomogeneity
- erosion
- bleeding on contact or light mechanical stress
- missing cause
- pathological vascular dilation/ vessels

The algorithm for complete examination of the oral mucosa was updated (Fig. 1).

Examinations, whose significance is not supported with reliable study data:

The description of research methodology was upgraded and newly structured. Specifically, a group of examinations is designated whose significance is not supported with reliable study data.

Professional societies involved/ Organizations	Abbreviation	Elected representatives
Working Group for Oral and Maxillofacial Surgery	AGOKI	Prof. Dr. A. M. Schmidt-Westhausen
Working Group Oral Pathology and Oral Medicine	AKOPOM	Prof. Dr. Dr. U. Müller-Richter
Federal Association of German Oral Surgeons	BDO	Prof. Dr. J. Jackowski Prof. Dr. T.M. Remmerbach
Federal Association of Dentists	BZÄK	Dr. J. Beck
Professional Association of German Pathologists	BDP	§)
German Dermatological Society	DDG	Prof. Dr. F. Kiesewetter
German Society for Otorhinolaryngology, Head and Neck Surgery	DGHNO-KHC	Prof. Dr. J.P. Klußmann Prof. Dr. C. Wittekindt (deputy)
German Society of Implantology	DGI	Prof. Dr. F. Schwarz
German Society for oral and maxillofacial surgery	DGMKG	Prof. Dr. K. Hertrampf (coordination) Prof. Dr. Dr. M. Kunkel (mandate)
German Society of Peirodontology	DGPARO	PD Dr. C. Graetz
German Society of Pathology	DGP	§)
German Society for Dental Prosthetics and Materials Science	DGPro	Prof. Dr. H.-J. Wenz, MME
German Cancer Society (working group ENT and OMF-surgery in oncology)	DKG	Prof. Dr. J.P. Klußmann
National Association of Statutory Health Insurance Dentists	KZBV	Dr. J. Beck

§) The elected representative of the German Society of Pathology (DGP) and the Professional Association of German Pathologists (BDP) left the guideline group during the creation process. Both specialist groups were given the opportunity to comment on the finalized draft guideline and both approved.

Table 1 Listing of the professional societies involved/organizations and the elected representatives

Necessary examinations for therapy decisions:

- inspection: using a systematic examination procedure it is ensured that all relevant regions of the oral mucosa can be investigated and critically assessed
- palpation

Further investigations:

- review of causes of mechanical irritation
- sensitivity test of neighboring teeth to record odontogenic inflammatory causes
- determining periodontal parameters to record periodontal causes
- x-ray examination to record dental and osseous inflammatory causes
- examination of lymph node status to evaluate accompanying inflammatory reactions or to recognize the spread of the tumor
- sensitivity test (lingual nerve and mental nerve) to evaluate sensation of pain or to recognize the spread of the tumor

Helpful examinations in justified individual cases:

- swab for microbiological diagnostics
- virological diagnostics
- reviewing a reaction to dental materials

Examinations, whose significance is not supported with reliable study data:

- intravital staining with toluidine blue[a]
- visual tools
  - chemiluminescence and autofluorescence diagnostics[b]
  - narrow band imaging[c]

The background texts were updated to help explain.

a) Intravital staining with toluidine blue

Methods of intravital staining of the oral mucosa for specific emphasis of malignant lesions on basis of tolui-

dine blue have been described for more than 40 years. The basic principle postulated is the increased binding of the dye with DNA-affinity in tissues with higher cell conversion [19]. On a molecular level the association between chromosomal changes (e.g. 3p/9p LOH) and staining behavior of oral mucosa changes were shown [30].

The accuracy in clinical investigations is variable, there are values of 38–98 % for sensitivity and a range of 9–93 % for specificity [4, 19, 20]. Despite the long-term availability and a large number of literature notifications, only a few studies address the application of toluidine blue in order to detect oral mucosa lesions that have not already been previously recognized clinically [12]. In addition, more authors are critical of the low accuracy for potentially malignant oral lesions with a sensitivity of under 50 % [9, 16, 18].

Overall, the big effort involved with chairside application has prevented the clinical implementation of staining and the expansion of the methods and usage in dental practices. In literature, there is no data on the application in primary care. After more than five decades, a relevant development and expansion of the method is not to be expected.

b) Chemiluminescence and autofluorescence diagnostics

In the last few years, the procedures for chemiluminescence and autofluorescence diagnostics were examined as supportive visual tools in detecting potentially malignant oral lesions and oral carcinomas in different studies. In the process of the chemiluminescence source of light, the oral mucosa is pretreated with 1 % acetic acid. Possible modifications in the keratinization are supposed to show up in white and then stand out after subsequent treatment with toluidine blue. In autofluorescence diagnostics, dysplastic or neoplastic lesions are supposed to show up darker compared to healthy (green) oral mucosa, due to the loss of fluorescence. Koch et al. (2010) were able to show a high sensitivity of 93 % in a patient collective (N = 78) with conspicuous clinical mucosa lesions in the examination using autofluorescence diagnosis, however, the specificity was only at 13–17 % [11]. In the study of Mehrota et al. (2010) both visual methods came into effect and showed significantly worse results [17]. The procedure with autofluorescence showed a sensitivity of 50 % and a specificity of 38.9 % in 156 examined lesions. When applying chemiluminescence in 102 examined lesions, the sensitivity was at 0 and the specificity at 75.5 %. Further studies that investigated these procedures showed similar critical, unsatisfactory results [1, 2, 8, 21, 22]. The inhomogeneous and inadequate data shows no scientific basis for the application of either visual procedure in early detection of potential malignant oral lesions and oral carcinomas.

c) Narrow band imaging

Another visual method that was evaluated in studies for early detection of oral carcinomas and potentially malignant oral lesions in the last few years is the narrow band imaging from other areas of surface diagnostics in the oral cavity in studies. The method used two narrow-banded frequency domains (400–430 nm and 525–555 nm) in order to depict differences in vessel plexus instead of continuous frequency spectrum of white light. Yang et al. (2012 and 2013) showed a sensitivity of 96.3 % for the narrow band imaging using a patient collective of n = 317 and a specifity of 60.1 % compared to white light with 87 % sensitivity and 93.5 % specificity. However, the transferability of the results and a potential recommendation is only possible to a limited extent, because in studies from Asian countries, many lesions are buccal lesions, caused by the enjoyment of betel products and therefore many localisations for lesions were underrepresented [28, 29]. A systematic review from 2014 [26] came to the conclusion that this method has diagnostic potential, however, a statement for recommendation in the field of early detection is not possible due to the insufficient and inadequate data.

Topical corticoid therapy of mucosal lichen ruber, particularly intralesional therapy

Also the background text on measures of demarcation of inflammatory/irritating phenomenons was extended and specifically, the intralesional therapy with corticoid was included.

Local corticoid therapy

For a symptomatic lichen ruber the local treatment using steroids is the therapy of choice [13]. There is not enough evidence for a recommendation of a specific steroid therapy regarding the outcome of "pain reduction" [24]. This was also confirmed by the study of Liu et al. (2013) [14]. They could, however, determine a positive therapy effect of an intralesional therapy with betamethasone compared to therapy with triamcinolone in their randomized, controlled study regarding the outcome "recurrence of a lesion within three months".

Unresponsiveness to steroid application confirms the indication of a biopsy [23].

Recommendations

Since the key statements of the guideline are formulated in the recommendations, all recommendations of the guideline are written out in the following. An explanation of modifications was included when significant changes have been made to the previous version.

Recommendation 1:	
Within the recommended systematic examination of the oral cavity every 6 months it should be ensured that all regions of the oral mucosa, the lips and the neighboring tissues are critically investigated. When changes are observed, further diagnostics should take place.	**strong consensus**

Expert consensus

Recommendation 2:	
When the cause of mucosal changes is assumed, e.g. a mechanical irritation of inflammatory systemic disease, the cause should be eliminated first, and if necessary this includes treating the systemic disease	**strong consensus**

Expert consensus

Recommendation 3:	
In case of suspecting a manifested carcinoma, the patient should be refered immediately to introduce further diagnostics and therapy	**strong consensus**

Expert consensus

Recommendation 4:	
When suspecting a malignant transformation of the mucous membrane, a histological clarification should take place	**strong consensus**

Expert consensus

Recommendation 5:	
For a cytological diagnosis, the harvesting procedure should be done using brushes, because they can collect superficial as well as deeper cell layers	**strong consensus**

Expert consensus

Statement 1:	
There is not enough evidence for a recommendation regarding application of further technology in cytology (immunohistology, DNA cytometry etc.) in early recognition of oral precursor lesions.	**strong consensus**

Expert consensus

Recommendation 6:	
If a biopsy might not be representative of the whole lesion, a complete diagnostic excision should take place	**strong consensus**

Expert consensus

Recommendation 7:	
If a mucosal lesion is considered non-malignant and there is no need for an biopsy, nonetheless monitoring is intended since some uncertainty remains regarding the dignity of oral mucosa lesions, a brush cytology should be used	**consensus**

Expert consensus

Recently incorporated recommendation

Recommendation 8:	
In extended oral mucosa lesions, where a diagnostic excision would lead to a highly perioperative morbidity, an extensive brush biopsy is an alternative to multiple simultaneous biopsies.	**strong consensus**

Expert consensus

For extensive oral mucosal lesions with chronic progression (for example with a proliferative verrucous leukoplakia) there is the problem that on one hand, representative localisations (e.g. most advanced in tumor progression) can sometimes not be defined, and on the other hand, a complete diagnostic excision especially in cross-regional lesions can imply the perioperative morbidity of a tumor resection or is not technically feasible in multifocal lesion. In these rare cases, the large surface coverage of the brush biopsy (reduction of "sampling errors") must be weighted against the greater diagnostic accuracy of the excision biopsy (limited to the excised tissue).

Recommendation 9:	
It is possible to refrain from incision or excision biopsy when a regression of the lesion is noticeable within two weeks after elimination of an adequate cause*. In this case, the clinical control should be continued until complete regression, because a partial regression of malignant lesions can be feigned by overlapping inflammatory components	**consensus**

Expert consensus

Recommendation 10:	
A histological clarification (biopsy) should take place**, if there is a beginning regression in the first two weeks, but not a complete healing after two more weeks	**strong consensus**

Expert consensus

/The timeframe of recommendations 9 and 10 apply to patients where normal wound healing can be expected.*

Recommendation 11:	
According to prevailing opinion, lesions that are clinically homogeneous, and evaluated as histologically "low grade" (previously SIN I or low dysplastic) can be primarily monitored.	**strong consensus**
Lesions that are histologically classified als "high grade" (previously SIN II or III, or moderately or highly dysplastic) should be excised completely.	**consensus**

Expert consensus

Recommendation 12:	
When there is a discrepancy between the clinical appearance and the histological evaluation (for example. inhomogeneous leukoplakia without histological dysplasia), another histological review or a transfer for a second opinion/introduction of further diagnostics and therapy should follow	**strong consensus**

Expert consensus

Recommendation 13:	
After removal or monitoring of low grade dysplastic lesions an inspection interval of 6 months should be followed. In all other manifestations of dysplastic lesions, a check-up interval of 3 months should be followed.	**consensus**
Specific recommendations exist for mucosal lichen ruber for the necessity of constant monitoring. The check-up interval should not exceed four months.	**consensus**

Expert consensus

Recommendation 14:	
A check-up should always be recommended to the patient, independent from the type of therapy.	**strong consensus**

Expert consensus

Recommendation 15:	
In general, an outpatient treatment under local anesthesia is sufficient. A treatment in general anesthesia/sedation can be indicated depending on localisation or due to expected problems in cooperation of the patient (e.g. gag reflex), in patients with large overall extent of mucogingival measures, in manifested local risk factors or after consideration of these criteria based on the preference of the patient. In-patient treatment can be indicated in severe systemic diseases or particular surgery developments.	**strong consensus**

Expert consensus

There is additional information available in the form of a more detailed guideline report. The documents can be downloaded from the websites of the AWMF, BZÄK and the DGZMK. The next update is planned for 2025.

Conflict of interest

The authors state that there is no conflict of interest within the guidelines of the International Committee of Medical Journal Editors.

References

1. Awan KH, Morgan PR, Warnakulasuriya S: Evaluation of an autofluorescence based imaging system (VELscopeTM) in the detection of oral potentially malignant disorders and benign keratoses. Oral Oncol 2011; 47: 274–277

2. Balevi B: Assessing the usefulness of three adjunctive diagnostic devices for oral cancer screening: a probabilistic approach. Community Dent Oral Epidemiol 2011; 39: 171–176

3. British Dental Association. Opportunistic oral cancer screening. BDA occasional paper. April 2000 (issue number 6). Available from url: http://www.bda-dentistry.org.uk/about/docs/mouth_cancer.pdf

4. Cancela-Rodriguez P, Cerero-Lapiedra R, Esparza-Gomez G, Llamas-Martinez S, Warnakulasuriya S: The use of toluidine blue in the detection of pre-malignant and malignant oral lesions. J Oral Pathol Med 2011; 40: 300–304

5. Department of Dental Services: Screening for oral cancer. Royal College of Surgeons of England, London 1994

6. Driemel O, Hertel K, Reichert TE, Kosmehl H: Aktuelle Klassifikation der Precursorläsionen des oralen Plattenepithelkarzinoms – Prinzipien der WHO-Klassifikation von 2005. Mund Kiefer Gesichtschir 2006; 10: 89–93

7. El-Naggar AK, Chan JKC, Grandis JR, Takata T, Slootweg PJ: WHO classification of head and neck tumours. IARC, 4 edition, Lyon 2017

8. Farah CS, McIntosh L, Georgiou A, McCullough MJ: Efficiacy of tissue autofluorescence imaging (VELscope) in the visualization of oral mucosal lesions. Head Neck 2012; 34: 856–862

9. Fedele S: Diagnostic aids in the screening of oral cancer. Head Neck Oncol 2009; 1: 5

10. Gale N, Pilch BZ, Sidransky D, Westra WH, Califano J: Epithelial precursor lesions. In: Barnes L, Eveson JW, Reichart P, Sidransky D (eds.): World Health Organization classification of tumors. Pathology and genetics of head and neck tumors. IACR, Lyon 2005, 140–143

11. Koch FP, Kaemmerer PW, Biesterfeld S, Kunkel M, Wagner W: Effectiveness of autofluorescence to identify suspicious oral lesions – a prospective, blinded clinical trial. Clin Oral Invest 2011; 15: 975–982

12. Lingen MW, Kalmar JR, Karrison T, Speight PM: Critical evaluation of diagnostic aids for the detection of oral Cancer. Oral Oncol 2008; 44: 10–22

13. Lodi G, Scully C, Carrozzo M, Griffiths M, Sugerman PB, Thongprasom K: Current controversies in oral lichen planus: report of an international consensus meeting. Part 2. Clinical management and malignant transformation. Oral Surg Oral Med Oral Pathol Oral Radiol Endod 2005; 100: 164–178

14. Liu C, Xie B, Yang Y et al.: Efficacy of intralesional betamethasone for erosive oral lichen planus and evaluation of recurrence: a randomized controlled trial. Oral Surg Oral Med Oral Pathol Oral Radiol 2013; 116: 584–590

15. Macfarlane GJ, Boyle P, Scully C: Oral cancer in Scotland: changing incidence and mortality. BMJ 1992; 305: 1121–1123

16. Martin IC, Kerawala CJ, Reed M: The application of toluidine blue as an adjunct in the detection of epithelial dysplasia. Oral Surg Oral Med Oral Pathol Oral Radiol Endod 1998; 85: 444–446

17. Mehrotra R, Singh M, Thomas S: A cross-sectional study evaluation chemilu-

menscence and autofluorescence in the detection of clinically innocuous precancerous and cancerous oral lesions. J Am Dent Assoc 2010; 142: 151–156

18. Onofre MA, Sposto MR, Navarro CM: Reliability of toluidine blue application in the detection of oral epithelial dysplasia and in situ invasive squamous cell carcinomas. Oral Surg Oral Med Oral Pathol Oral Radiol Endod 2001; 91: 535–540

19. Patton LL, Epstein JB, Kerr AR: Adjunctive techniques for oral cancer examination and lesion diagnosis: a systematic review of the literature. J Am Dent Assoc 2008; 139: 896–905

20. Rahman F, Tippu Shoaib R, Khandelwal S, Girish KL, Manjunath BC, Bhargava A: A study to evaluate the efficacy of toluidine blue and cytology in detecting of oral cancer and dysplastic lesions. Quintessence Int 2012; 43: 51–59

21. Scheer M, Neugebauer J, Dermann A, Fuss J, Drebber U, Zoeller JE: Autofluorescence imaging of potentially malignant mucosa lesions. Oral Surg Oral Med Oral Pathol Oral Radiol Endod 2011; 111: 568–577

22. Shin D NV, Gillenwater A, Richards-Kortum R: Advances in fluorescence imaging techniques to detect oral cancer and its precursors. Future Oncol 2010; 6: 1143–1154

23. Thongprasom K, Dhanuthai K: Steroids in the treatment of lichen planus: a review. J Oral Sci 2008; 50: 377–385

24. Thongprasom K, Carrozzo M, Furnes S, Lodi G: Interventions for treating oral lichen planus. Cochrane Database Rev 2011; Jul 6;(7): CD001168. doi: 10.1002/14651858.CD001168.pub2

25. Van der Waal I: Potentially malignant disorders of the oral and oropharyngeal mucosa: terminology, classification and present concepts of management. Oral Oncol 2009; 45: 317–323

26. Vu AN, Farah CS: Efficacy of narrow band imaging for detection and surveillance of potentially malignant and malignant lesions in the oral cavity and oropharynx: a systematic review. Oral Oncol 2014; 50: 413–420

27. Wolff K-D., Bootz F, Beck J et al: S3-Leitlinie „Mundhöhlenkarzinom, Diagnostik und Therapie". www.leitlinien.de

28. Yang S-W, Lee Y-S, Chang L-C, Hwang C-C, Chen T-A: Diagnostik significance of narrow-band imaging for detetcting high-grade dysplasia, carcinoma in situ, and carcinoma in oral leukoplakia. Laryngoscope 2012; 122: 2754–2761

29. Yang S-W, Lee Y-S, Chang L-C, Chien H-P, Chen T-A: Light sources used in evaluating oral leukoplakia: broadband white light versus narrowband imaging. J Oral Maxillofac Surg 2013; 42: 693–701

30. Zhang L, Williams M, Poh CF et al.: Toluidine blue staining identifies high-risk primary oral premalIgnant lesions with poor outcome. Cancer Res 2005; 65: 8017–8021

(Photo: Fotoatelier Ute Boeters, Kiel)

PROF. DR. KATRIN HERTRAMPF, MPH MME
Clinic for Oral and Maxillofacial Surgery
University Hospital Schleswig-Holstein, Campus Kiel
Arnold-Heller-Str. 3, Building B,
24105 Kiel, Germany
hertrampf@mkg.uni-kiel.de

(Photo: private, Martin Kunkel)

UNIV.-PROF. DR. DR. MARTIN KUNKEL
Clinic for Oral and Maxillofacial Surgery
University Hospital
Knappschaftskrankenhaus Bochum
In der Schornau 23–25
44892 Bochum, Germany
martin.kunkel@rub.de

Fabian Duttenhoefer, Marc Anton Fuessinger, Yasmin Beckmann, Rainer Schmelzeisen, Martin Boeker, Knut A. Groetz

S3-guideline "Dental implants in patients with immunodeficiency" – practice-oriented treatment recommendations

Dental implants are an integral part of modern dental, oral and maxillofacial medicine. Apart from rehabilitating the physiological masticatory function and increasing the quality of life, dental implants have a positive influence on the general health condition [31]. For successful treatment, a key prerequisite is the osseous healing of the inserted implants (osseointegration). This strongly depends on an adequately functioning immune system, as it is involved in regulating postoperative wound healing and it has an important modulating effect on the tendency of subsequent peri-implantitis development. In this respect, immunocompromised patients exhibit a particularly higher risk profile.

Given the current demographic development of higher life expectancy and continuously improving health care, it has become apparent that the number of patients displaying immunodeficiency, who wish to be treated with implant-supported restorations, is increasing. Furthermore, due to the ongoing improvement in long-term immunosuppressive therapies, a significant increase in this category of patients can be anticipated in the future [1, 13, 17].

Moreover, in deciding when dental implants are indicated in immunocompromised patients, it must be considered that the patient population is very heterogeneous with varying degrees of immune system impairment. For the dental practice, this means a high degree of uncertainty with respect to the indication for treatment, as well as the associated treatment sequence, which includes preparation, conducting the operative intervention and postoperative aftercare.

For a better overview, the classification of immunodeficiency can be grouped as follows:

1. Primary, congenital immunodeficiency*
2. Secondary, acquired immunodeficiency, e.g. HIV infection**
3. Secondary, drug-induced immunosuppression, e.g. steroids (cortisone)

Autoimmune diseases

Studies performed in the last 10 years corroborate that there is a steady increase in the frequency of autoimmune diseases [17]; at present, their prevalence in Europe and North America is presumed to be as high as 12.5 % [13, 17]. Accordingly, there is reason to suspect that the number of patients with autoimmune diseases, who wish for dental implants, will grow. The mechanisms which underlie the reduction of the body's immunological tolerance to one's own body molecules, and subsequently, to a lowered immune response and to different forms of autoimmune diseases, is not yet fully understood [28]. Socioeconomic, genetic and environmental factors as well as certain types of infections are discussed as being triggering factors for autoimmune reactions.

Autoimmune diseases occur more frequently in women. They represent the predominant group among patients suffering from autoimmune diseases (75 %) [13]. In a systematic review, the influence of autoimmune diseases and their therapy on the survival rates of dental implants was investigated. The outcome revealed a clear trend towards female patients who accounted for 98 % of the patient population. The frequent occurrence of different coexisting autoimmune diseases was also conspicuous; examples include the combination of rheumatoid arthritis and

Department of Oral and Craniomaxillofacial Surgery, University Hospital Freiburg, Hugstetter Str. 55, 79106 Freiburg, Germany: Dr. Dr. Fabian Duttenhoefer; Dr. Dr. Marc Anton Fuessinger, Yasmin Beckmann, Prof. Dr. Dr. Rainer Schmelzeisen
Department of Oral and Maxillofacial Surgery, HELIOS Dr. Horst-Schmidt-Kliniken, Academic Teaching Hospital University Mainz, Ludwig-Erhard-Str. 100, 65199 Wiesbaden, Germany: Prof. Dr. Dr. Knut A. Grötz
Institute of Medical Biometry and Statistics, Medical Data Science, Faculty of Medicine and Medical Center, University of Freiburg, Freiburg, Germany: PD Dr. Martin Boekerr
Translation from German: Cristian Miron
Citation: Duttenhoefer F, Fuessinger MA, Beckmann Y, Schmelzeisen R, Boeker M, Groetz KA: S3-guideline "Dental implants in patients with immunodeficiency" – practice-oriented treatment recommendations. Dtsch Zahnärztl Z Int 2020; 2: 196–199
DOI.org/10.3238/dzz-int.2020.0196–0199

* There is insufficient literature on primary immunodeficiency for the purpose of drawing conclusions regarding the influence of the underlying disease on the survival of dental implants. The classification 1) has been included for the scope of completeness.

** Although the underlying disease, diabetes mellitus, also has immunomodulatory influences, it is not included in this guideline. In this context, reference should be made to the Guideline "Dental Implants in Diabetes Mellitus" (AWMF register number 083–025).

Sjögren's syndrome or dermatomyositis as well as oral lichen planus and Sjögren's syndrome.

With regard to the modalities for treating autoimmune diseases such as rheumatoid arthritis, polymyalgia rheumatica, pemphigus vulgaris, scleroderma, Sjögren's syndrome and systemic lupus erythematosus, mainly steroid medication such as prednisone or other glucocorticoid derivatives are used for therapy. Neither the effect of the drug nor the underlying autoimmune disease was found to affect implant survival [8].

In principle, due to the possible risk of malignant transformation of the oral manifestation of the underlying diseases, stringent implant aftercare should be respected. There is evidence to suggest that the very rare peri-implant carcinomas occur with particular frequency in patients with oral lichen planus [22].

Special role of Crohn's disease

The chronic inflammatory bowel disease, Crohn's disease, predominantly affects the gastrointestinal tract, although a direct influence on the oral mucosa can also occur. The autoimmune inflammatory reactions are triggered by antigen-antibody complexes and this is why immunosuppressive and anti-inflammatory drugs are part of the treatment spectrum.

Pertaining to the therapy of patients with dental implants and Crohn's disease, a correlation was observed between implant loss and Crohn's disease in studies investigating early implant failure [2, 3, 30]. These results were statistically supported by further studies performed in 2007 and 2008. The basis for the cumulative incidence of early implant loss in Crohn's disease patients is controversially debated in the scientific community. Thus far, it has been shown that the osseointegration of dental implants can be influenced by antigen-antibody complexes due to autoimmune reactions in the area of bone-implant contact [26]. Moreover, malnourishment, which frequently occurs in the course of Crohn's disease, may also lead to inadequate bone healing around dental implants [9].

HIV

In the last 30 years, the HIV infection and the subsequent Acquired Immune Deficiency Syndrome (AIDS) has developed from being an epidemic with a devastating deterioration of patient's health, to being a stable, chronic disease thanks to current therapeutic management. Consequently, there is an increasing number of patients at different stages of the disease who wish for implant-based dental rehabilitation.

Compared to healthy patients, both HIV-seropositive patients with a CD4 cell count > 200 cells/µl and severely immunocompromised patients with a CD4 count of less than 200 cells/µl showed no significant differences after implant insertion with regard to the healing reaction, infection rate or postoperative complications. In addition, higher rates of implant loss were not observed [6, 16, 18]. Consequently, there was no evidence of a direct relationship between the risk of postoperative infections after implant treatment and the CD4 count [10, 20, 29].

In 75 % of the studies which were analyzed, different forms of antibiotic therapy were used for implant surgery. The prophylactic administration of antibiotics had no influence on the risk of postoperative infections, but it was shown to reduce the risk of implant failure [5, 15]. In summary, in a systematic review, antibiotic therapy was identified as one of the key factors which influences the analysis of dental implant osseointegration in HIV-positive patients [4].

Chemotherapy

Chemotherapy still constitutes one of the main pillars of modern cancer treatment. To date, the number of approved antineoplastic drugs is continuously growing due to the diversification of drugs which target specific types of cancer. Therefore, it is difficult to thoroughly investigate the mechanisms by which chemotherapeutic agents exert their biological effects on dental implants. For this reason, few studies have explored the potential effect of chemotherapeutic agents on osseointegration in spite of the fact that it is one of the most important parameters for successful implant therapy.

For already existing implants, there is evidence to suggest that chemotherapy can have a variety of negative effects such as mucositis, painful peri-implant infections as well as systemic effects such as fever and sepsis. However, these reported side effects have been observed primarily in blade and subperiosteal implants, which are hardly used nowadays [14]. Due to the fact that chemotherapy is associated with serious underlying diseases, there is a need for rigorous risk stratification involving an interdisciplinary approach; thus, close cooperation with the oncologist in charge of therapy is recommended.

Immunosuppresion after organ transplantation

The number of organ transplant recipients is increasing in tandem with medical progress. As a general rule, oral and maxillofacial infectious foci should be surgically operated prior to organ transplantation in order to reduce the rate of postoperative infection. After successful transplantation, patients who have had multiple tooth extractions before transplantation often require the functional rehabilitation of their masticatory functions [24, 27]. It is not uncommon for dental practitioners and oral and maxillofacial surgeons who are performing the treatment to be addressed with the patient's expressed wish for implant-supported prosthetic restorations.

In numerous studies, no demonstrable effect of the various post-transplantation protocols and their respective immunosuppression regimes, which use steroid and immunomodulating drugs (tacrolimus, sirolimus, cyclosporine and mycophenolate), could be shown on the implant survival rate.

The lack of randomized controlled trials limits the ability to draw conclusions. Nevertheless, no constraints for treatment with dental implants could be identified based on the results of the abovementioned studies.

Implant surgery should only be performed after consultation with the transplant physician in charge,

especially with regard to prophylactic/prolonged antibiotic therapy.

The practice-oriented treatment recommendations and checklist for risk stratification for indicating and managing dental implant treatment in immunocompromised patients is based on the current S3-guideline „Dental implants in patients with immunodeficiency".

Practice-oriented treatment recommendations

1. Indications

The medical status of the patient at the time of indication has a significant influence on the success rate of implant treatment. Conversely, it must also be ensured that the planned implant therapy does not endanger the patient's health [12]. Thus, before indicating implant treatment, the individual risk for implant loss and complications should first be assessed in all patients displaying an autoimmune disease, immunodeficiency, or who are under immunosuppression.

Primarily, an acute status of the underlying disease as well as any local or systemic contraindications should first be excluded. Further treatment planning should ideally include interdisciplinary cooperation (internists, rheumatologists, or other specialist disciplines).

2. Preoperative pre-treatment and diagnostics

In order to reduce the risk of infection and eliminate existing foci of infection, any necessary surgical interventions should be performed before implant surgery. Wound healing can provide an initial insight into the function of the immune system.

In addition to radiological diagnostics, the reported clinical findings should be included for the purpose of risk assessment, as they may provide possible clues regarding compromised soft tissue healing, bone remodeling or rates of bone regeneration. The prosthetic evaluation (prognosis of the remaining dentition, benefits of abutment augmentation or mucosal load reduction) is performed in the same manner as for healthy patients.

3. Implant prognosis

Literature data indicates that there are no relevant differences between patients with and without immunosuppression based on a follow-up period of at least 24 months. An exception to this are patients suffering from Crohn's disease.

4. Necessity of augmentation

Jaw bone augmentation is accompanied by increased demands on the bony recipient tissue. In cases of immunosuppression or immunodeficiency, it can be assumed that there is a less than adequate systemic immune response of the recipient tissue during wound healing [11, 21, 23].

5. Informing the patient

As part of routine patient education before planning any type of implant-based treatment, immunocompromised patients should be informed about the individual risks of disease-related complications (e.g. poorer implant prognosis in patients with Crohn's disease) and implant loss. Additionally, patients should be well-informed about the importance of follow-up care, which is adapted and structured according to their individual risk, and any potential follow-up costs.

6. Perioperative management

The low complication rates/ implant loss risks observed in the studies were all attained from patients undergoing perioperative systemic antibiotic prophylaxis.

7. Implant insertion

Submucosal and transmucosal healing are both possible. A recommendation regarding which type of healing is preferable cannot be derived from literature. Since the rates of bone remodeling and bone regeneration are reduced under immunosuppressive therapy, immediate or early loading must be critically appraised; this is also true for immediate implant insertion.

8. Prosthetic treatment

With regard to prosthetic treatment adapted to immunocompromised or immunosuppressed patients, no reliable data can be found in literature. Given the increased demands on the peri-implant soft tissue because of an inadequately functioning immune system, prosthetic designs which facilitate good oral hygiene and, if necessary, mucosal load relief should be pursued.

9. Follow-up care

An essential aspect for successful long-term implant therapy is regular follow-up care. In patients with immunodeficiency, the required follow-up care should be individually determined and consider the underlying disease, while being performed on a regular basis. It is advisable to provide patients with additional follow-up care during acute phases of immunodeficiency.

Checklist for risk stratification (low risk profile):

- phase of the underlying disease (chronic or inactive)
- stably adjusted immunosuppressive medication
- adequate oral hygiene
- focal infections are treated before implant surgery
- clinical and radiological examination reveals normal healing of hard and soft tissues
- bone augmentation is not necessary before implant surgery
- perioperative systemic antibiotic prophylaxis
- conventional loading (> 2 months healing period)
- features that facilitate good oral hygiene are integrated into prosthetic design
- follow-up care is adapted and structured according to the patient's specific risk

References

1. Ali Z, Baker SR, Shahrbaf S, Martin N, Vettore MV: Oral health-related quality of life after prosthodontic treatment for patients with partial edentulism: A systematic review and meta-analysis. J Prosthet Dent 2019; 121: 59–68.e3

2. Alsaadi G, Quirynen M, Komárek A, van Steenberghe D: Impact of local and systemic factors on the incidence of oral implant failures, up to abutment connection. J Clin Periodontol 2007; 34: 610–617

3. Alsaadi G, Quirynen M, Michiles K, Teughels WTH, Komárek A, van Steen-

berghe D: Impact of local and systemic factors on the incidence of failures up to abutment connection with modified surface oral implants. J Clin Periodontol 2007; 34: 610–617

4. Ata-Ali J, Ata-Ali F, Di-Benedetto N, Bagan L, Bagan JV: Does HIV infection have an impact upon dental implant osseointegration? A systematic review. Med Oral Patol Oral Cir Bucal 2015; 20: e347–356

5. Ata-Ali J, Ata-Ali F: Do antibiotics decrease implant failure and postoperative infections? A systematic review and meta-analysis. Int J Oral Maxillofac Surg 2014; 43: 68–74

6. Campo J, Cano J, del Romero J, Hernando V, Rodríguez C, Bascones A: Oral complication risks after invasive and non-invasive dental procedures in HIV-positive patients. Oral Dis 2007; 13: 110–116

7. Chaudhry HM, Bruce AJ, Wolf RC et al.: The incidence and severity of oral mucositis among allogeneic hematopoietic stem cell transplantation patients: a systematic review. Biol Blood Marrow Transplant 2016; 22: 605–616

8. Duttenhoefer F, Fuessinger MA, Beckmann Y, Schmelzeisen R, Groetz KA, Boeker M: Dental implants in immunocompromised patients: a systematic review and meta-analysis. Int J Implant Dent 2019; 5: 43

9. Esposito M, Hirsch JM, Lekholm U, Thomsen P: Biological factors contributing to failures of osseointegrated oral implants. (I). Success criteria and epidemiology. Eur J Oral Sci 1998; 106: 527–551

10. Gherlone EF, Capparè P, Tecco S et al.: A prospective longitudinal study on implant prosthetic rehabilitation in controlled HIV-positive patients with 1-year follow-up: the role of CD4+ level, smoking habits, and oral hygiene. Clin Impl Dent Relat Res 2015; 18: 955–964

11. Hartmann K, Koenen M, Schauer S et al.: Molecular actions of glucocorticoids in cartilage and bone during health, disease, and steroid therapy. Physiol Rev 2016; 96: 409–447

12. Hwang D, Wang H-L: Medical contraindications to implant therapy: part I: absolute contraindications. Impl Dent 2006; 15: 353–360

13. Jacobson DL, Gange SJ, Rose NR, Graham NM: Epidemiology and estimated population burden of selected autoimmune diseases in the United States. Clin Immunol Immunopathol 1997; 84: 223–243

14. Karr RA, Kramer DC, Toth BB: Dental implants and chemotherapy complications. J Prosthet Dent 1992; 67: 683–687

15. Keenan JR, Veitz-Keenan A: Antibiotic prophylaxis for dental implant placement? Evid Based Dent 2015; 16: 52–53

16. Kolhatkar S, Mason SA, Janic A, Bhola M, Haque S, Winkler JR: Surgical crown lengthening in a population with human immunodeficiency virus: a retrospective analysis. J Periodontol 2012; 83: 344–353

17. Lerner A, Jeremias P, Matthias T: The world incidence and prevalence of autoimmune diseases is increasing. International Journal of Celiac Disease 2016; 3: 151–155

18. Lin CA, Takemoto S, Kandemir U, Kuo AC: Mid-term outcomes in HIV-positive patients after primary total hip or knee arthroplasty. J Arthroplasty 2014; 29: 277–282

19. Margaix-Muñoz M, Bagán JV, Jiménez Y, Sarrión M-G, Poveda-Roda R: Graft-versus-host disease affecting oral cavity. A review. J Clin Exp Dent 2015; 7: e138–145

20. May MC, Andrews PN, Daher S, Reebye UN: Prospective cohort study of dental implant success rate in patients with AIDS. Int J Implant Dent 2016; 2: 20

21. Mitra R: Adverse effects of corticosteroids on bone metabolism: a review. PM R 2011; 3: 466–471, quiz 471

22. Moergel M, Karbach J, Kunkel M, Wagner W: Oral squamous cell carcinoma in the vicinity of dental implants. Clin Oral Investig 2014; 18: 277–284

23. Okamoto K, Nakashima T, Shinohara M et al.: Osteoimmunology: the conceptual framework unifying the immune and skeletal systems. Physiol Rev 2017; 97: 1295–1349

24. Perdigão JPV, de Almeida PC, Rocha TDS et al.: Postoperative bleeding after dental extraction in liver pretransplant patients. J Oral Maxillofac Surg 2012; 70: e177–184

25. Piccin A, Tagnin M, Vecchiato C et al.: Graft-versus-host disease (GvHD) of the tongue and of the oral cavity: a large retrospective study. Int J Hematol 2018; 6: 443

26. Quirynen M, De Soete M, van Steenberghe D: Infectious risks for oral implants: a review of the literature. Clin Oral Implants Res 2002; 13: 1–19

27. Rustemeyer J, Bremerich A: Necessity of surgical dental foci treatment prior to organ transplantation and heart valve replacement. Clin Oral Investig 2007; 11: 171–174

28. Smith DA, Germolec DR: Introduction to immunology and autoimmunity. Environ Health Perspect 1999; 107: 661

29. Stevenson GC, Riano PC, Moretti AJ, Nichols CM, Engelmeier RL, Flaitz CM: Short-term success of osseointegrated dental implants in HIV-positive individuals: a prospective study. JCDP 2007: 8: 1–10

30. van Steenberghe D, Jacobs R, Desnyder M, Maffei G, Quirynen M: The relative impact of local and endogenous patient-related factors on implant failure up to the abutment stage. Clin Oral Implants Res 2002; 13: 617–622

31. Vogel R, Smith-Palmer J, Valentine W: Evaluating the health economic implications and cost-effectiveness of dental implants: a literature review. Int J Oral Maxillofac Implants 2013; 28: 343–356

(Photo: @Conny Ehm Photography, Freiburg)

DR. DR. FABIAN DUTTENHOEFER
Department of Oral and Craniomaxillofacial Surgery
University Hospital Freiburg
Hugstetter Str. 55,
79106 Freiburg, Germany
fabian.duttenhoefer@uniklinik-freiburg.de

DZZ International
German Dental Journal International

Publishing Institution
International Journal of the German Society of Dentistry and Oral Medicine/Deutsche Gesellschaft für Zahn-, Mund- und Kieferheilkunde e. V. (Zentralverein, gegr. 1859), Liesegangstr. 17a, 40211 Düsseldorf, Phone: +49 2 11 / 61 01 98 – 0, Fax: +49 2 11 / 61 01 98 – 11

Affiliations
German Society of Periodontolgy (DG PARO)
German Society for Prosthetic Dentistry and Biomaterials
German Association for Conservative Dentistry
German Society of Craniomandibular Function and Disorders in the DGZMK
German Society of Paediatric Dentistry
German Academy of Oral and Maxillofacial Surgery
German Association of Dento-Maxillo-Facial Radiology (GSDOM)
German Academy of Dental Ergonomics
Group of Basic Science in Dentistry

Publisher
Deutscher Ärzteverlag GmbH
Dieselstr. 2, 50859 Köln;
Postfach 40 02 65, 50832 Köln
Phone: +49 2234 7011-0; Fax: +49 2234 7011-6508
www.aerzteverlag.de

Executive Board
Jürgen Führer

Director Business Division Medicine and Dentistry
Katrin Groos

Product Management
Carmen Ohlendorf, Phone: +49 02234 7011-357;
Fax: +49 2234 7011-6357;
ohlendorf@aerzteverlag.de

Editorial Office
Irmingard Dey, Phone: +49 2234 7011-242;
Fax: +49 2234 7011-6242; dey@aerzteverlag.de

Frequency
6 times a year

Layout
Linda Gehlen

Account
Deutsche Apotheker- und Ärztebank, Köln,
Kto. 010 1107410 (BLZ 370 606 15),
IBAN: DE 2830 0606 0101 0110 7410,
BIC: DAAEDEDD,
Postbank Köln 192 50–506 (BLZ 370 100 50),
IBAN: DE 8337 0100 5000 1925 0506,
BIC: PBNKDEFF

2. Volume
ISSN 2627-3489