

Christine Mirzakhania, Joachim Esken, Magdalena Schlegel, Guido Heydecke

Treatment of the edentulous mandible with a fixed bridge supported by 4 mm short implants in the molar region – a case report

Introduction: In implant therapy of the edentulous mandible, the decision of implant position is often determined by the need for bone augmentation in the molar region. Bone augmentation requires an extra surgery and thus presents higher risks and costs. In addition, the prosthetic treatment modality of fixed versus removable prosthesis is dependent on implant position. Usually, treatment decision is made in favor of lower costs, less risks and higher patient comfort, which often results in choosing interforaminal implants and removable overdentures. Extra short implants allow for fixed implant supported bridges in the edentulous jaw. Furthermore, in patients with advanced bone loss, pre-treatment with complex bone augmentation is not necessary.

Material & methods: This report describes the treatment protocol for a fixed implant-supported prosthesis in the edentulous mandible based on a patient case. Implant therapy was performed without bone augmentation procedures, and instead 4 mm short implants were inserted in the molar and 10 mm long implants were inserted in the canine region with diameters of 4.1 mm. After implant exposure in a second-stage surgery, a fixed prosthesis with CAD/CAM-fabricated framework and full porcelain veneer was cemented on individualized titanium abutments.

Results: The described treatment with a fixed prosthesis supported by extra short implants in the molar, and regular long implants in the canine region resulted in full rehabilitation of masticatory function in the edentulous jaw. From the patient's perspective the achieved rehabilitation is comparable to a status with own teeth and leads to an improvement in quality of life.

Conclusion: A straight forward implant placement without prior bone augmentation reduces the overall treatment time. In addition, more patients with advanced bone loss in the molar region of the lower jaw may benefit from the presented treatment protocol. From the perspective of the patient treated, the major improvement of chewing ability and the fixed character of the prosthesis made an immense positive impact.

Keywords: advanced bone loss; edentulous mandible; fixed bridge; short implants

University Medical Center Hamburg-Eppendorf, Department of Prosthetic Dentistry, Center for Dental and Oral Medicine, Martinistr. 52, 20246 Hamburg: Dr. Christine Mirzakhania (corresponding author), Joachim Esken, Dr. Magdalena Schlegel, Prof. Dr. Guido Heydecke

Citation: Mirzakhania C, Esken J, Schlegel M, Heydecke G: Treatment of the edentulous mandible with a fixed bridge supported by 4 mm short implants in the molar region – a case report. Dtsch Zahnärztl Z Int 2022; 4: 94–99

Peer-reviewed article: submitted: 26.02.2021, revised version accepted: 02.02.2022

DOI.org/10.53180/dzz-int.2022.0011

Introduction

Tooth loss and the corresponding oral rehabilitation are one of the major issues in health care service. Treatment options for tooth loss largely differ in costs, risks, and benefits for the patient. Implant treatment is a valuable option that minimizes risks and biological costs with survival rates of 95% after up to 10 years [10, 12].

Because the edentulous mandible in particular often provides insufficient bone volume, implant therapy is commonly combined with bone augmentation procedures. The latter is accompanied by additional invasive surgery, higher incidences of complications such as infections and loss of grafting materials, longer treatment time and higher costs.

Concepts with tilted implants to avoid bone augmentation procedures have been developed. For this, Malo and colleagues introduced the "All-on-4™ concept" (Nobel Biocare, Gothenburg, Sweden), where 4 implants are placed interforaminally, of which the distal implants are inserted tilted, the anterior implants axially. A fixed or removable prosthesis is fitted with 12 teeth replaced. In a 2015 retrospective case series, Malo et al. found an "... implant survival estimate of 95,4% after 7 years using the patient as the unit of analysis" [13]. In their systematic review on the All-on-4™ treatment, Patzelt et al. reported 99% survival rate for implants in the mandible after 36 months. However, authors concluded, that these results were highly biased, one of the reasons being that 69% of studies were conducted by a small group of experienced clinicians specialized in all-on-4. Also, study design and patient selection were detected as bias factors. Authors recommend further research with RCTs to gain reliable long-term data on survival and success for this procedure [14].

Another solution to avoid complex bone augmentation is the insertion of implants with reduced length to allow more patients to benefit from implant treatment with higher patient comfort. Implants with a length of 4 mm are the shortest currently available.

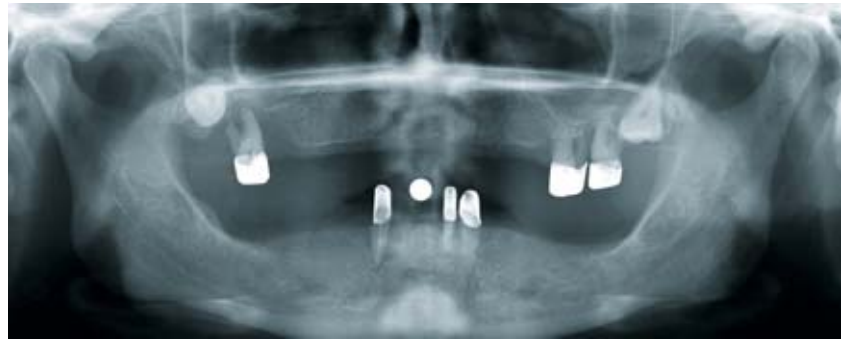

Figure 1 Pre-treatment standard radiograph

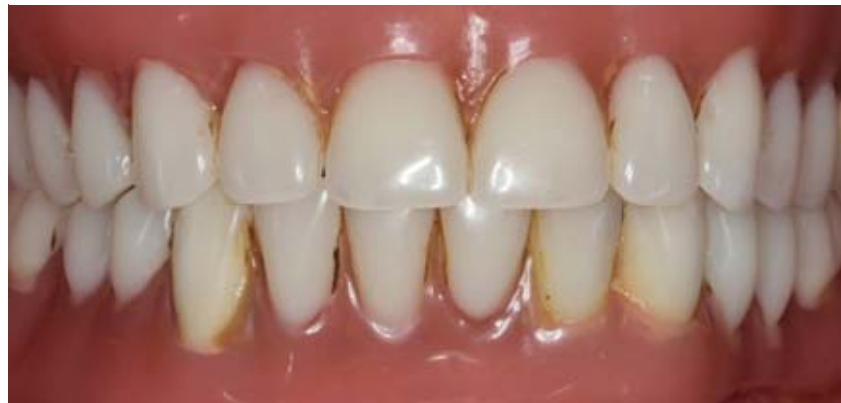

Figure 2 Pre-treatment clinical situation

Knowledge about biomechanics of dental implants has progressed and implant materials, surfaces and design have evolved accordingly over time. This leads to overcoming the dogma of achieving higher stability with long and wide implants [15]. Also, results of current studies appear to show promising evidence for the use of 4 mm short implants. Varying treatment protocols for the use of extra short implants in the mandible have been described.

Fabris and Anitua reported treatment protocols using extra short implants in combination with vertical bone augmentation placed in patients with shortened dental arches. After healing, implants were provided with splinted fixed crowns. Fabris used 4 mm short implants, whereas Anitua inserted 5.5 and 6.5 mm short implants [1, 7]. In a multicenter study, Slotte et al. treated patients with unilateral or bilateral tooth loss and inserted three to four 4 mm short implants without bone augmentation procedures, and splinted them with a bridge [17]. Calvo-Guirado et al. treated eden-

tulous patients and placed 6 implants, 2 implants of 10 mm length in the interforaminal area and 4 posterior implants with 4 mm length, without bone augmentation. A temporary prosthesis was inserted supported by provisional implants, and 90 days after implant surgery a screw-retained fixed prosthesis was fitted [4].

In the literature, survival rates for 4 mm short implants ranged from 92,2% after 5 years when inserted in free-end situations and splinted [17] to 97,5% after 1 year in edentulous mandibles in conjunction with four 4 mm short implants in the molar region and 2 interforaminal implants with regular length and a fixed prosthesis [4]. Comparable survival rates of implants of 4 mm and 8 mm length, the latter placed after 2-stage procedures with bone augmentation, were reported in a RCT by Rokn et al. [16]. In a split mouth design, 11 patients received 25 implants with 4 mm and 22 implants with 8 mm. In this case, survival rates for both implant lengths after 1 year were 100%. A statistically significant dif-

Implant position	Screw torque (Ncm)	RFA implant insertion (exposure) mesial (ISQ)	RFA implant insertion (exposure) buccal (ISQ)
36	25	72 (80)	53 (67)
33	35	72 (78)	62 (79)
43	30	68 (81)	58 (82)
46	35	74 (74)	67 (69)

Table 1 Screw torque, RFA at implant insertion and RFA at implant exposure (in brackets)

ference in complication rates between procedures of 4-mm and 8-mm implants was observed; the sites with bone augmentation as pre-treatment and 8-mm implants showed complications such as membrane exposures and paresthesia, whereas the 4-mm-implant sites did not [16]. Felice et al. found similar survival rates after 1 year for 1–3 splinted 4 mm short and >8.5 mm long implants in premolar and molar sites [8]. The aforementioned studies showed comparable implant survival rates between 4 mm short and >8 mm long implants, whereas a 2016 systematic review concluded that implants shorter than 8 mm present a greater risk for failure [11].

In this case report, a treatment protocol is introduced for the edentulous mandible with a metal-ceramic fixed dental prosthesis supported by two 4 mm short implants in the region of the first molars and two 10 mm, regular long implants in the canine region.

Materials and methods

General medical history: The 48 year old female patient presented herself at the dental hospital in 2018. Except for an allergy to egg protein and penicillin, the patient was healthy and a non-smoker and also she reported no complaints concerning mandibular joints.

Special medical history: The patient initially presented with upper and lower removable overdentures supported by 6 teeth (16, 26, 27, 33, 32, 43). The patient requested for better retention of the dentures and improved aesthetics. The fitting of new conventional dentures did not correspond to the patient's wishes

and she asked for information about the option of implant therapy.

Diagnostic findings: The extraoral findings showed no pathology. Intraoral findings revealed upper and lower telescopic overdentures at 16, 26, 27, 33, 32, 43 with poor prognosis. All remaining teeth presented with attachment loss of >75%, mobility grade II–III, horizontal and vertical bone loss with furcation involvement and advanced caries (Figure 1 and 2).

Diagnosis: Partially edentulous upper and lower jaws, supplied with insufficient partial removable dental prostheses retained with telescopic crowns.

Therapy: After obtaining panoramic radiography, the patient was informed about poor prognosis of the remaining teeth 16, 26, 27, 33, 32, 43. The teeth were subsequently extracted and the partial dentures were altered to full upper and lower dentures. After pre-treatment, the radiographic report was discussed with the patient to agree on a suitable treatment plan. The patient rejected conventional dentures. Due to advanced loss in bone height in the premolar and molar region, implant therapy in this area would have required an autologous bone grafting procedure prior to augmentation. To avoid bone augmentation, removable dental prostheses retained by 2 interforaminal implants with Locator® attachments (Zest Dental Solutions, Escondido, California, USA) or placement of 4 interforaminal implants and a bar-retained overdenture were discussed. As a treatment alternative, the patient was informed about participation in an ongoing prospective clinical study. Within this trial, patients were to receive a fixed dental

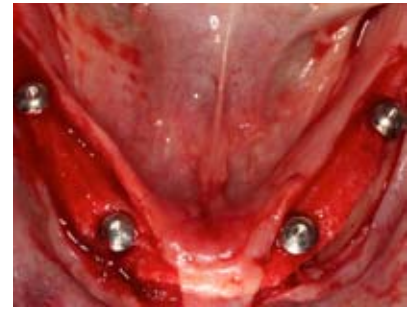

Figure 3 Implant surgery lower jaw

prosthesis supported by 2 extra short 4 mm implants in the region of the first molar and 2 regular 10 mm long implants in the canine region (“Prospective clinical study of Straumann Roxolid/SLActive short implants in edentulous mandible”, approved by Ethics committee of Hamburg, study no. PV 4805).

After the patient decided to participate in the study, impressions of the upper and lower jaw were taken, followed by a bite registration and fitting of the set-up for backward planning. The set-up was then transferred to a template with radio-opaque teeth, which the patient inserted during Cone Beam Computed Tomography (CBCT) for image guidance of implant placement. Implant surgery was planned using a computer software (coDiagnostix®, Dental Wings Inc., Montreal (QC), Canada) to ensure correct positioning and axis of the implants and of the tooth to be replaced. Tissue-level titanium-zirconium alloy implants with a length of 4 mm and a diameter of 4.1 mm were selected for positions 36 and 46, and implants with a length of 10 mm and a diameter of 4.1 mm were selected for positions 33 and 43 (Straumann® Standard Plus Implants (SLActive®), Straumann USA LLC, Andover, USA). Afterwards the template was altered to a surgical template. The template was used during the procedure to determine the correct implant position according to the prosthetic requirements.

On the day of the surgery, the patient received antibiotic prophylaxis one hour prior to treatment (Clindamycin 600 mg). Implants were placed in healed sites and in a 2-stage surgery. The surgical procedure for

implant placement was carried out in accordance to Straumann protocols. Local anesthesia was achieved by alveolar nerve block anesthesia. A mucoperiosteal flap with midline incision on the alveolar crest was performed from the molar region to the midline on both sides of the lower jaw. First, two 10-mm implant holes were drilled in the position of the canines, the template was temporarily fixed by these holes, and then the 4-mm short implant holes were drilled. Then all implants were inserted manually (Figure 3). All implants achieved primary stability. Additionally, Resonance Frequency Analysis measurements (RFA) were performed (Table 1).

Closure screws were inserted and sutures were placed for covered healing. After surgical procedures, a radiograph was obtained to verify implant positions (Figure 4). The lower denture served as interim prosthesis and was adapted. Generous clearance around the implants was established to ensure that there was no pressure affecting the healing of the implants. Post OP pain medication was administered (NSAID, Ibuprofen 400 mg), which was limited to 3 dosages a day every 6 hours for a maximum of 3 consecutive days. Also, a rinsing protocol with antiseptic mouthwash twice daily for 7 days was prescribed (Chlorhexamed Forte, alcohol-free 0,2%, GlaxoSmithKline Consumer Healthcare GmbH & Co. KG, Munich, Germany). The patient was instructed to exclusively consume soft foods while the implant healed.

After 3 months of healing without loading implant exposure proceedings took place. Since there was

less than 3 mm of attached gingiva around implants 36 and 46, a free gingival graft (FGT) was placed in the molar region. During surgery, RFA was measured again (Table 1). The patient was asked not to insert the lower prosthesis for one week to allow the grafts to heal. The soft tissue was left to heal for 6 weeks.

Impression for final restoration was performed using polyether (Impregum™, 3M Deutschland GmbH, Neuss, Germany) with custom-made open trays (Figure 5), followed by bite registration and refitting of the set-up. Titanium abutments were then tried in first. Subsequently, a CAD/CAM-fabricated, milled bridge framework made of a non-precious metal alloy from 36 to 46 was inserted. After full porcelain veneering in the dental laboratory, the fixed dental prosthesis was cemented using provisional cement (Temp Bond™ NE, KerrHawe, SA, Bioggio, Switzerland) (Figure 6, 7 and 8).

In the maxilla, an implant-supported bar denture was placed on 4 implants (in regions 16, 14, 24, 26) and 2 separate CAD/CAM-fabricated milled titanium bars (Atlantis™ Isus bars, Dentsply IH GmbH, Germany) with semi-precision attachments (Preci-Horix and Preci-Vertex attachments, Ceka© & Preciline©, Switzerland) (Figure 8). At the end of the prosthetic treatment, the patient was thoroughly instructed in proper oral hygiene and followed up after 2 weeks and then every 4 months.

Discussion:

The presented treatment offers different extensive advantages to patients

with edentulous mandibles and advanced bone loss. No bone augmentation procedure is needed, and due to the straightforward implant insertion, the treatment provides higher patient comfort.

The surgical risk associated with implant placement in non-augmented sites with 4 mm short implants is lower than that associated with placement of regular long implants in augmented sites, where postoperative complications, morbidity, and also bone loss occur more frequently than in non-augmented sites [6]. Additionally, a fixed construction is linked to higher quality of life compared to removable dentures [3]. Even though the observation period regarding the survival of 4 mm short implants is short and the variety of treatment protocols does not allow a transfer of these results to our treatment protocol, the splinting of 4 implants with a full arch bridge, the survival rates are nevertheless promising.

Mechanical or biological complications related to mandibular distortion and the splinted bridge on 4 implants are not foreseeable. To date, no evidence of clinical relevance of a relationship between mandibular distortion and implant loss or prosthetic failure has been found. It is suggested that mandibular distortion causes micro-movement at the bone-implant interface, which could lead to fibrous encapsulation instead of osseointegration of dental implants [5]. In our case, the fixed prosthesis was cemented to the individual abutments with provisional cement to avoid possible consequences of loading the bone-implant interface, as decementing the prosthe-

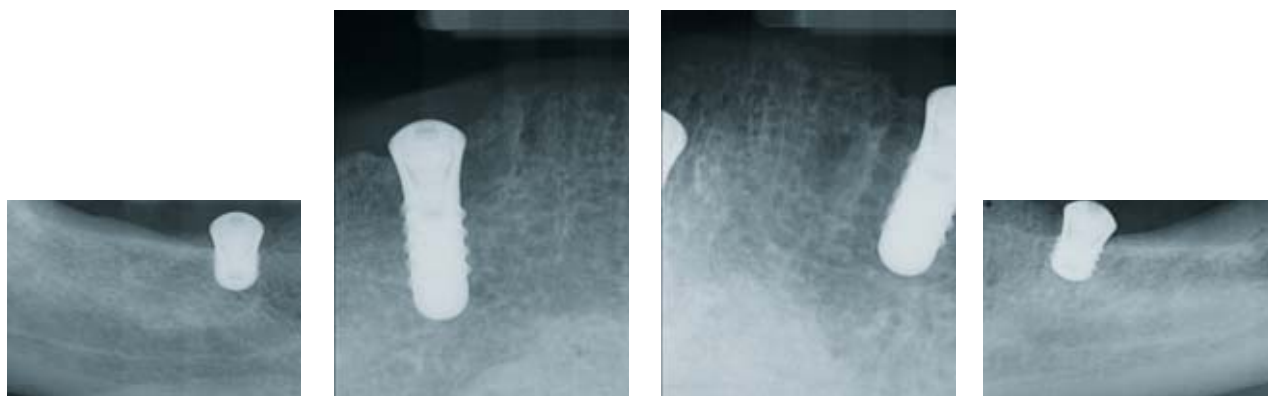


Figure 4a-d Radiographs after implant surgery, lower jaw

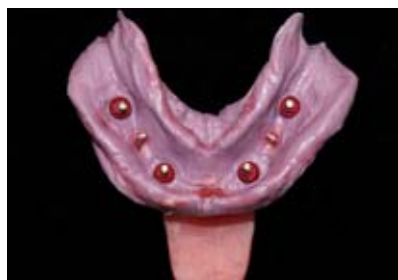

Figure 5 Lower jaw, impression

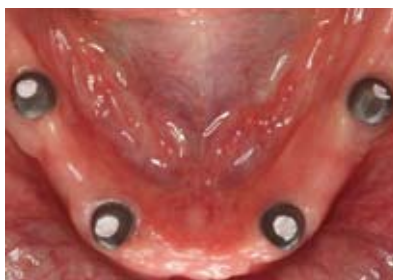

Figure 6 Lower jaw, abutments

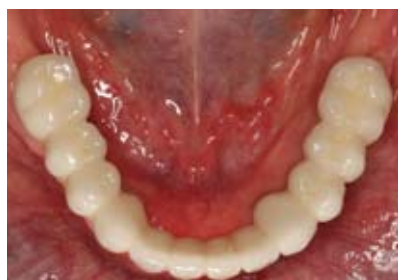

Figure 7 Lower jaw, fixed bridge

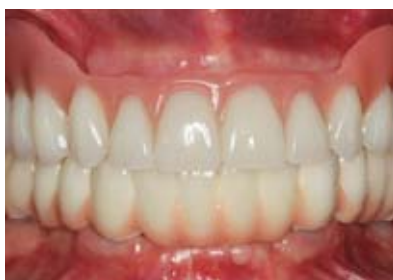

Figure 8 Intraoral overview

sis can prevent overloading of the implants. Crown margins were positioned supra- or epigingival to allow for full removal of cement residue.

Yet, the prognosis of a full-arch mandibular fixed prosthesis on 4 implants, with 2 of them being 4 mm short, is not predictable. Full-arch fixed dental prosthesis in the mandible on 4 implants with a conventional length of 10 mm or longer and 10–12 replaced units were classified to appearing successful in a systematic review [9]. It is unclear whether this assumption can be applied to our treatment protocol with 4 mm short implants in the molar region. In case of implant loss of only one implant, the inserted fixed prosthesis has to be removed. This would lead to further treatment and higher costs for patients. Then, a removable prosthesis could be more forward-looking in terms of anticipated implant loss.

One risk for the successful realization of the prescribed treatment could be the provisional phase from implant surgery to insertion of final prosthesis. In this case, the conventional prosthesis served as provisional restoration. Relining of the denture base after implant and exposure surgeries and establishing generous clearance around the implants cannot be regarded as a safe and predictable approach. Due to horizontal

movement of the denture on the mucosa and the yielding of the mucosa from vertical pressure, uncontrollable and destructive forces can possibly be transferred to the implants. To insert provisional implants and an implant-retained provisional prosthesis such as described by Calvo-Guirado [4] offers more safety. Nevertheless, additional costs for provisional implants and provisional prosthesis are a downside to this procedure.

In the edentulous mandible with advanced bone loss, the placement of 4 mm short implants leads to a shift in the crown-to-implant ratio, which could be another potential risk factor. There seems to be no correlation between bone loss and implant failure with increased crown-to-implant ratio [2]. The implant diameter, the number of splinted implants and the opposing dentition did affect bone loss and implant failure of short implants. A significant difference between antagonistic fixed prosthesis, negatively influencing bone loss around short implants and natural dentition or conventional full dentures was detected [2].

Conclusion:

By comparing the risks and benefits of the implant treatment of the edentulous mandible with a fixed bridge supported by 4 mm short implants in

the molar and 10 mm long implants in the canine region, results suggest that this procedure is not only straightforward, but also costs less and provides higher patient comfort than alternative treatments. Long-term outcomes of short implants are still lacking and more research according to the number of short implants in a full-arch reconstruction of the edentulous mandible are needed.

Conflict of interest

The authors declare that there is no conflict of interest within the meaning of the guidelines of the International Committee of Medical Journal Editors.

This case report originated from a study that was financially supported by Straumann GmbH.

References

1. Anitua E, Alkhraisat MH, Orive G: Novel technique for the treatment of the severely atrophied posterior mandible. *Int J Oral Maxillofac Implants.* 2013; 28: 1338–1346. doi: 1310.11607/jomi.13137
2. Anitua E, Alkhraisat MH, Pinas L, Begona L, Orive G: Implant survival and crestal bone loss around extra-short implants supporting a fixed denture: the effect of crown height space, crown-to-implant ratio, and offset placement of the prosthesis. *Int J Oral Maxillofac Implants.* 2014; 29: 682–689. doi: 610.11607/jomi.13404
3. Brennan M, Houston F, O'Sullivan M, O'Connell B: Patient satisfaction and oral health-related quality of life outcomes of implant overdentures and fixed complete dentures. *Int J Oral Maxillofac Implants.* 2010; 25: 791–800
4. Calvo-Guirado JL, Lopez Torres JA, Dard M, Javed F, Perez-Albacete Martinez C, Mate Sanchez de Val JE: Evaluation of extrashort 4-mm implants in mandibular edentulous patients with reduced bone height in comparison with standard implants: a 12-month results. *Clin Oral Implants Res.* 2016; 27: 867–874. doi: 810.1111/clr.12704. Epub 12015 Oct 12703
5. Choi AH, Conway RC, Taraschi V, Ben-Nissan B: Biomechanics and functional distortion of the human mandible. *J Investig Clin Dent.* 2015; 6: 241–251. doi: 210.1111/jicd.12112. Epub 12014 Jul 12117

6. Esposito M, Buti J, Barausse C, Gasparro R, Sammartino G, Felice P: Short implants versus longer implants in vertically augmented atrophic mandibles: A systematic review of randomised controlled trials with a 5-year post-loading follow-up. *Int J Oral Implantol* (New Malden) 2019; 12: 267–280
7. Fabris V, Manfro R, Reginato VF, Bacchi A: Rehabilitation of a severely resorbed posterior mandible with 4-mm extra-short implants and guided bone regeneration: case report with 3-year follow-up. *Int J Oral Maxillofac Implants*. 2018; 33: e147–e150. doi: 110.11607/jomi.16548
8. Felice P, Checchi L, Barausse C et al.: Posterior jaws rehabilitated with partial prostheses supported by 4.0 x 4.0 mm or by longer implants: one-year post-loading results from a multicenter randomised controlled trial. *Eur J Oral Implantol*. 2016; 9: 35–45
9. Heydecke G, Zwahlen M, Nicol A et al.: What is the optimal number of implants for fixed reconstructions: a systematic review. *Clin Oral Implants Res*. 2012; 23: 217–228. doi: 210.1111/j.1600-0501.2012.02548.x
10. Karoussis IK, Salvi GE, Heitz-Mayfield LJ, Bragger U, Hammerle CH, Lang NP: Long-term implant prognosis in patients with and without a history of chronic periodontitis: a 10-year prospective cohort study of the ITI Dental Implant System. *Clin Oral Implants Res*. 2003; 14: 329–339. doi: 310.1034/j.1600-0501.1000.00934.x
11. Lemos CA, Ferro-Alves ML, Okamoto R, Mendonca MR, Pellizzer EP: Short dental implants versus standard dental implants placed in the posterior jaws: a systematic review and meta-analysis. *J Dent*. 2016; 47: 8–17. 10.1016/j.jdent.2016.1001.1005. Epub 2016 Jan 1019
12. Leonhardt A, Grondahl K, Bergstrom C, Lekholm U: Long-term follow-up of osseointegrated titanium implants using clinical, radiographic and microbiological parameters. *Clin Oral Implants Res*. 2002; 13: 127–132. doi: 110.1034/j.1600-0501.2002.130202.x
13. Malo P, de Araujo Nobre M, Lopes A, Ferro A, Gravito I: All-on-4® treatment concept for the rehabilitation of the completely edentulous mandible: a 7-year clinical and 5-year radiographic retrospective case series with risk assessment for implant failure and marginal bone level. *Clin Implant Dent Relat Res*. 2015; 17: e531–541. doi: 510.1111/cid.12282. Epub 2014 Dec 12223
14. Patzelt SB, Bahat O, Reynolds MA, Strub JR: The all-on-four treatment concept: a systematic review. *Clin Implant Dent Relat Res*. 2014; 16: 836–855. doi: 810.1111/cid.12068. Epub 2013 Apr 12065
15. Renouard F, Nisand D: Impact of implant length and diameter on survival rates. *Clin Oral Implants Res*. 2006; 17: 35–51. doi: 10.1111/j.1600-0501.2006.01349.x
16. Rogn AR, Monzavi A, Panjnoush M, Hashemi HM, Kharazifard MJ, Bitaraf T: Comparing 4-mm dental implants to longer implants placed in augmented bones in the atrophic posterior mandibles: one-year results of a randomized controlled trial. *Clin Implant Dent Relat Res*. 2018; 20: 997–1002. doi: 1010.1111/cid.12672. Epub 2018 Oct 12611
17. Slotte C, Gronningsaeter A, Halmoy AM et al.: Four-millimeter-long posterior-mandible implants: 5-year outcomes of a prospective multicenter study. *Clin Implant Dent Relat Res*. 2015; 17: e385–395. doi: 310.1111/cid.12252. Epub 2014 Jul 12217



Photo: C. Mirzakhanian

DR. MED. DENT.
CHRISTINE MIRZAKHANIAN M.SC.
University Medical Center
Hamburg-Eppendorf
Department of Prosthetic Dentistry
Center for Dental and Oral Medicine
Martinistr. 52, 20246 Hamburg
c.mirzakhanian@uke.de