

# DZZ

4 | 2021  
3. VOLUME

## INTERNATIONAL

German Dental Journal International – [www.online-dzz.com](http://www.online-dzz.com)  
International Journal of the German Society of Dentistry and Oral Medicine

Current technological  
processing and uses of  
silicate ceramics

---

Vertical tooth surface loss –  
a narrative review. Part I

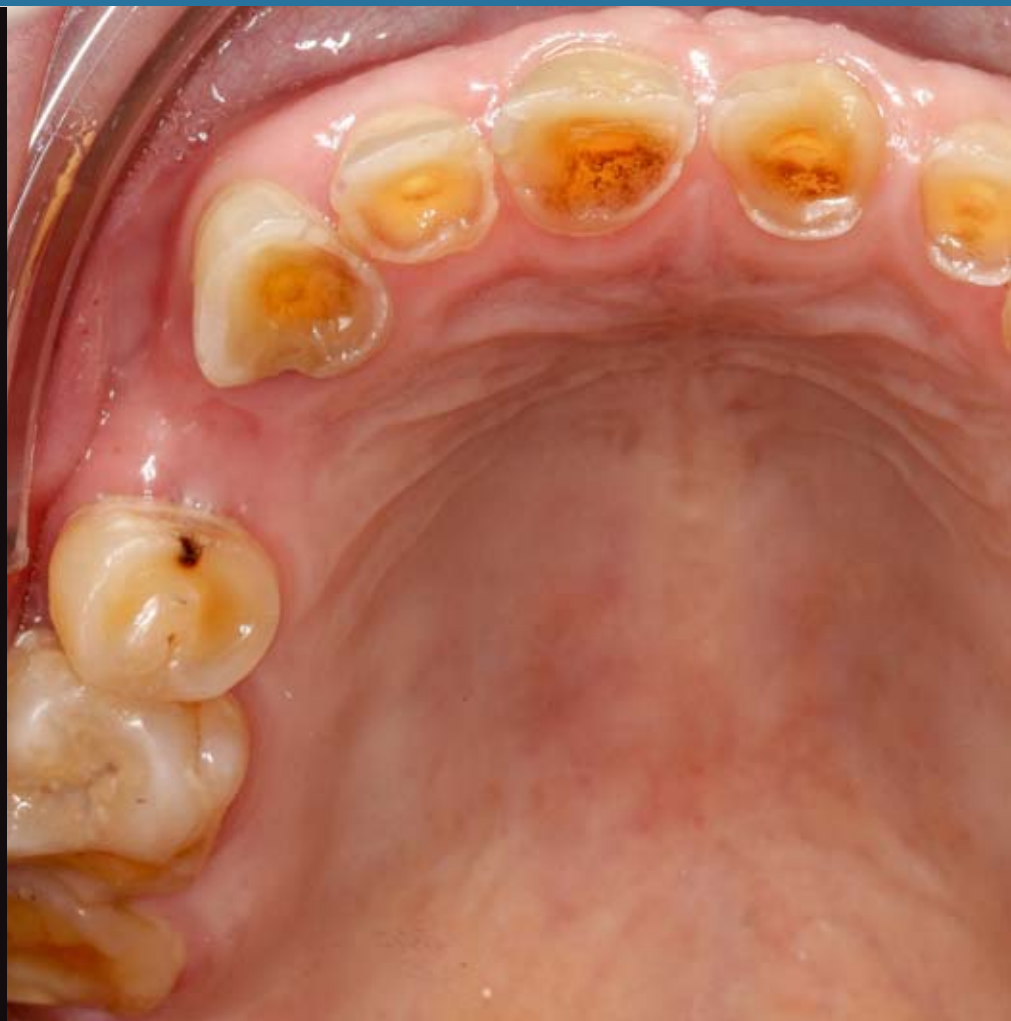---

Formation and detection of  
titanium release during  
implant insertion

---

Beware of contamination!  
Do hemostatic agents  
influence the microtensile  
bond strength of an universal  
adhesive to dentin?

---



This journal is regularly listed  
in CCMED / LIVIVO and in ICMJE.

 Deutscher  
Ärzteverlag

**PRACTICE****MINIREVIEW**

Alois Schmid, Michael Behr, Johann Wulff, Sybille Schneider-Feyrer, Georg Beierlein, Thomas Strasser

**143 Current technological processing and uses of silicate ceramics****RESEARCH****REVIEW**

Anuschka Josephine Roesner, Angelika Rauch, Michael Behr, Sebastian Hahnel

**148 Vertical tooth surface loss – a narrative review. Part I: Epidemiology and diagnosis****ORIGINAL ARTICLE**

Friedrich Müller, Janine Müller, Maximilian Schmidt-Breitung, Marcus Horn, Philipp Merkt, Viktor Foltin

**158 Formation and detection of titanium release during implant insertion**

Silke Jacker-Guhr, Anne-Katrin Lührs

**167 Beware of contamination! Do hemostatic agents influence the microtensile bond strength of a universal adhesive to dentin?****GUIDELINE**

Jaana-Sophia Kern, Taskin Tuna, Stefan Wolfart

**176 Update of the S3-Guideline “Implant-prosthetic rehabilitation in the edentulous maxilla” – What is new?****POSITION PAPER**

Edgar Schäfer, Bijan Vahedi, Bernard Bengs, Gabriel Krastl

**182 Endodontic pain management. Scientific Communication of the German Society of Endodontology and Dental Traumatology****188 LEGAL DISCLOSURE**

**Title picture:** From original article of Anuschka Josephine Roesner, Angelika Rauch, Michael Behr, Sebastian Hahnel, here figure 3: Patient case; the patient was examined before the start of treatment using the TWES. For the maxilla, a value of 4 was recorded for all 3 sextants (2nd sextant, palatal 3), p. 148–157; (Fig. 3: A. Roesner)

**Online-Version of DZZ International:** [www.online-dzz.com](http://www.online-dzz.com)

# Current technological processing and uses of silicate ceramics



## Question

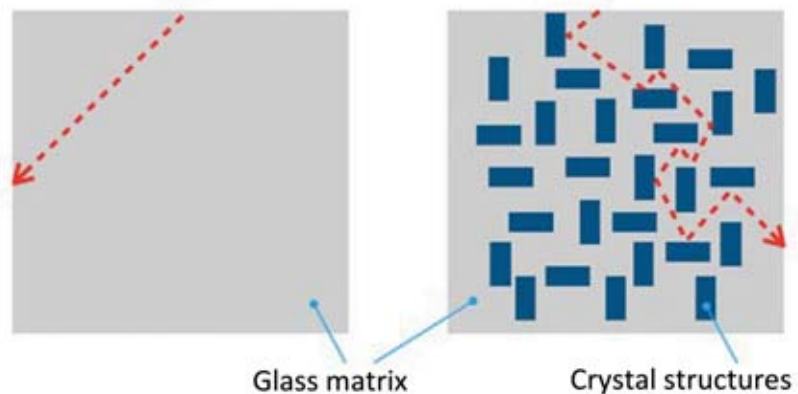
What are the clinical indication spectra and processing forms of silicate ceramics?

## Background

In dentistry, silicate ceramics with varying amounts of glass are distinguished from oxide ceramics with little or no glass content. In an ideal glass, there are no crystalline structural elements like in ceramics. The higher and finer the arrangement of the crystalline structure, the less light can pass through the ceramic (Fig. 1); the opaquer it appears. Owing to the presence of a certain proportion of amorphous structures in a silicate ceramic, the transmission of light is less impaired. However, the higher translucency of the ceramic comes at the expense of lower strength [7] (Fig. 2, Fig. 3).

In principle, silicate ceramics are produced from blanks of a molten glass in which crystal formation is stimulated in a succeeding thermal process. The properties of a silicate ceramic are determined by the nucleation, subsequent grain formation as well as the size of the newly formed crystals. Currently, the following types of silicate ceramics can be distinguished [7, 10]:

- Feldspathic ceramic which is indicated for classical veneering, veneers or partial crowns (e.g. Vitablocs Mark II, Vita Zahnfabrik, Bad Säckingen, D)



**Figure 1** Differences in light refraction. Left: amorphous ideal glass; right: silicate ceramic with a high proportion of semicrystalline structure.

- Leucite-reinforced glass-ceramic which is indicated for single crowns, veneers, partial crowns (e.g. Empress 1, Empress CAD, Ivoclar, Schaan, FL)
- Lithium disilicate ceramic which is indicated for crowns, three-unit bridges (anterior teeth, premolars), veneers, partial crowns (e.g. e.max CAD, Ivoclar, Schaan, FL)
- Zirconium oxide-reinforced lithium silicate which is indicated for crowns, small 3-unit bridges (anterior teeth, premolars), veneers, partial crowns (e.g. Celtra Duo, Dentsply-Sirona, Bensheim, D; Suprinity, Vita Zahnfabrik, Bad Säckingen, D).
- Fluorapatite ceramic which is indicated for overpressing of lithium disilicate frameworks (e.g. e.max Ceram), abutments (e.g. Strau-

mann Anatomic IPS e. max, Ivoclar, Schaan, FL) or overpressing of zirconium dioxide frameworks (e.g. e.max ZirPress, Ivoclar, Schaan, FL), as well as veneers.

## Processing methods

Nowadays, the following processing methods are distinguished for silicate ceramics (Tab. 1):

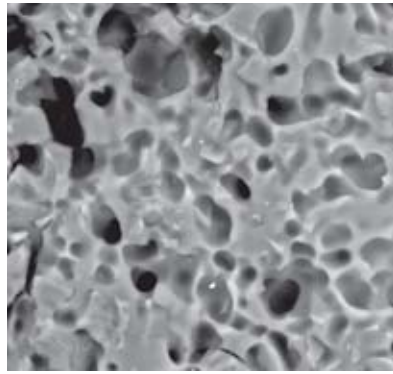
### Slip casting method

The classical veneering ceramics made of feldspar are applied onto the restorations by slip casting. Veneering ceramics for metal frameworks have a relatively high leucite content because leucite increases the coefficient of thermal expansion (CTE) and matches the CTE of the metal alloy. In contrast, veneering ceramics for frameworks made of zirconium


dioxide, for example, have a low leucite content (e.g. Vita VM9, Vita Zahnfabrik, Bad Säckingen, D). The dental technician's individual know-how in handling veneering ceramics determines variables such as the anatomical and color design, air inclusions, pores, duration and the number of firing cycles during slip casting.

### Pressing method

Since glasses represent „frozen liquids“, silicate ceramic masses such as feldspar or fluorapatite ceramics can be hot pressed (Fig. 4). The advantage of this method is that processing errors such as pores and defects can be minimized [7]. The shape of the veneering is designed on the framework material with the help of castable wax or resins. The framework and burnout form are embedded in investment material and the ceramic mass is pressed into the cavity under vacuum. In the so-called „cut-back technique“, individual requirements in terms of shape and color can be achieved. In this procedure, a part of the pressed material is removed. It is supplemented with color-optimizing dentin or enamel masses. For each type of framework material, special masses are available.



**Figure 2** Scanning electron micrograph of a feldspar ceramic (Vitablocs Mark II, VITA Zahnfabrik, D). Condition after 60 s of etching with 5 % hydrofluoric acid. After etching, the sharp-edged shapes of the feldspar crystals emerge from the glass matrix which now appears porous (magnification 5000×).



**Figure 3** Scanning electron micrograph of a lithium (di)silicate ceramic (e.max CAD, Ivoclar, Schaan, FL). Condition after 20 s of etching with 5 % hydrofluoric acid. The darker lithium (di)silicate crystals emerge from the brightly depicted glass matrix (magnification 4000×).

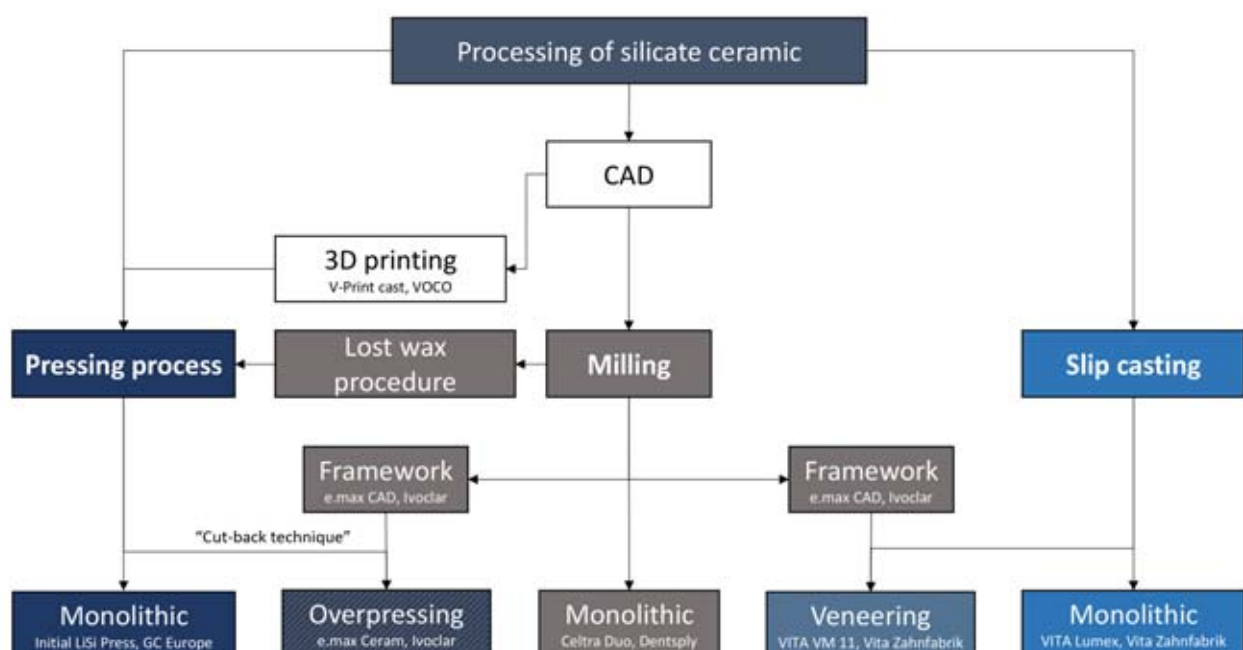
For example, Vita PM9 (Vita Zahnfabrik, Bad Säckingen, D) is suitable for overpressing metal alloys, e.max Ceram (Ivoclar) for overpressing lithium (di)silicate and e.max ZirPress (Ivoclar, Schaan, FL) for veneering zirconium dioxide frameworks.

Monolithic restorations can be produced using the pressing technique as well. Veneers, partial crowns (Fig. 5), crowns (Fig. 6) and small three-unit bridges can be fabricated

in this way. Pressed restorations generally exhibit a higher level of strength [1] and better interface quality than restorations which are fabricated using the slip casting method [7].

### Milling method

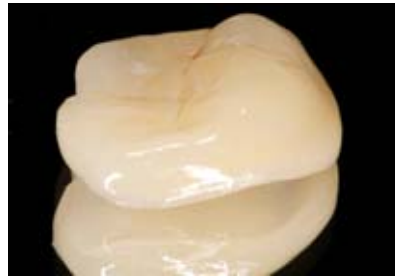
CAD/CAM milled veneers and restorations made of silicate ceramics are on the rise. Advantages of industrially produced blocks for milling in-



**Table 1** Overview of the various processing methods of silicate ceramics. (see text for details)



**Figure 4** Removed and cleaned hot pressed restorations. Processing method: e.max Press (Ivoclar, Schaan, FL).



**Figure 5** A so-called "tabletop" made of lithium (di)silicate.

clude better control of structural defects and composition. Moreover, the assessment of effective layer thickness of the veneer is easier to perform on the PC in CAD mode, which as a rule of thumb, should never be thicker (stronger) than 1.5 mm; otherwise, the chipping rate increases. The bonding together of the framework and the milled veneering is made in the furnace using a „glass solder“ (Ivoclar, Schaan, FL) or with an adhesive luting composite using the „rapid layer“ technique (Vita Zahnfabrik, Bad Säckingen, D) [7]. Silicate ceramics have the advantage that

they can be etched with hydrofluoric acid for the latter technique, thus creating a reliable bond. In contrast, zirconium dioxide cannot be etched. The bond to zirconium dioxide is considered as being partially problematic [3].

Due to their hardness, pressable crystalline lithium (di)silicate blocks are not suitable for milling processes. Hence, special milling blocks have been developed for this purpose. The blocks of lithium metasilicates are „presintered“ at low temperatures. As a result, they have a light blue, shimmering appearance. These presin-

tered blocks can be readily milled using the CAD/CAM process. The milled „blue“ blocks are so stable that they can be tried in. After their clinical check and adjustment, they receive the desired color through staining and crystallization firing. The flexural strength is specified as > 350 MPa, so that, crowns made of lithium (di)silicate do not need to be cemented adhesively.

So-called „zirconium dioxide-reinforced“ lithium silicates follow a comparable strategy [5]. Since the zirconium dioxide is only dissolved in the glass, the extent to which the zirconium dioxide causes reinforcement in the ceramic is controversial [4]. Lithium silicates such as Celtra Duo (Dentsply) or Suprinity (Vita) are fully crystallized. They can be milled and polished subsequently. However, the flexural strength reduces to around 210 MPa. This means that crowns with a flexural strength of less than 350 MPa must be adhesively cemented. An additional glaze firing increases the flexural strength to approximately 370 MPa, so that, crowns could then be conventionally cemented as well. In the case of den-

| Subgroups         | Amorphous, reinforced |
|-------------------|-----------------------|
| Indication        | V, PCr                |
| Flexural strength | < 150 MPa             |
| Cementation       | adhesive              |

**Feldspathic ceramic**

| Subgroups         | no glaze firing<br>with glaze firing                        |
|-------------------|---|
| Indication        | V, PCr, AntCr, PstCr<br>V, PCr, AntCr, PstCr, AntBr, PrBr   |
| Flexural strength | ca. 210 MPa<br>> 350 MPa                                    |
| Cementation       | adhesive<br>adhesive and AntCr/PstCr<br>also conventionally |

**Zirconium oxide-reinforced lithium silicate  
Zr-LiSi**

| Subgroups         | -                    |
|-------------------|----------------------|
| Indication        | V, PCr, AntCr, PstCr |
| Flexural strength | < 200 MPa            |
| Cementation       | adhesive             |

**Leucite ceramic**

| Subgroups         | -   |
|-------------------|---|
| Indication        | V, PCr, AntCr, PstCr, AntBr, PrBr             |
| Flexural strength | > 350 MPa                                     |
| Cementation       | adhesive (AntCr/PstCr also<br>conventionally) |

**Lithium disilicate  
LiSiO<sub>2</sub>**

**Table 2** Overview of silicate ceramics: Indication and cementation. V = veneer, PCr = partial crown/inlay, AntCr = anterior crown, PstCr = posterior crown, AntBr = three-unit anterior bridge, PrBr = three-unit premolar bridge

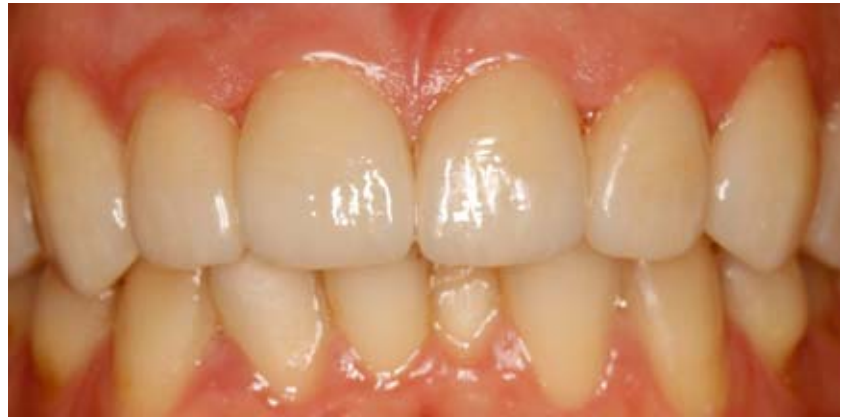tal bridges that are made of zirconium dioxide-reinforced lithium silicate or lithium (di)silicate, the following applies for safety reasons: it is better to cement adhesively (Tab. 2).

### Printing method

The first processes of purely additive manufacturing of dental restorations made from ceramics are still being tested [8]. Currently, 3D printing is already being applied for the pressing method [11] (Fig. 7). After the restoration design is made using CAD (e.g. a crown), it is first printed in a castable resin (e.g. Voco Cast, Voco, Cuxhaven, D). The stable resin restorations can be tried in and clinically adjusted. They are then embedded in an investment material, the (printed) resin form is burned out and the ceramic material is hot pressed into the remaining cavity. The final color is achieved using the above-mentioned cut-back technique or through staining and glaze firing.

### Cementation of silicate ceramic

Both in vitro as well as in vivo studies indicate that the adhesive bond appears to improve the stability of lithium (di)silicate restorations against masticatory forces more than conventional cementation with, for example, glass ionomer cement. In a clinical study, conventionally cemented crowns showed slightly higher rates of loss after 8 years, but these differences were not statistically significant [6]. Other clinical studies could not determine any difference in the survival rate of lithium (di)silicate restorations based on the cementation [12]. In vitro studies showed that adhesive cementation had slight advantages after mastication was simulated. In this context, it was interesting to observe that crowns cemented with self-adhesive composites only reached the fracture strength level of conventional cementation [9]. In order to attain the advantages of adhesive cementation, the classical adhesive procedure is apparently required. Especially in the case of adhesive cementation, silicate ceramics can reveal their great advantage over „translucent“ zirconium dioxides: in contrast to zirconium dioxide, silicate ceramics can be



**Figure 6** Anterior crowns made of lithium (di)silicate.



**Figure 7** Example of a 3D printing process (V-Print Cast, Voco, Cuxhaven, D) for the production of a pressed lithium (di)silicate crown. Left image: printed object in light-cured state after CAD production. Middle picture: fitted and finished resin crown before investment. Right image: finished ceramic crown.

etched with 5% hydrofluoric acid. After etching and the application of an adhesive silane, a reliable adhesive bond is formed. The indication spectrum of lithium (di)silicates and 3rd generation („translucent“) zirconium dioxides is largely identical [2].

### Statement

The optical properties of silicate ceramics make them well-suited for the replication of enamel and dentin with a natural appearance. Various types of silicate ceramics are available for veneering frameworks and monolithic restorations.

In most cases, the veneering is made with classic feldspathic ceramic which is applied using the slip casting method. However, (over-)pressing methods have been developed which can optimize the work process and increase the quality of the veneering. In the pressing method, leucite-rein-

forced glass-ceramic (metal frameworks) or fluorapatite ceramic [mostly for zirconium dioxide and lithium (di)silicate frameworks] are used.

The development of lithium (di)silicates (LiSiO<sub>2</sub>, Zr-LiSi) has significantly increased the strength of silicate ceramics and therefore expanded the range of indications for monolithic restorations. Their indications are largely identical to those of 3rd generation zirconium dioxides („translucent“ zirconium dioxides). Good optical properties, high strength, which permits the use of various luting concepts, the ability to be etched with hydrofluoric acid for a reliable adhesive bond if needed, enamel-like wear behavior, and various new processing options such as pressing, milling, and printing, distinguish the material group of silicate ceramics. They thus represent a sig-

(Fig. 1–7, Tab. 1 und 2: Behr et al.)

nificant enrichment of the clinical choice of dental materials.

### Conflicts of interest

The authors declare that there is no conflict of interest as defined by the guidelines of the International Committee of Medical Journal Editors.

Alois Schmid, Michael Behr,  
Johann Wulff, Sybille Schneider-  
Feyrer, Georg Beierlein,  
Thomas Strasser, Regensburg

### References

- Almarza R, Ghassemieh E, Shahrabaf S, Martin N: The effect of crown fabrication process on the fatigue life of the tooth-crown structure. *Mater Sci Eng C Mater Biol Appl* 2020; 109: 110272
- Behr M, Fuellerer J, Strasser T, Preis V, Zacher: Ist Zirkoniumdioxid gleich Zirkoniumdioxid? *Dtsch Zahnärztl Z* 2020; 75: 4–7
- Behr M, Proff P, Kolbeck C et al.: The bond strength of the resin-to-zirconia interface using different bonding concepts. *J Mech Behav Biomed Mater* 2011; 4: 2–8
- Belli R, Wendler M, Ligny D de et al.: Chairside CAD/CAM materials. Part 1. Measurement of elastic constants and microstructural characterization. *Dent Mater* 2017; 33: 84–98
- Dentsply Sirona: Celtra Duo. Zirkonoxidverstärktes Lithiumsilikat (ZLS). Fact-File. [www.dentsplysirona.com](http://www.dentsplysirona.com) › de\_DE › Fixed › Celtra\_Duo, 11.01.2021
- Gehrt M, Wolfart S, Rafai N, Reich S, Edelhoff D: Clinical results of lithium-disilicate crowns after up to 9 years of service. *Clin Oral Investig* 2013: 275–284
- Lohbauer U, Belli R, Wendler M: Keramische Materialien. In: Rosentritt M, Ilie N, Lohbauer U (Hrsg): *Werkstoffkunde in der Zahnmedizin. Moderne Materialien und Technologien*. Thieme, Stuttgart, New York 2018, 239–305
- Methani MM, Revilla-León M, Zandinejad A: The potential of additive manufacturing technologies and their processing parameters for the fabrication of all-ceramic crowns. A review. *J Esthet Restor Dent* 2020; 32: 182–192
- Preis V, Behr M, Hahnel S, Rosentritt M: Influence of cementation on in vitro performance, marginal adaptation and fracture resistance of CAD/CAM-fabricated ZLS molar crowns. *Dent Mater* 2015: 1363–1369
- Rosentritt M, Kieschnick A, Stawarczyk B: Zahnfarbene Werkstoffe im Vergleich. *Kleine Werkstoffkunde für Zahnärzte – Teil 4*. ZM-online 2019
- Rosentritt M, Kiesneck A, Hahnel S, Stawarczyk B: *Werkstoffkunde-Kompodium Zirkonoxid. Moderne dentale Materialien im Arbeitsalltag*. <https://werkstoffkunde-kompodium.de/das-werkstoffkunde-kompodium/zirkonoxid/>, 27.01.2020
- Teichmann M, Göckler F, Weber V, Yildirim M, Wolfart S, Edelhoff D: Ten-year survival and complication rates of lithium-disilicate (Empress 2) tooth-supported crowns, implant-supported crowns, and fixed dental prostheses. *J Dent* 2017; 56: 6–7



(Photo: UKR)

**PROF. DR. MED. DENT.  
MICHAEL BEHR**  
University of Regensburg  
Faculty of Medicine  
Franz-Josef-Strauss-Allee 11  
93053 Regensburg

[michael.behr@klinik.uni-regensburg.de](mailto:michael.behr@klinik.uni-regensburg.de)

Anuschka Josephine Roesner, Angelika Rauch, Michael Behr, Sebastian Hahnel

# Vertical tooth surface loss – a narrative review

## Part I: Epidemiology and diagnosis

**Introduction:** Tooth surface loss (TSL) is etiologically the sum of cumulative, multifactorial events, which ultimately lead to irreversible loss of tooth structure. Tooth surface loss can be pathological depending on its extent and progression and it can necessitate that the dentist initiates individualized preventive or therapeutic measures in cooperation with the affected patient.

**Methods:** A literature search for various studies published on PubMed and in the S3 guideline Bruxism up to February 2020 was conducted as part of this narrative review. The studies were evaluated based on topic-related search terms and also a manual search through their respective reference lists was performed. Standard values for TSL were defined and different methods for recording findings were compared.

**Results:** A sound diagnosis and regular monitoring are mandatory treatment steps for the dentist when treating patients with TSL. Clinical examinations including the “Tooth Wear Index” or the “Tooth Wear Evaluation System” are available for this purpose; these help convey, depending on the index applied, the qualitative and/or quantitative loss of tooth substance. Based on the severity and extent of TSL, thorough consideration is needed for determining if a conservative or an interventional treatment is indicated. Conservative measures include protective splints, fluoridation, and regular monitoring; interventional measures constitute definitive restorations after an initial pre-restorative phase.

**Conclusion:** A systematic decision tree for the diagnosis and therapy of patients with non-cariogenic, vertical TSL was developed based on the current recommendations found in literature. It is intended to provide dental practitioners with a guideline for the diagnosis and treatment of patients with TSL in their everyday practice.

**Keywords:** tooth surface loss (TSL); “Tooth Wear Evaluation System”; “Tooth Wear Index”; prosthetic rehabilitation

---

Department of Dental, Oral and Maxillofacial Medicine, Clinic for Prosthetic Dentistry, University Freiburg: Dr. Anuschka Josephine Roesner  
Department of Dental Prosthetics and Materials Science, University Leipzig: Dr. Angelika Rauch, Prof. Dr. Sebastian Hahnel  
Faculty of Medicine, Polyclinic for Dental Prosthetics, University of Regensburg: Prof. Dr. Michael Behr  
Translation from German: Cristian Miron

**Citation:** Roesner A, Rauch A, Behr M, Hahnel S: Vertical tooth surface loss – a narrative review. Part I: Epidemiology and diagnosis. *Dtsch Zahnärztl Z Int* 2021; 3: 148–157

**Peer-reviewed article:** submitted: 09.03.2020, revised version accepted: 10.06.2020

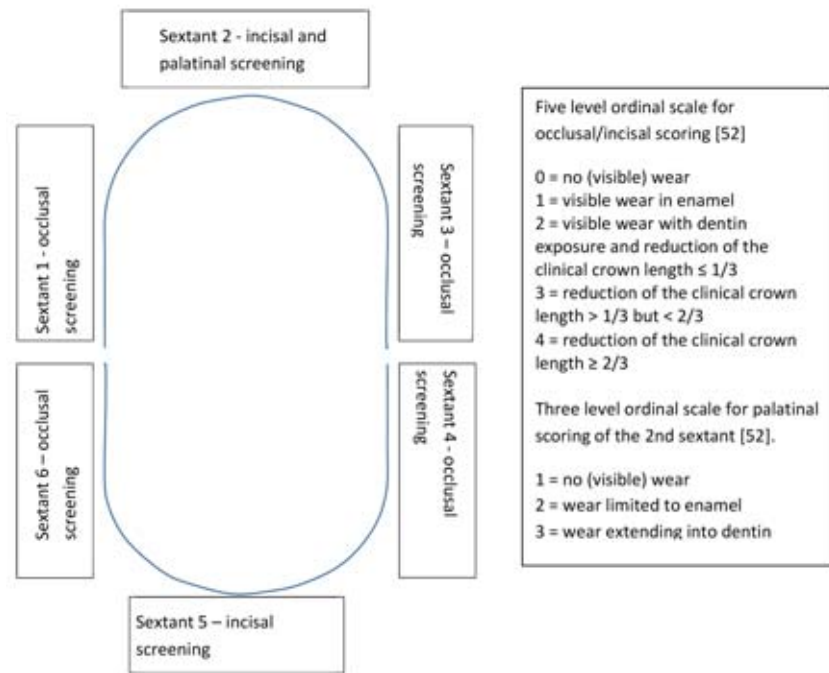
DOI.org/10.3238/dzz-int.2021.0017



## Introduction

The causes of pathological tooth surface loss (TSL) are multifaceted and range from carious lesions, trauma, idiopathic and genetic factors (e.g. molar incisor hypomineralization [MIH] or amelogenesis imperfecta) to bruxism. The first published studies on the topic of non-cariogenic tooth substance loss appeared as early as the 1970s [30, 40]. The terms abrasion, attrition, erosion, bruxism and demastication have been introduced in literature to define and better describe tooth surface loss.

Mechanical wear of the tooth substance is described using the terms abrasion and attrition. Attrition is caused by the physiological wear of the tooth substance as a direct result of tooth-to-tooth contact [14, 23]. The wear facets associated with attrition are particularly evident in patients with bruxism. Bruxism is defined as a repetitive masticatory muscle activity, which is characterized by the grinding or pressing of the teeth and/or tensing or pressing of the jaws against each other. The two different types are sleep and awake bruxism, which can occur solitarily or in combination [31, 32]. Whereas attrition describes intrinsic mechanical wear, which is caused by direct functional or parafunctional tooth-to-antagonist contact, abrasion refers to extrinsic mechanical wear, which is not related to the function or parafunctions of the masticatory system, but rather to oral hygiene measures, such as excessive contact pressure during tooth brushing or to habits such as fingernail or pin chewing [53]. Furthermore, it is worth noting that abrasion primarily refers to a physiological process; in contrast, pathological abrasion refers to mechanical wear, which includes abnormal wear of the hard tooth substance due to causes other than chewing processes. Enamel defects caused by toothbrushes and interdental space brushes, or so-called toothbrush abrasions, are often described in literature [54] and they are linked to improper brushing techniques. Other frequently listed examples that cause tooth abrasions are the retaining elements of dentures [22] or by foreign bodies such



**Figure 1** Quantitative screening using the TWES; in addition to the five level scale for each sextant [52], the palatal surfaces in the 2nd sextant are graded using a three level scale. For each sextant, the highest value is recorded.

as the wearing of piercings in the oral cavity or habits like chewing on pins [49].

Demastication represents a special form of abrasion. In this case, wear is produced by abrasive substances contained in food. Even though demastication plays a less important role in modern times, the examination of 7000 – 8000-year-old human skulls has proved that the main cause of severe tooth wear in the past was coarse food containing sand and gravel [51].

Erosion is defined as a pathological, non-cariogenic destruction process of tooth surface that is caused by the action of acids on teeth without obligatory bacterial involvement [49]. Etiologically, exogenous (extrinsic) and endogenous (intrinsic) factors can be differentiated. Extrinsic factors include erosions resulting from dietary habits, environmental influences or particular lifestyles (combination of frequent acidic substance consumption and excessive oral hygiene). In Addition drugs with a low pH value can either directly cause erosions, or indirectly, by reducing saliva secretion. Diseases,

which provoke reflux or chronic vomiting, are summarized as intrinsic factors, which can lead to erosions. In this case, lesions originating on the oral and occlusal tooth surfaces are predominantly observed [26].

With respect to a patient's particular case, it is unrealistic to consider the various causes of non-cariogenic TSL in isolation from one another; thus, it must be assumed that the loss is multifactorial and the different subtypes must be cumulated. For example, to some degree, the presence of erosions promotes the development of abrasions [49].

With regard to the long-term preservation of the natural dentition in the context of an aging population, the problem of non-cariogenic TSL is becoming increasingly important [41]. Given these circumstances, the diagnosis and regular clinical monitoring of TSL is substantial. Yet, to date, there are few evidence-based guidelines, which describe a systematic treatment approach for helping to guide the diagnosis and treatment of patients with TSL in everyday practice. As part of the literature search conducted in this narrative re-

| Author                          | Sample size  | Prevalence  |
|---------------------------------|--|---|
| <b>Abrasion</b>                 |  |   |
| Kitchin 1941 [27]               | n = 200  | 20–29 yrs: 58,0 %<br>30–39 yrs: 84,0 %<br>40–49 yrs: 96,0 %<br>50–59 yrs: 94,0 %                      |
| Radentz et al. 1976 [42]        | n = 80   | 17–45 yrs: 50,0 %   |
| Bergström and Lavstedt 1979 [9] | n = 818  | 18–25 yrs: 15,9 %<br>26–35 yrs: 37,6 %<br>36–45 yrs: 41,1 %<br>46–55 yrs: 40,3 %<br>55–65 yrs: 40,8 % |
| Hand et al. 1986 [21]           | n = 520  | □□65 yrs: 56,0 %  |
| Bergström and Eliasson 1988 [8] | n = 250  | 21–60 yrs: 85,0 %<br>at least 1 surface lesion<br>22,0 % at least 1 deep lesion                       |
| Akgül et al. 2003 [1]           | n = 428  | 20–30 yrs: 2,0 %<br>31–40 yrs: 5,7 %<br>41–50 yrs: 12,9 %<br>□□51 yrs: 29,6 %<br>Total: 9,1 %         |
| <b>Erosion</b>                  |  |   |
| Nautsch and Klimm 1989 [38]     | n = 300 (16–35 yrs)                                  | 4,0 %   |
| Klimm et al. 1991 [28]          | n = 2499 (16–35 yrs)                                 | 3,4 %   |
| Jaeggi et al. 1999 [25]         | n = 417 (19–25 yrs)                                  | 82,0 % (erosion degree I occlusally)  |
| Williams et al. (1999) [56]     | n = 525 (14 yrs)                                     | labial: 17,0 %<br>palatinal: 12,0 %   |
| Deery et al. 2000[12]           | n = 129 (11–13 yrs) (UK)<br>n = 125 (11–13 yrs) (US) | UK: 41,0 %<br>US: 37,0 %  |
| Ganss et al. 2001 [19]          | n = 1000 (□□11,4 yrs)                                | Deciduous teeth: 71,0 %<br>Permanent teeth: 12,0 %  |
| Al-Ma Jed et al. 2002 [2]       | n = 354 (5–6 yrs)<br>n = 862 (12–14 yrs)             | 5–6 yrs: 34,0 %<br>12–14 yrs: 26,0 %  |
| Al-Malik et al. 2002 [3]        | n = 987 (2–5 yrs)                                    | 31,0 %  |
| Schiffner et al. 2002 [47]      | n = 655 (35–44 yrs)<br>n = 1027 (65–74 yrs)          | 35–44 yrs: 10,7 %<br>65–74 yrs: 7,9 %   |
| Arnadóttir et al. 2003 [4]      | n = 278 (15 yrs)                                     | 21,6 %  |
| Dugmore and Rock 2004 [13]      | n = 1753 (12 yrs)                                    | 59,7 %  |
| Caglar et al. 2005 [10]         | n = 153 (11 yrs)                                     | 28,0 %  |
| Peres et al. 2005 [39]          | n = 499 (12 yrs)                                     | 13,0 %  |
| Salas et al. 2017 [46]          | n = 1210 (8–12 yrs)                                  | 25,1 %  |
| Truin et al. 2005 [50]          | n = 832 (12 yrs)                                     | 24,0 %  |
| Wiegand et al 2006 [55]         | n = 463 (2–7 yrs)                                    | Up to 32,0 %  |

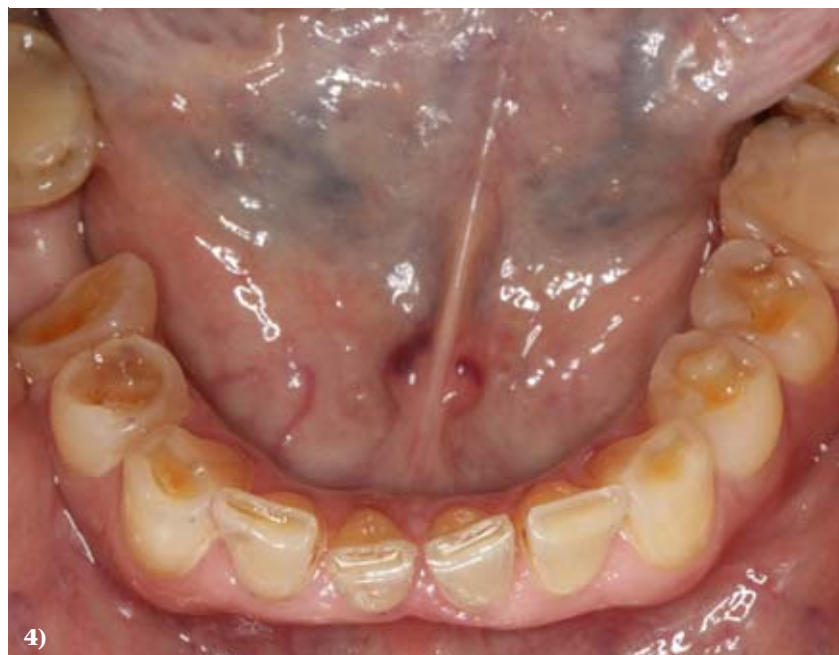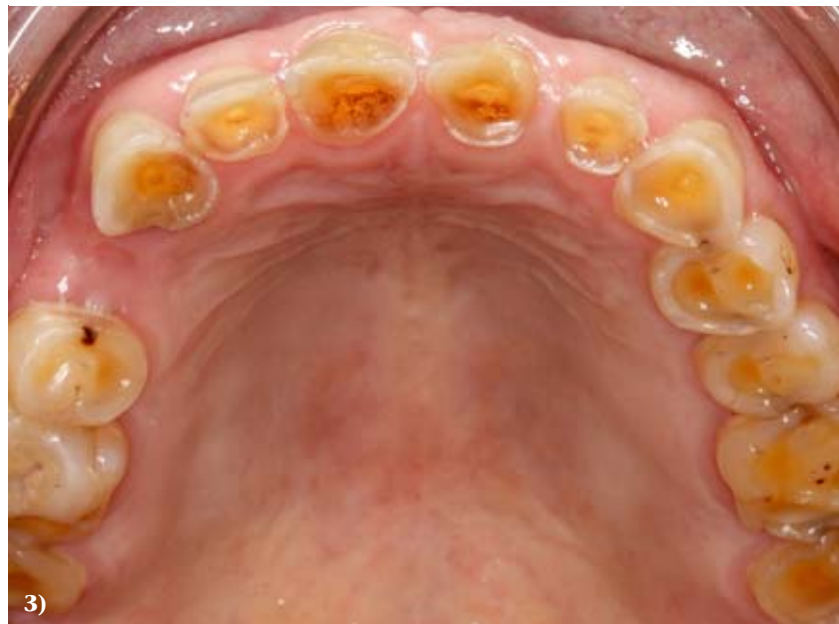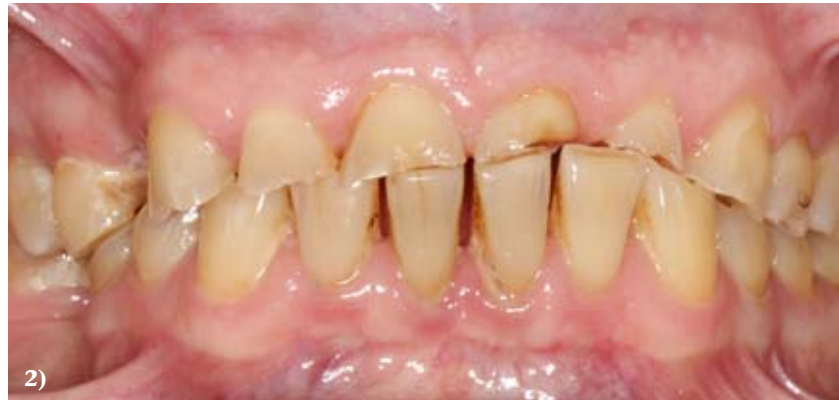**Table 1** Study results of the prevalence of abrasion and erosion.

view, various studies published on PubMed as well as in the S3 guideline Bruxism up to February 2020 were evaluated on the basis of topic-related search terms; moreover, a manual search through the studies' respective reference lists was conducted. The search terms used were: tooth surface loss, (severe) tooth wear, (loss of) vertical dimension, tooth wear treatment options, prevalence of dental erosion, prevalence of dental abrasion, diagnosis and management of dental erosion, tooth wear index, tooth wear evaluation system. The first part of this narrative review describes the epidemiology, classification and diagnosis of non-cariogenic TSL; the second part outlines different treatment options while also presenting effective, evidence-based therapeutic approaches with a focus on restorative prosthetic measures.

### Norm values for non-cariogenic TSL

The findings in literature vary with regard to the prevalence of non-cariogenic TSL due to the heterogeneity of the sample groups in terms of collective size, age and eating habits (Table 1).

For instance, a large-scale epidemiological study that examined over 3100 young European adults aged 18–35 years (3187 patients) reported a prevalence of non-cariogenic TSL in about 30 % of young adults [7]. A systematic review from 2015 analyzed the incidence of erosive TSL in children as well as younger adults aged 8–19 years and it reported a 30 % prevalence of non-cariogenic TSL [45]. Another large epidemiological study involving 1125 Dutch adults investigated the parameters age, gender, socioeconomic status and TSL of the affected teeth. The prevalence of mild, moderate, and severe TSL was reported to be 13 %, 80 %, and 6 %, respectively. Men and persons having a low socioeconomic status exhibited a higher severity of TSL than women or persons with a higher socioeconomic status. Additionally, it was found that mild to moderate tooth wear occurs frequently and that its prevalence increases with age [53].



**Figures 2–4** Patient case; the patient was examined before the start of treatment using the TWES. For the maxilla, a value of 4 was recorded for all 3 sextants (2nd sextant, palatal 3). In the mandible, a value of 3 in 4th and 6th sextants and a value of 2 for the 5th sextant was recorded.

| Score | Surface | Criteria   |
|-------|---------|--|
| 0     | B/L/O/I | No loss of enamel surface characteristics                                |
|       | C       | No change in contour   |
| 1     | B/L/O/I | Loss of enamel surface characteristics                                   |
|       | C       | Minimal loss of contour  |
| 2     | B/L/O   | Loss of enamel exposing dentine for < 1/3 of tooth surface               |
|       | I       | Loss of enamel just exposing dentine                                     |
|       | C       | Defect is less than 1 mm deep  |
| 3     | B/L/O   | Loss of enamel exposing dentine for > 1/3 of tooth surface               |
|       | I       | Loss of enamel and substantial loss of dentine                           |
|       | C       | Defect is 1–2 mm deep  |
| 4     | B/L/O   | Complete enamel loss, pulp exposure, secondary dentine exposure          |
|       | I       | Pulp exposure or exposure of secondary dentine                           |
|       | C       | Defect is more than 2 mm deep, pulp exposure, secondary dentine exposure |

**Table 2** Tooth Wear Index from Smith und Knight [48]; in the description of the tooth surfaces, “B” stands for “buccal”, “L” for “labial”, “O” for “occlusal”, “I” for “incisal” and “C” for “cervical”.

To a certain degree, TSL is an age-related physiological phenomenon [6]. In many studies, TSL is more pronounced in men than in women [24]; conversely, in other study groups, no gender-specific differences were found [43]. Scientific studies have described the shortening of the lower and upper incisors from the age of 10 to the age of 70 based on 1239 permanent upper and lower incisors from 346 patients. It was determined that the physiological TSL of lower incisors and upper incisors was 0.024 mm and 0.017 mm per year, respectively [43]. Other studies have defined the physiological TSL in premolars to be 0.015 mm per year and in molars as much as 0.029 mm [29]. Moreover, it seems that TSL is periodic with phases of progression and remission [44]. If TSL exceeds these determined normal values, or depending on the age of the patient, there is severe TSL. The dentist must diagnose this in good time in order to be able to initiate a patient-oriented and target-oriented treatment strategy.

Based on the studies that are listed in Table 1, non-cariogenic TSL can be diagnosed at any age, depending on the genetic predisposition, consumer habits and behavioral patterns.

### Clinical guidelines

Pathological TSL can lead to increased tooth sensitivity, an impaired esthetic appearance or give rise to functional problems [34]. In order to be able to decide if TSL has to be treated, it is necessary to assess it using standardized criteria; in this respect, patient age, the degree of TSL and the course of TSL (episodic or progressive) can play a considerable role. Especially among the elderly, increased TSL is considered physiological, in spite of the fact that the vertical dimension can remain unchanged due to the process being gradual (thesis according to Dawson [11]). For instance, the restoration of the presumed loss of vertical jaw relation, with the intention of changing the esthetic appearance of the patient, can represent overcompensation

and potentially trigger para-functional activities or functional complaints [36].

Nevertheless, in case of pathological changes, dental treatment may be indicated. Particularly severe TSL, which is accompanied by a severe loss ( $\geq 1/3$ ) of the clinical crown as well as dentin exposure, often represents an indication for therapeutic intervention [34].

Rapid progression may be clinically observed as markedly reduced remaining tooth hard substance or massively reduced tooth crowns. Clinical symptoms may include increased tooth sensitivity of the affected teeth due to exposure of dentin with pulp involvement. Vertically, a massively reduced dental crown may correlate with a lack of occlusal space, which in turn, limits the therapeutic options. Based on the authors' experience, a reduced vertical dimension can be accompanied by impaired masticatory efficiency, a negative smile line, or even increased interocclusal space. For these reasons, it can be assumed that the recon-

| Score per sextant | Meaning                                  |  |
|-------------------|--|--|
| 0                 | No tooth surface loss                    |  |
| 1                 | Initial loss of tooth texture            |  |
| 2                 | Distinct defect, hard tissue loss < 50 % |  |
| 3                 | Hard tissue loss ≥ 50 %                  |  |
| Risk assessment   | Total score (Sum of scores)              | Treatment  |
| No risk           | ≤ 2                                      | – regular check-ups and aftercare (repeat at 3-year intervals)   |
| Low Risk          | 3–8                                      | – motivation and instructions regarding correct oral hygiene and dietary advice<br>– close monitoring and aftercare as well as routine clinical examinations (every 2 years)   |
| Moderate Risk     | 9–13                                     | – oral hygiene instructions as well as remotivation and dietary advice<br>– develop strategies to eliminate the associated causes<br>– fluoridation measures or other strategies in order to increase resistance of the tooth surface<br>– regular monitoring of the wear with study casts, photos or silicone impressions<br>– repetition at least every 6 to 12 months   |
| High Risk         | ≥ 14                                     | – oral hygiene instructions as well as oral hygiene remotivation and dietary advice<br>– develop strategies to eliminate the respective causes<br>– fluoridation measures or other strategies in order to increase resistance of the tooth surface<br>– repeat at 6–12 month intervals<br>– regular monitoring of the wear with study casts, photos or silicone impressions<br>– repetition at least every 6 to 12 months<br>– restorative intervention may be necessary |

**Table 3** Basic Erosive Wear Examination (BEWE) [5].

structive measures for restoring function, phonetics and esthetics become more elaborate the later the therapeutic intervention is begun [35].

### Diagnosis

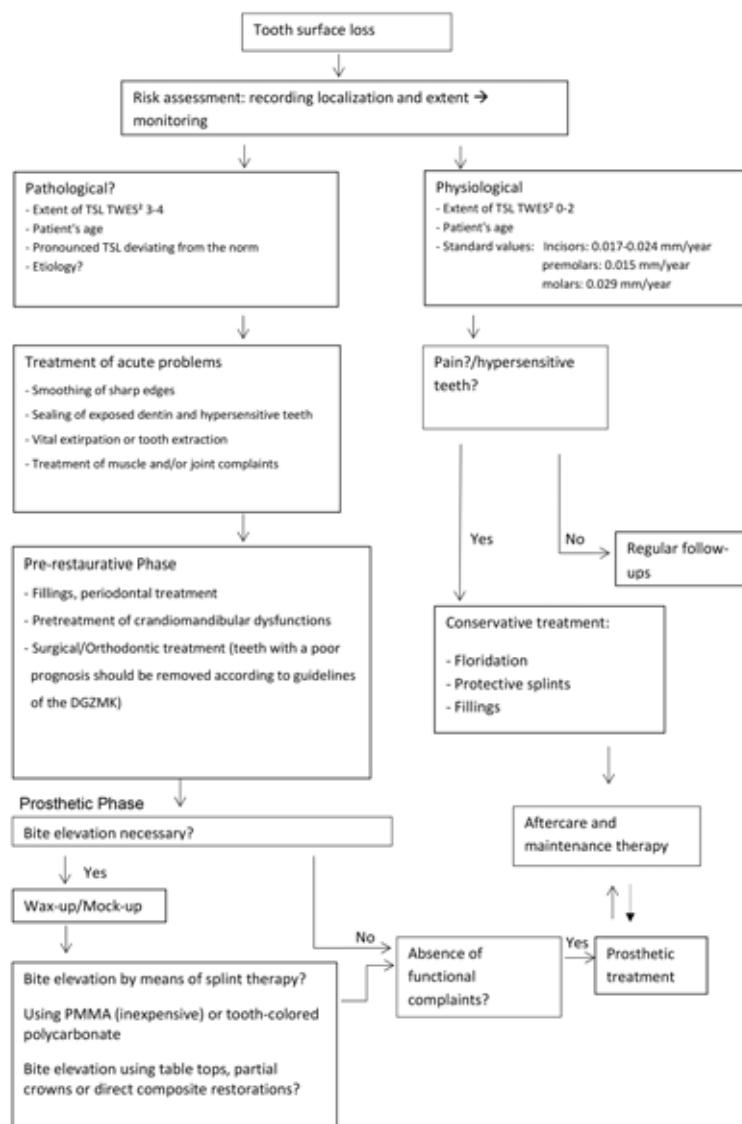
The dental care and treatment of patients with non-cariogenic TSL is lengthy and demanding. However, a structured approach facilitates the clinical decision-making process and treatment. In this context, TSL and, if possible, the corresponding subtype should be diagnosed [52]. Afterwards, an analysis of the extent of the loss is meaningful [52]. Clinical examinations as well as laboratory techniques such as the superimposition of digital images are available for this purpose [33].

Indices convey the quantitative loss of tooth substance and make it easier for the dentist to record the progression of the loss. The „Tooth Wear Index“ (TWI) by Smith and Knight (Table 2) represents the most widely used and best evaluated scientific index for recording TSL [35]. The TWI is suitable for assessing the severity of TSL [48] as well as for regular follow-up examinations. Depending on the extent of TSL, five grades of loss can be differentiated. TSL is recorded separately for each tooth surface in relation to the anatomical structures. It is not possible, however, to make a statement about the etiology of tooth wear using this index.

Several years ago, Bartlett presented an alternative index [5]. When

using the „Basic Erosive Wear Examination“ (BEWE), the percentage of tooth wear is determined with respect to the tooth and sextant. Depending on the extent, it is differently evaluated (Table 3), with the most severe finding per sextant always being documented. By adding the points for each sextant, the total score and possible treatment options are revealed [5].

In the current S3 guideline on bruxism, published by the cooperation between the German Society for Functional Diagnostics and Therapy (DGFD) and the German Society for Dental, Oral and Maxillofacial Surgery (DGZMK), the Tooth Wear Evaluation System (TWES) is described, which enables both a



**Figure 5** Decision tree for possible treatment options in patients with TSL.

qualitative (Table 4) and quantitative appraisal (Figures 1–4) of TSL. With the help of the TWES, the TSL can be detected (qualitatively), the severity assessed (quantitatively), the probable causes diagnosed, and the condition and possible progression monitored. The degree of severity determines the ensuing treatment, whereby Wetselaar and Lobbezoo differentiate between diagnostic modules for general practitioners and specialists (Table 5) [52].

Risk assessment is an important aspect for evidence-based and patient-oriented decision making. In patients with severe TSL, conservative treatment methods such as

preventive measures and regular follow-ups should be carefully weighed against the risk of further substance loss or the possible failure of the existing restorations.

In addition to using an index to quantify the extent of TSL, further parameters should be considered for deciding if a prosthetic restoration is indicated. One such parameter includes the wishes and motivation of the patient. In the course of clinical treatment, the authors often found that patients with TSL desire restorative treatments because they regularly complained of hypersensitivity, pain when drinking and eating, and esthetic deficits. With time, it is not

unusual for the affected patients to train themselves to adopt a relieving posture when eating. Thorough consideration is needed to determine if the increased sensitivity is due to TSL, or rather, to carious lesions or periodontal defects. The decision-making process for choosing the ideal treatment should also take the rate of progression, patient age and etiology of TSL into account.

Based on current scientific studies, the authors of this article have developed a decision tree to help provide dentists with a guideline for differentiated decision making in patients with TSL (Figure 5). It is important to note that restorative treatments are not always indicated. Especially in patients with non-cariogenic TSL, prevention and aftercare are of utmost importance. The dental therapist should always try to identify the cause of TSL in order to counteract before opting for an invasive treatment. In patient cases where restorative treatment is needed, a wide variety of treatment options and materials are available; these will be discussed in greater detail in the second part of this review [15, 16, 37].

## Conclusion

Tooth surface loss is a physiological process per se. Etiologically, it represents the sum of cumulative, multifactorial events which ultimately lead to irreversible loss of tooth substance. The factors which influence this process are not only exogenous, but also endogenous. Moreover, these factors have varying degrees of manifestation. Important parameters include patient age, enamel thickness, enamel hardness, saliva flow rate and composition, the pH value of the oral cavity, as well as, malpositions of teeth. Over time, various indices have been developed for risk assessment, among which, the Tooth-Wear-Index (TWI) and the Tooth Wear Evaluation System (TWES) have become well-established. When deciding if a prosthetic treatment should be performed, various factors such as the extent of TSL in relation to patient's age must be taken into account. The decision tree, which has been developed by the authors, is intended to

| Clinical signs of erosion  |   |
|--|---|
| According to Gandara and Truelove [17]   | According to Ganß and Lussi [18,20]   |
| <ul style="list-style-type: none"> <li>– “Cupping” of occlusal surfaces, (incisal grooving) and „crater” formation</li> <li>– Wear of non-occluding surfaces</li> <li>– Raised restorations</li> <li>– Broad concavities on the smooth surfaces of enamel</li> <li>– Increased incisal translucency</li> <li>– clean, non-tarnished appearance of amalgam restorations</li> <li>– persisting cervical enamel projections in the gingival sulcus</li> <li>– Hypersensitivity</li> </ul> | <ul style="list-style-type: none"> <li>– Rounding of cusps and fissures</li> <li>– Raised restorations</li> <li>– Flattening of elevations, formation of concavities in greater width than depth</li> <li>– persisting cervical enamel projections in the gingival sulcus</li> <li>– No plaque, discoloration or subgingival tartar</li> <li>– Smooth, silky shimmering or silky-glossy appearance, sometimes dull surface</li> </ul> |
| Clinical signs of attrition  |   |
| <ul style="list-style-type: none"> <li>– Glossy wear facets</li> <li>– Degree of enamel and dentin wear is comparable</li> <li>– Consistent wear on occluding surfaces</li> <li>– Possible fractures of cusps and restorations</li> </ul>  | <ul style="list-style-type: none"> <li>– Flat, smooth as glass</li> <li>– Matching features on antagonist teeth</li> </ul>  |
| Indentations in cheeks, tongue or lips*  |   |
| Clinical signs of abrasion   |   |
| <ul style="list-style-type: none"> <li>– Normally, cervical localization</li> <li>– Lesions are rather broad than deep</li> <li>– Mostly premolars and canines are affected</li> </ul>   |   |
| * Additional feature according to Wetselaar und Lobbezoo   |   |

**Table 4** With the help of the qualification module of the TWES, the dentist is able to recognize the problem of tooth surface loss [52].

help implement a systematic assessment of TSL in patients and to identify possible treatment options.

### Conflicts of interest

The authors declare that there is no conflict of interest within the meaning of the guidelines of the International Committee of Medical Journal Editors.

### References

1. Akgül HM, Akgül N, Karaoglanoglu S, Ozdabak N: A survey of the correspondence between abrasions and tooth brushing habits in Erzurum, Turkey. *Int Dent J* 2003; 53: 491–495
2. Al-Majed I, Maguire A, Murray JJ: Risk factors for dental erosion in 5–6 year old and 12–14 year old boys in Saudi Arabia. *Community Dent Oral Epidemiol* 2002; 30: 38–46

### Diagnostic modules – basic diagnostic for general practitioners

Module Qualification  
Module Quantification  
Module Quantification – clinical crown length  
Module recording of tooth wear (intra-oral photographs, dental casts)

### Diagnostic modules – extended diagnostics for specialists

Module Quantification– finer-grained occlusal/incisal and non-occlusal/non-incisal  
Module Oral History, questionnaires  
Module salivary analysis

### Treatment/management modules

Module complaints of the patient vs. reasons for clinician to start treatment/management  
Module start of treatment/management  
Module level of difficulty

**Table 5** Tooth Wear Evaluation System (TWES) [52]; with the TWES, it is possible to detect tooth surface loss (qualification) and to evaluate its severity (quantification). Additionally, possible causes can be diagnosed and a possible progression can be recorded.

(Fig. 1–5, Tab. 1–5; A. Roesner)

3. Al-Malik MI, Holt RD, Bedi R: Erosion, caries and rampant caries in preschool children in Jeddah, Saudi Arabia. *Community Dent Oral Epidemiol* 2002; 30: 16–23
4. Arnadóttir IB, Saemundsson SR, Holbrook WP: Dental erosion in Icelandic teenagers in relation to dietary and life-style factors. *Acta Odontol Scand* 2003; 61: 25–28
5. Bartlett D: A proposed system for screening tooth wear. *Br Dent J* 2010; 208: 207–209
6. Bartlett D, Dugmore C: Pathological or physiological erosion – is there a relationship to age? *Clin Oral Investig* 2008; 12 (Suppl 1): 31
7. Bartlett DW, Lussi A, West NX, Boucharde P, Sanz M, Bourgeois D: Prevalence of tooth wear on buccal and lingual surfaces and possible risk factors in young European adults. *Journal of Dentistry* 2013; 41: 1007–1013
8. Bergström J, Eliasson S: Cervical abrasion in relation to toothbrushing and periodontal health. *Scand J Dent Res* 1988; 96: 405–411
9. Bergström J, Lavstedt S: An epidemiologic approach to toothbrushing and dental abrasion. *Community Dent Oral Epidemiol* 1979; 7: 57–64
10. Caglar E, Kargul B, Tanboga I, Lussi A: Dental erosion among children in an Istanbul public school. *J Dent Child (Chic)* 2005; 72: 5–9
11. Dawson PE: Functional occlusion. From TMJ to smile design. Mosby, St. Louis, Mo. op. 2007
12. Deery C, Wagner ML, Longbottom C, Simon R, Nugent ZJ: The prevalence of dental erosion in a United States and a United Kingdom sample of adolescents. *Pediatr Dent* 2000; 22: 505–510
13. Dugmore CR, Rock WP: The prevalence of tooth erosion in 12-year-old children. *Br Dent J* 2004; 196: 279
14. Eccles JD: Tooth surface loss from abrasion, attrition and erosion. *Dent Update* 1982; 9: 373–374, 376–378, 380–381
15. Edelhoff D, Ahlers MO: Occlusal onlays as a modern treatment concept for the reconstruction of severely worn occlusal surfaces. *Quintessence Int* 2018; 49: 521–533
16. Edelhoff D, Schweiger J, Prandtner O, Trimpl J, Stimmelmayer M, Güth J-F: CAD/CAM splints for the functional and esthetic evaluation of newly defined occlusal dimensions. *Quintessence Int* 2017; 48: 181–191
17. Gandara BK, Truelove EL: Diagnosis and management of dental erosion. *J Contemp Dent Pract* 1999; 1: 16–23
18. Ganss C, Klimek J, Borkowski N: Characteristics of tooth wear in relation to different nutritional patterns including contemporary and medieval subjects. *Eur J Oral Sci* 2002; 110: 54–60
19. Ganss C, Klimek J, Giese K: Dental erosion in children and adolescents – a cross-sectional and longitudinal investigation using study models. *Community Dent Oral Epidemiol* 2001; 29: 264–271
20. Ganss C, Lussi A: Current erosion indices – flawed or valid? *Clin Oral Investig* 2008; 12 (Suppl 1): S1–3
21. Hand JS, Hunt RJ, Reinhardt JW: The prevalence and treatment implications of cervical abrasion in the elderly. *Gerodontology* 1986; 2: 167–170
22. Hebel KS, Graser GN, Featherstone JDB: Abrasion of enamel and composite resin by removable partial denture clasps. *J Prosthet Dent* 1984; 52: 389–397
23. Imfeld T: Dental erosion. Definition, classification and links. *Eur J Oral Sci* 1996; 104: 151–155
24. Jaeggi T, Lussi A: Prevalence, incidence and distribution of erosion. *Monogr Oral Sci* 2014; 25: 55–73
25. Jaeggi T, Schaffner M, Bürgin W, Lussi A: Erosionen und keilförmige Defekte bei Rekruten der Schweizer Armee. *Schweiz Monatsschr Zahnmed* 1999; 109: 1170–1182
26. Kanzow P, Wegehaupt FJ, Attin T, Wiegand A: Etiology and pathogenesis of dental erosion. *Quintessence Int* 2016; 47: 275–278
27. Kitchin PC: Cervical exposure and abrasion in human teeth for different age classes. *Science* 1941; 94: 65–66
28. Klimm W, Natusch I, Schreger E, Gorejwa R, Hamann V, Neugebauer A: Orale Gesundheit einer ostdeutschen Großstadtpopulation. Basisuntersuchungen der Dresdener Präventionsstudie an 2500 16– bis 35-jährigen. *Schweiz Monatsschr Zahnmed* 1991; 101: 1109–1118
29. Lambrechts P, Braem M, Vuylsteke-Wauters M, Vanherle G: Quantitative in vivo wear of human enamel. *J Dent Res* 1989; 68: 1752–1754
30. Lewis KJ, Smith BG: The relationship of erosion and attrition in extensive tooth tissue loss. Case reports. *Br Dent J* 1973; 135: 400–404
31. Lobbezoo F, Ahlberg J, Glaros AG et al.: Bruxism defined and graded: an international consensus. *J Oral Rehabil* 2013; 40: 2–4
32. Lobbezoo F, Ahlberg J, Raphael KG et al.: International consensus on the assessment of bruxism: Report of a work in progress. *J Oral Rehabil* 2018; 45: 837–844
33. Lohbauer U, Reich S: Antagonist wear of monolithic zirconia crowns after 2 years. *Clin Oral Investig* 2017; 21: 1165–1172
34. Loomans B, Opdam N, Attin T et al.: Severe tooth wear: European consensus statement on management guidelines. *J Adhes Dent* 2017; 19: 111–119
35. Mehta SB, Banerji S, Millar BJ, Suarez-Feito J-M: Current concepts on the management of tooth wear: part 1. Assessment, treatment planning and strategies for the prevention and the passive management of tooth wear. *Br Dent J* 2012; 212: 17–27
36. Behr M, Fanghänel J, Rauch A: Changing the bite position on a patient with tooth hard substance loss. *Dtsch Zahnärztl Z Int* 2020; 1: 3–7
37. Muts E-J, van Pelt H, Edelhoff D, Krejci I, Cune M: Tooth wear: a systematic review of treatment options. *J Prosthet Dent* 2014; 112: 752–759
38. Natusch I, Klimm W: Chronischer Zahnhartsubstanzverlust im frühen und mittleren Erwachsenenalter. *Zahn Mund Kieferheilkd Zentralbl* 1989; 77: 123–127
39. Peres KG, Armênio MF, Peres MA, Traebert J, Lacerda JT de: Dental erosion in 12-year-old schoolchildren: a cross-sectional study in Southern Brazil. *Int J Paediatr Dent* 2005; 15: 249–255
40. Pindborg JJ: Pathology of the dental hard tissues. Munksgaard, Copenhagen 1970
41. Preston AJ, Barber MW: The ageing UK population—considerations for the restorative dentist. *Int Dent J* 2007; 57: 423–428
42. Radentz WH, Barnes GP, Cutright DE: A survey of factors possibly associated with cervical abrasion of tooth surfaces. *J Periodontol* 1976; 47: 148–154
43. Ray DS, Wiemann AH, Patel PB, Ding X, Kryscio RJ, Miller CS: Estimation of the rate of tooth wear in permanent incisors: a cross-sectional digital radiographic study. *J Oral Rehabil* 2015; 42: 460–466
44. Rodriguez JM, Austin RS, Bartlett DW: In vivo measurements of tooth wear over 12 months. *Caries Res* 2012; 46: 9–15
45. Salas MMS, Nascimento GG, Huysmans MAC, Demarco FF: Estimated prevalence of erosive tooth wear in permanent teeth of children and adolescents: an epidemiological systematic review and meta-regression analysis. *J Dent* 2015; 43: 42–50
46. Salas MMS, Vargas-Ferreira F, Ardenghi TM, Peres KG, Huysmans M-CD, Demarco FF: Prevalence and associated factors of tooth erosion in 8–12-year-old Brazilian schoolchildren. *J Clin Pediatr Dent* 2017; 41: 343–350



47. Schiffner U, Micheelis W, Reich E: Erosionen und keilförmige Defekte bei deutschen Erwachsenen und Senioren. *Dtsch Zahnärztl Z* 2002; 57: 102–106
48. Smith BG, Knight JK: An index for measuring the wear of teeth. *Br Dent J* 1984; 156: 435–438
49. The glossary of prosthodontic terms: Ninth Edition. *J Prosthet Dent* 2017; 117: e1–e105
50. Truin GJ, van Rijkom HM, Mulder J, van't Hof MA: Caries trends 1996–2002 among 6- and 12-year-old children and erosive wear prevalence among 12-year-old children in The Hague. *Caries Res* 2005; 39: 2–8
51. Verger-Pratoucy: La carie dentaire existait-elle chez l'homme du Paléolithique ? *bspf* 1967; 64: 91–95
52. Wetselaar P, Lobbezoo F: The tooth wear evaluation system: a modular clinical guideline for the diagnosis and management planning of worn dentitions. *J Oral Rehabil* 2016; 43: 69–80
53. Wetselaar P, Vermaire JH, Visscher CM, Lobbezoo F, Schuller AA: The prevalence of tooth wear in the Dutch adult population. *Caries Res* 2016; 50: 543–550
54. Wiegand A, Begic M, Attin T: In vitro evaluation of abrasion of eroded enamel by different manual, power and sonic toothbrushes. *Caries Res* 2006; 40: 60–65
55. Wiegand A, Müller J, Werner C, Attin T: Prevalence of erosive tooth wear and associated risk factors in 2–7-year-old German kindergarten children. *Oral Dis* 2006; 12: 117–124
56. Williams D, Croucher R, Marcenes W, O'Farrell M: The prevalence of dental erosion in the maxillary incisors of 14-year-old schoolchildren living in Tower Hamlets and Hackney, London, UK. *Int Dent J* 1999; 49: 211–216



(Photo: A. Roesner)

---

**DR. ANUSCHKA  
JOSEPHINE ROESNER**  
Department of Dental, Oral and  
Maxillofacial Medicine, Clinic for  
Prosthetic Dentistry  
Hugstetter Str. 55  
79106 Freiburg, Germany  
anuschka.roesner  
@uniklinik-freiburg.de

Friedrich Müller, Janine Müller, Maximilian Schmidt-Breitung, Marcus Horn, Philipp Merkt, Viktor Foltin

# Formation and detection of titanium release during implant insertion

## An ex-vivo study in human donor bone

**Introduction:** In orthopaedic wear of titanium components of endo-prosthesis is an increasing problem, especially in hip prosthesis. Inflammation and tissue degeneration make surgical revisions risky and unfavourable. As approximately one million dental implants are inserted every year in Germany alone, side-effects like multi-etiological periimplantitis become more frequent. This study is motivated by the need to prevent disturbance of osseointegrative healing of implants after insertion due to phagocytosis of nanoparticles. That may cause activation of prolonged tissue inflammation with subsequent higher risk of implant loss or activation of multi-etiological peri-implantitis.

**Methods:** Human donor bone of D1 quality (Os femoris) was cut in appropriate size and 6 Conelog implants (Camlog) of 3,8 mm diameter (3 implants with a microrough surface and 3 of machined surface) together with 6 Thommen implants of 4 mm diameter (3 implants with a microrough surface and 3 of machined surface) were inserted with a maximum torque of 20 Ncm. Afterwards the bone cavity was opened and investigated for titanium wear. Scanning electron microscopy (SEM) and energy dispersive X-ray spectroscopy (EDX) was used to perform detection of nanoparticles. Statistical analysis was performed using ANOVA.

**Results:** The occurrence of titanium was very limited. Therefore, the size of particles could not be measured. Overall 150 sites in 12 implants have been analyzed (average of 12.5 sites per implant). In total, the measurements of 37 sites produced positive detection of small traces of titanium (0.016–0.364 wt.%). No differences have been found regarding the surface morphology or type of manufacturer. Remarkably there are differences in the sub-groups. There is a statistically significant difference between machined and microrough surfaces in Conelog implants ( $p = 0.0161$ ). No difference has been found in machined and microrough Thommen implants ( $p = 0.696$ ).

**Summary and Conclusion:** This unpretentious investigation actually shows that wear of titanium can occur in human bone simply due to implant insertion. Though wear is extremely limited in human donor bone and of little clinical relevance. Further long-term investigations regarding aspects of bio-tribocorrosion in dental implants are needed. The risk of prolonged inflammation during osseointegration is considered to be extremely low and therefore titanium implants are a safe and predictable therapeutic option.

**Keywords:** titanium; wear; particles; human donor bone; bio-tribocorrosion

Zahnarztpraxis Dres. Müller+, Tannenring 76, 65207 Wiesbaden: Dr. Friedrich Müller M.Sc. M.Sc., Dr. Janine Müller, Dr. Maximilian Schmidt-Breitung MBA, Marcus Horn, Dr. Philipp Merkt M.Sc., Doc. Viktor Foltin PhD

St. Elisabeth University Bratislava, Slovakia; Johannes Gutenberg-University Mainz, Germany: Dr. Friedrich Müller M.Sc. M.Sc., Dr. Maximilian Schmidt-Breitung MBA, Marcus Horn, Dr. Philipp Merkt M.Sc., Doc. Viktor Foltin PhD

Translation from German: Yasmin Schmidt-Park

**Citation:** Müller F, Müller J, Schmidt-Breitung M, Horn M, Merkt P, Foltin V: Formation and detection of titanium release during implant insertion. An ex-vivo study in human donor bone. *Dtsch Zahnärztl Z Int* 2021; 3: 158–166

**Peer-reviewed article:** submitted: 14.04.2020, revised version accepted: 30.07.2020

**DOI.org/10.3238/dzz-int.2021.0018**

### Introduction

This study investigates wear of dental titanium implants after insertion in human donor bone of D1 quality. Wear particles can be phagozytosed by macrophages and therefore promote prolonged inflammation and compromise osseointegration. Nanoparticles are ubiquitous in our daily life and can be found in dental materials, too. Schmalz et al. were working on an overview of nanoparticles in dentistry [36, 37]. They found that nanoparticles can be produced through wear of restorative materials (e.g. ceramics, metals) or can be released from dental implants and that they might be able to enter the biological environment when restorations or implants are being removed from the oral cavity.

A recently published review on corrosion and wear of titanium-based dental implant connections showed that the problem of nanoparticles reached scientific evidence [2]. This scoping review of Apaza-Bedoya et al. showed that degradation at the implant-abutment connection due to wear and tribological processes are among the serious problems in dentistry. They stated that wear and corrosion debris (e.g. ions and micro- and nanoparticles) that are released into the biological surrounding tissue can stimulate peri-implantitis that in turn leads to pathologic bone resorption.

A review of the literature of titanium toxicity by Kim et al. revealed several toxic and allergic reactions

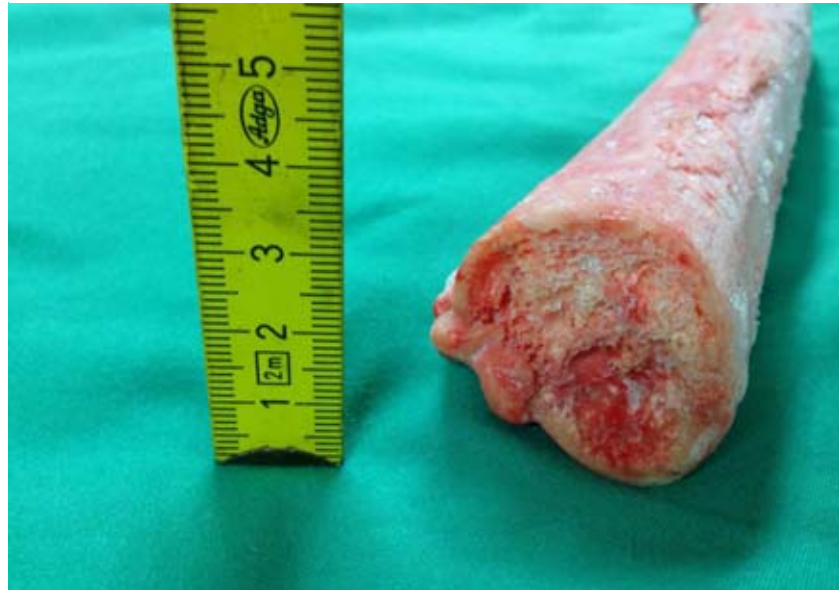

Figure 1 Deep frozen human femur shaft




Figure 2 Human femur shaft with inserted implants





Figure 3 Canelog Implants machined (above) and microrough surface (below)



**Figure 4** Thommen Implants machined (above) and microrough surface (below)

[18]. The most used titanium material is TiO<sub>2</sub> powder that can be found in various applications such as paints, food products, drugs and cosmetics [9, 42] followed by increasing concerns of its influence on our environment and human health [3,13, 54]. Toxicity of TiO<sub>2</sub> nanoparticles in rodents has been shown in many studies [5, 6, 8, 11, 14, 41, 48, 50, 51, 57].

Although titanium and its alloys are the most biocompatible material, wear and corrosion can still occur in extreme environment and conditions (e.g. low pH and high concentrations of fluoride) [19, 29, 44]. Schiff et al. found that fluorine ions can even de-

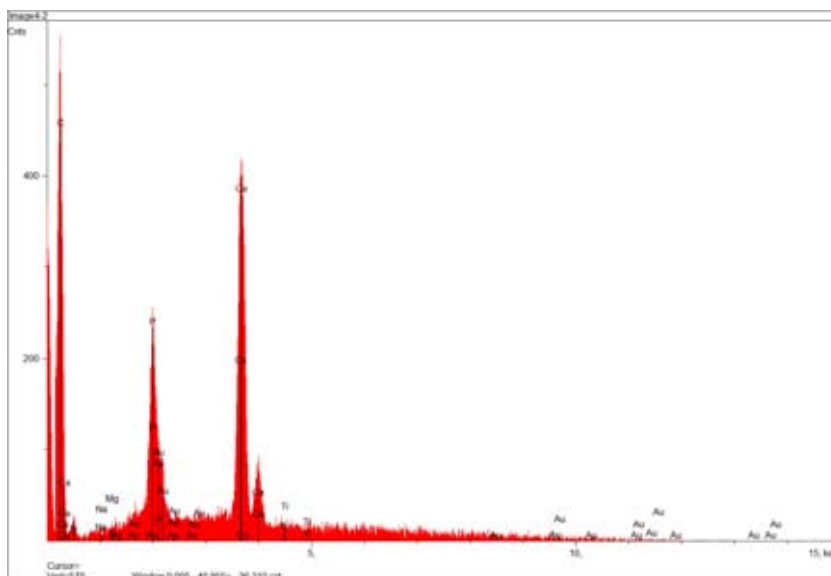
stroy the titanium passive layer [35]. Wachi et al. found that titanium ions might be responsible for deteriorating effects of peri-implant mucositis [49]. Olmedo et al. found macrophages loaded with titanium particles as an indicator of corrosion processes of failed implants in human peri-implant soft tissue [27]. Using the exfoliative cytological test to observe particles inside and outside of epithelial cells and macrophages, studies from Olmedo and Penmetsa found significant higher rates of implant particles in patients with peri-implantitis [28, 30]. Wilson et al. discussed three possibilities that can cause presence of titanium particles:

releasing due to friction between implant and bone during insertion, wear during debridement at maintenance procedures, and corrosion [53]. The damage of the surface of the implant due to particle release during insertion was observed by Senna et al. [40]. On the other hand Addison et al. proposed localized surface corrosion and micro-motions to be responsible for titanium particles and found wear debris unlikely to be the major contributor of particles [1].

Own investigations regarding torque dependent insertion depth of dental titanium implants in artificial bone showed that implants are stressed during insertion with up to 70 Ncm of torque [24]. Wear of dental titanium implants in artificial bone was subsequently investigated [25]. It has been shown that in artificial bone of D1 quality wear was very limited with only 0.17 to 0.47 atomic percent and with particles of 100 to 150 nm in size. This present study was aimed to re-check the previous findings under more clinically relevant conditions in human donor bone of D1 quality.

## Methods

Human donor bone was provided by the Dr. Senckenberg Anatomical Institute of the University Hospital of the Goethe University Frankfurt (No. 65300308–2018–01). The donor bone encompassed a deep frozen femur bone shaft (Os femoris) of 25 cm in length and 3.5 cm in width (Fig. 1).



**Figure 5** EDX-spectrum of sample 7

The shaft was split longitudinally and afterwards fixated by screws crossways. By this, the bone cavity could be opened after implant setting without bringing stress to the implant surface or the cavity walls (Fig. 2). Afterwards implants have been inserted into the cut of the lengthwise separation. Due to the restricted length of the bone shaft the limited number of only 12 implants could be inserted with sufficient space between the implants. This fact enabled the placement of only 3 implants of each group. Six Conelog implants (Camlog) of 3,8 mm diameter (3 implants with microrough surface and 3 with machined surface) together with 6 Thommen implants of 4 mm diameter (3 implants with microrough surface and 3 with machined surface) were inserted with a maximum torque of 20 Ncm and sufficient water cooling to prevent heat exhaustion. In both systems standard stainless steel drills were used meeting the recommendations of the drilling protocols. A previous analysis of an unused stainless steel drill for possible titanium sources showed a very homogeneous composition of the drill surface. The spectra gave a slight indication of the presence of titanium on the drill surface, but the titanium signal of the EDX analysis was not greater than its statistical error. Therefore, titanium was only present in traces in the drill material. To obtain sample size small enough for the SEM vacuum chamber each implant cavity was cut into 1.5 cm pieces (Fig. 3 and 4). Implant and bone units have been dried in an exsiccator for 14 days to ensure SEM imaging. To obtain suitable electrical conductivity of the donor bone, sputtering of these samples was necessary. The device used was Edwards S150B Sputter Coater. Sputter gas was Argon to provide a suitable source of ions for efficient target bombardment. Target material was gold (negative cathode) having favourable electrical conduction features. Samples have been sputtered for one minute at 1kV voltage and 100 mbar pressure. Additional advantages of sputtering was reduction of scanning electron microscope beam damage to the bone, reduction of sample charging,

| Sample | Description              | Sites per sample | Mean (Ti unit wt.%) | SD    | min   | max   |
|--------|--------------------------|------------------|---------------------|-------|-------|-------|
| 1      | Canelog osseointegrative | 20 (4 positive)  | 0.045               | 0.077 | 0.006 | 0.364 |
| 2      | Canelog osseointegrative | 12 (4 positive)  | 0.049               | 0.041 | 0.009 | 0.142 |
| 3      | Canelog osseointegrative | 16 (1 positive)  | 0.033               | 0.024 | 0.000 | 0.097 |
| 4      | Canelog machined         | 6 (0 positive)   | 0.014               | 0.010 | 0.003 | 0.029 |
| 5      | Canelog machined         | 4 (2 positive)   | 0.021               | 0.023 | 0.005 | 0.055 |
| 6      | Canelog machined         | 2 (0 positive)   | 0.001               | 0.001 | 0.001 | 0.002 |
| 7      | Thommen osseointegrative | 15 (6 positive)  | 0.058               | 0,025 | 0.031 | 0.116 |
| 8      | Thommen osseointegrative | 15 (5 positive)  | 0.032               | 0.025 | 0.004 | 0.094 |
| 9      | Thommen osseointegrative | 15 (2 positive)  | 0.029               | 0.019 | 0.000 | 0.059 |
| 10     | Thommen machined         | 15 (6 positive)  | 0.037               | 0.016 | 0.004 | 0.064 |
| 11     | Thommen machined         | 15 (3 positive)  | 0.074               | 0.064 | 0.000 | 0.252 |
| 12     | Thommen machined         | 15 (4 positive)  | 0.029               | 0.018 | 0.002 | 0.060 |

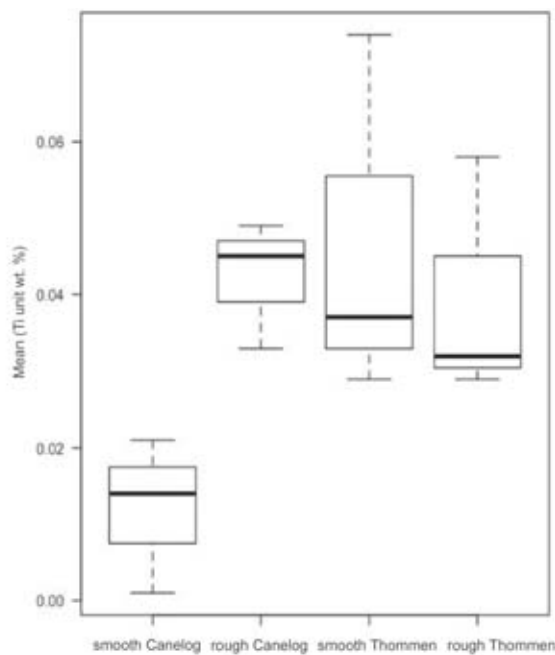
**Table 1** Detection of traces of titanium on Canelog and Thommen implants (unit weight %)

improvement of secondary electron emission as well as improvement of edge resolution. Energy dispersive X-ray spectroscopy (EDX) is a measurement method in the field of material testing and analytics. The electron beam of specific energy is used to stimulate atoms of a certain sample that thereupon emit a characteristic X-ray radiation. Each element emits its specific and distinct X-ray spectrum. In this way the elementary composition of the samples surface can be analyzed. Statistical analysis was performed using one- and two-factor analysis of variance (ANOVA).

The output of the EDX-software of a concentration value of a specific element cannot be mistaken with a positive detection of the analyzed el-

ement even if the nominal value is non-zero. In fact the interpretation of the value is based on statistical tests. That means that with a certain probability the real and unknown result of titanium is located around the given value. For this reason the software also shows the standard deviation (SD) in addition to the measured nominal count. If one chooses the single standard deviation the probability that the real and unknown value of titanium lies within the standard deviation is 68.3 %. If one doubles the standard deviation (2SD) the probability raises to 95.5 %. Nominal values less than the single or double standard deviation indicate a corresponding high probability that the real and unknown titanium value is zero (even the value itself is not

(Fig. 1–6, Tab. 1: F. Müller)



**Figure 6** Box-Plot

zero). Actually in analytical practice this in turn means that titanium could not be detected seriously.

## Results

In total 12 implants were inserted into human donor bone, 6 Canelog implants and 6 Thommen implants of which 3 of each manufacturer have had a microrough osseointegrative surface and 3 of each group a machined surface. SEM investigation and EDX analyses have been performed on various sites of the crestal parts of each implant. Overall 150 sites in 12 implants have been analyzed (average of 12.5 sites per implant). In total the measurements of 37 sites (24.55 %) produced positive detection of little traces of titanium (0.016–0.364 wt.%).

Canelog implants with microrough surface produced 9 of 48 positive sites (18.75 % of 48 sites) and Canelog machined surface implants produced 2 of 12 positive sites (16.66 % of 12 sites). Thommen implants with microrough and machined surface produced 13 of 45 positive sites each (28.88 % of 45 sites) (Tab. 1 and Fig. 5).

Univariate statistical analyses showed no differences regarding the surface morphology ( $p = 0.326$ ) or type of implant manufacturer

( $p = 0.167$ ). Bivariate testing including both factors (surface and manufacturer) showed a marginal significant difference ( $p = 0.0755$ ) indicating that there are differences in the sub-groups. There is a statistically significant difference between machined and microrough surface in Canelog implants ( $p = 0.0161$ ) as well as a difference between machined surface implants of Thommen and Canelog ( $p = 0.0826$ ). No difference has been found in machined and microrough Thommen implants ( $p = 0.696$ ). Also no statistical significant difference has been found between microrough surface implants of Thommen and Camlog ( $p = 0.81$ ) (Fig. 6).

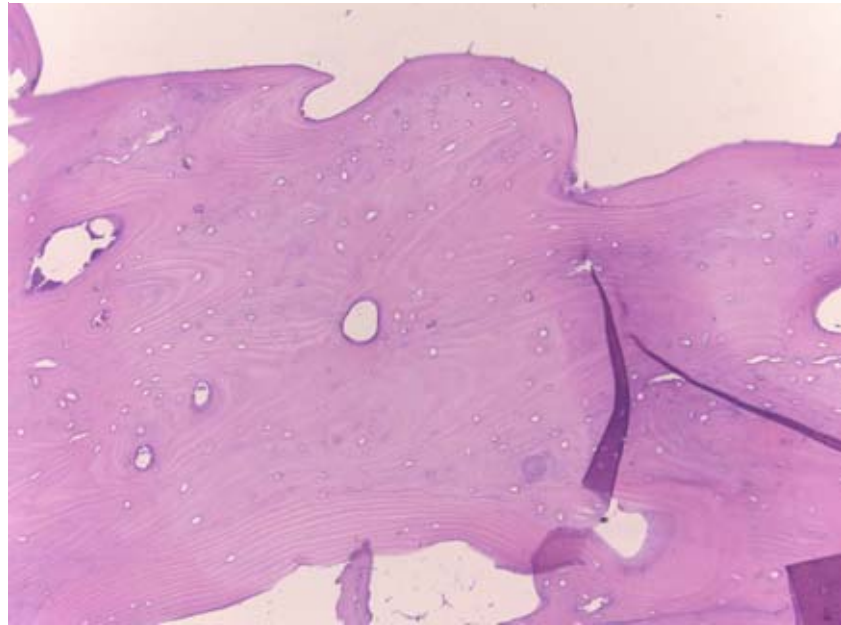
## Discussion

This present study indicates that the investigated titanium implants are only very little abrasive. The most abrasive resistant surface was found in Canelog implants with machined surfaces. Nearly similar abrasive behavior was found in both Thommen surfaces together with microrough Canelog implants. Results of a previously published investigation of Canelog implants have shown a ten times higher abrasion behavior in artificial bone compared to human donor bone (up to 0.46 wt.% of tita-

nium particles) [25]. This difference might be determined due to the properties of the artificial bone blocks (Sawbone, 40 pcf) that were used previously. These solid blocks were completely of compacta bone quality while human donor bone was of spongy medullary consistency in the center of the sample with an outer rim of compacta structure of only 2–3 mm. This compacta structure was found to be strong enough to obtain primary stability for all implants but lacks standardization (Fig. 7). On the one hand this standardization was given sufficiently in the artificial bone model that was lacking clinical needs on the other hand. The results show that microrough surfaces are more abrasive than machined surfaces due to the micro-retentive pattern after sand blasting and acid etching to ensure osseointegration. Therefore, it is no wonder that Canelog's machined surface is clearly less abrasive than its microrough. Remarkably this difference cannot be found in Thommen's surface where machined is comparable abrasive to microrough. Another interesting fact is that both Canelog and Thommen microrough surfaces are similar in abrasive behavior. So no superiority of one manufacturer over the other can be concluded.

In comparison Sridhar et al. did not find traces of titanium of 16 Straumann implants in artificial bone of 10, 20, 30 and 40 pcf Sawbone blocks [43]. The examination method used by Sridhar et al. (light microscopy and X-ray diffractometry) can be regarded as a potential cause for the failure to successfully detect titanium nanoparticles, since light microscopy does not achieve magnifications as high as those with a scanning electron microscope and therefore titanium particles that are scattered cannot be reliably detected in the nanometer range. In contrast another in-vitro study found reduced oxide layer of dental implants after insertion and pullout tests using microstructural analysis [47]. Deppe et al. found that the mean surface roughness, mean maximal roughness and the developed surface area ratio were highly modified after implant placement into bone using an in-

vitro study model [10]. Three different implant systems with different surface roughness have been inserted into Class I porcine bone. It was found that in the acid-etched implant surface the mean surface roughness decreased especially in the apical region (-10.4 %) compared to large-grit-blasted implant surface. In anodized implants the mean surface roughness increased (+5.7 %) indicating a destruction of the surface. Meyer et al. confirmed contamination of peri-implant bone in minipigs after placement of titanium implants by using scanning electron microscopy [20]. Results revealed titanium particles especially in the crestal part of the bone and around implants with rough surfaces. Wear was found to be less important on surfaces with a roughness of 1.5  $\mu\text{m}$  and 0.4  $\mu\text{m}$ . Recently, these findings have been confirmed by Suarez-Lopez del Amo et al. [45]. The authors tested 5 different implant surfaces (dual-acid etched, fluoride-modified, sandblasted large-grit acid-etched/hydrophilic sandblasted large-grit acid-etched, phosphate-enriched titanium oxide, and large grit). Results showed round or small angular elongated titanium debris in the crestal part of the osteotomy site. In contrast these findings could not have been confirmed by another group of researchers [52]. After insertion of implants in rabbit tibia Wennerberg et al. did not find an association between implant roughness and ion release. Surgical interventions of advanced peri-implantitis often require the removal of macroscopic implant threads for surface smoothing [39]. Various instruments have been tested to achieve a new plain implant surface [7, 32]. Schwarz et al. clearly demonstrated titanium contamination of neighboring bone and connective tissue after this implantoplasty resulting in a localized mixed chronic inflammatory cell infiltrate dominated by plasma cells and lymphocytes [38]. Actually, the authors did not report any clinical adverse effects related to the presence of those titanium particles. Peri-implantitis treatment in all its aspects is yet insufficiently predictable [16] compared



(Fig. 7: Dr. Manuel Niederhagen, OptiPath Frankfurt/M.)

**Figure 7** Histological verification of compacta

to periodontitis treatment [22] and therefore scientific evidence is heterogeneous [23]. That's why knowledge of every part of the etiology of peri-implantitis is mandatory. A contrary assessment was recently done by Petterson et al. [31]. In order to investigate the influence of titanium on peri-implant inflammation, 13 patients with peri-implantitis (test group) and 11 patients with periodontitis (control group) have been included in this study. In patients with peri-implantitis, significantly higher titanium values have been measured than in the control group. They concluded that titanium can potentially worsen inflammation symptoms and make treatment prognosis worse. In order to investigate the possible influence of released components of dental implants as a result of peri-implant therapy or the corrosion of the titanium surface, Noronha Oliveira et al. carried out a systematic literature search in the Pubmed database [26]. 79 articles have been included in the analysis. It has been observed that metal ions and metal particles activate osteoclasts, pro-inflammatory cells and cytokines in the peri-implant tissues. Degenerative changes have been found in macrophages and neutrophils after the phagocytosis of titanium microparticles. Degradation

products that result from the degradation of dental implants have a cytotoxic and genotoxic potential for peri-implant tissues. The quantity and the physicochemical properties of the degradation products determine the extent and damage to the peri-implant tissues. Safiotti et al. performed a cross-sectional study on peri-implantitis and bacterial load [34]. They believe that in peri-implantitis bacteria not only trigger an immune response from the host, but also lead to electrochemical changes and corrosion of the titanium surface, which can result in an increased inflammatory process. In order to investigate the influence of the released titanium on the peri-implant inflammation, 20 plaque samples of 30 patients have been taken and analyzed. Significantly higher titanium values have been measured in implants with peri-implantitis than in healthy peri-implant conditions.

Investigations on orthopedic prosthesis revealed the underlying patho-physiologic mechanism resulting in bone and implant loss [12, 15]. Titanium alloy increases the release of inflammation-inducing mediators (Prostaglandin E2, Interleukin-1, Interleukin-6, TNF) [15]. Human monocytes released more inflammatory mediators due to Ti-Al-V in comparison to titanium-aluminum-niobium

(Ti-Al-Nb) [33]. Yu et al. investigated synergistic effects of H<sub>2</sub>O<sub>2</sub> and albumin on corrosion behavior of titanium alloy (Ti6Al4V) in physiological saline [56]. A much higher rate of metal release was observed in both media (albumin and H<sub>2</sub>O<sub>2</sub>) compared to the presence of H<sub>2</sub>O<sub>2</sub> and albumin alone. Furthermore Zhang et al. showed that albumin suppressed the dissolution of Ti6Al4V in the presence of H<sub>2</sub>O<sub>2</sub> at short periods (< 24 h), but after longer periods the dissolution rate increased. That might be attributed to the reduction of the oxide film of titanium [58].

Allergic reactions against titanium are supposed to be impossible and mostly intolerance or hypersensitive reactions against titanium are wrongly diagnosed as allergy. There are reports of hypersensitive reactions like erythema, eczema, pain, necrosis and bone loss after insertion of titanium implants [18] but allergic reactions were reported by Hosoki et al. in 2016 [17] and Thomas et al. [46]. Berglund and Carlmark performed a study on systemic disease of titanium (known as “yellow nail syndrome”) using energy-dispersive X-ray fluorescence (EDXRF) in the nails of 30 patients and found high concentrations of titanium [4].

A recently published comprehensive critical review concluded that titanium particles are being released from titanium surfaces because of mechanical wear, contact to chemical agents, and interaction with substances produced by adherent biofilm and inflammatory cells [21]. The authors found that wear, corrosion, titanium particles, inflammation, and microorganisms take part in a complex host response to foreign bodies. Environmental factors together with corrosion and wear lead to material degradation called tribo-corrosion. Released titanium particles disturb cell function, surface disruption changes protein absorption, bacterial load causes inflammation, inflammation changes pH that in turn alters the composition of biofilms that in turn causes again corrosion. So multiple feedback loops compromise the peri-implant hard and soft tissue. Mombelli et al. finally concluded nicely that “biofilms cause

inflammation, and biofilms cause corrosion”. In summary this conclusion can be broadened to the full aspect of the scientific field of bio-tribocorrosion “insertion causes wear, wear causes inflammation, wear causes corrosion, corrosion causes inflammation, inflammation causes corrosion, biofilms cause inflammation, biofilms cause corrosion” [55].

Nevertheless, the fact that implant insertion causes very limited wear as shown is only a small aspect in the etiology of multifactorial peri-implantitis and its clinical relevance compared to bacterial issues and immune response might be inferior. Still clinicians should keep this aspect in mind to promote and augment adequate options for their patients during primary (implant insertion) and secondary (peri-implantitis treatment) implant surgery.

### Acknowledgement

The present study was financially supported by DGZMK scientific funds (15.000 Euro), the Oral Reconstruction Foundation (3.080 Euro) and Thommen (2.260 Euro). Thanks go to Dr. Christian Hof and Dr. Hendrik Reers for their help with realization of this study and evaluation of the data.

### Conflicts of interest

The authors declare that there is no conflict of interest as defined by the guidelines of the International Committee of Medical Journal Editors.

### References

1. Addison O, Davenport AJ, Newport RJ et al.: Do ‘passive’ medical titanium surfaces deteriorate in service in the absence of wear? *J R Soc Interface* 2012; 9: 3161–3164
2. Apaza-Bedoya K, Tarce M, Benfatti CAM et al.: Synergistic interactions between corrosion and wear at titanium-based dental implant connections: A scoping review. *J Periodont Res* 2017; 52: 946–954
3. Batt J, Milward M, Chapple I, Grant M, Roberts H, Addison O: TiO<sub>2</sub> nanopar-

ticles can selectively bind CXCL8 impacting on neutrophil chemotaxis. *Eur Cell Mater* 2018; 35: 13–24

4. Berglund F, Carlmark B: Titanium, sinusitis, and the yellow nail syndrome. *Biol Trace Elem Res* 2011; 143: 1–7
5. Bermudez E, Mangum JB, Asgharian B et al.: Long-term pulmonary responses of three laboratory rodent species to subchronic inhalation of pigmentary titanium dioxide particles. *Toxicological Sciences* 2002; 70: 86–97
6. Bermude E, Mangum JB, Wong BA et al.: Pulmonary responses of mice, rats, and hamsters to subchronic inhalation of ultrafine titanium dioxide particles. *Toxicological Sciences* 2004; 77: 347–357
7. Bollen CM, Papaioanno W, Van Eldere J, Schepers E, Quirynen M, Van Steenberghe D: The influence of abutment surface roughness on plaque accumulation and peri-implant mucositis. *Clin Oral Implants Res* 1996; 7: 201–211
8. Chen J, Dong X, Zhao J, Tang G: In vivo acute toxicity of titanium dioxide nanoparticles to mice after intraperitoneal injection. *J Appl Toxicol* 2009; 29: 330–337
9. Chen XX, Cheng B, Yang YX et al.: Characterization and preliminary toxicity assay of nano-titanium dioxide additive in sugar-coated chewing gum. *Small* 2013; 9: 1765–1774
10. Deppe H, Wolff C, Bauer F, Ruthenberg R, Sculean A, Mücke T: Dental implant surfaces after insertion in bone: an in vitro study in four commercial implant systems. *Clin Oral Investig* 2018; 22: 1593–1600
11. Fabian E, Landsiedel R, Ma-Hock L, Wiench K, Wohlleben W, Van Ravenzwaay B: Tissue distribution and toxicity of intravenously administered titanium dioxide nanoparticles in rats. *Arch Toxicol* 2008; 82: 151–157
12. Furrer S, Scherer Hofmeier K, Grize L, Bircher AJ: Metal hypersensitivity in patients with orthopaedic implant complications – a retrospective clinical study. *Contact dermatitis* 2018; 79: 91–98
13. Grande F, Tucci P: Titanium dioxide nanoparticles: a risk for human health? *Mini Reviews in Medicinal Chemistry* 2016; 16: 762–769
14. Hamilton RF, Wu N, Porter D, Buford M, Wolfarth M, Holian A: Particle length-dependent titanium dioxide nanomaterials toxicity and bioactivity. *Particle and Fibre Toxicology* 2009; 6: 35
15. Haynes DR, Rogers SD, Hay S, Percy MJ, Howie DW: The differences in toxicity and release of bone-resorbing mediators. *J Bone Joint Surg Am* 1993; 75: 825–834
16. Hoffmann T, Müller J, Gehrke P, Müller F: Antimicrobial photodynamic



- therapy in peri-implantitis treatment – a systematic review. *Int Poster J Dent Oral Med* 2015; 17: No. 4, Poster 929
17. Hosoki M, Nishigawa K, Miyamoto Y, Ohe G, Matsuka Y: Allergic contact dermatitis caused by titanium screws and dental implants. *J Prosthodont Res* 2016; 60: 213–219
18. Kim TK, Eo MY, Nguyen TTH, Kim SM: General review of titanium toxicity. *Int J Implant Dent* 20219; 5: 10
19. Martini D, Fini M, Franchi M et al.: Detachment of titanium and fluorohydroxyapatite particles in unloaded endosseous implants. *Biomaterials* 2003; 24: 1309–1316
20. Meye U, Bühner M, Büchter A, Kruse-Lösler B, Stamm T, Wiesmann HP: Fast element mapping of titanium wear around implants of different surface structures. *Clin Oral Implants Res* 2006; 17: 206–211
21. Mombelli A, Hashim D, Cionca N: What is the impact of titanium particles and biocorrosion on implant survival and complications? A critical review. *Clin Oral Implants Res* 2018; 29: 37–53
22. Müller F, Müller J, Noack B, Hoffmann T: Adjunctive antimicrobial photodynamic therapy in chronic periodontitis treatment – a meta-analysis. *Int Poster J Dent Oral Med* 2015; 17: No. 4, Poster 933
23. Müller F: Comparison of clinical evidence of antimicrobial photodynamic therapy in periodontitis and peri-implantitis treatment. *Int Poster J Dent Oral Med* 2016; 18: No. 2, Poster 994
24. Müller F, Müller J: Drehmomentabhängige Insertionstiefe in D1-Kunstknöchel In-vitro-Untersuchung an Conelog Implantaten. *Implantologie* 2016; 24: 327–333
25. Müller F, Müller J, Schmidt-Breitung M: Entstehung und Nachweis von Nanopartikeln durch Abrieb von Titanimplantaten. *Dtsch Zahnärztl Z* 2019; 74: 36–43
26. Noronha Oliveira M, Schunemann WVH, Mathew MT et al.: Can degradation products released from dental implants affect peri-implant tissues? *J Periodontol Res* 2018; 53: 1–11
27. Olmedo DG, Paparella ML, Brandizzi D, Cabrini RL: Reactive lesions of peri-implant mucosa associated with titanium dental implants: a report of 2 cases. *Int J Oral Maxillofac Surg* 2010; 39: 503–507
28. Olmedo DG, Nalli G, Verdú S, Paparella ML, Cabrini RL: Exfoliative cytology and titanium dental implants: a pilot study. *J Periodontol* 2013; 84: 78–83
29. Peñarrieta-Juanito G, Sordi MB, Henriques B et al.: Surface damage of dental implant systems and ions release after exposure to fluoride and hydrogen peroxide. *J Periodontol Res* 2019; 54: 46–52
30. Penmetsa SLD, Shah R, Thomas R, Kumar ABT, Gayatri PSD, Mehta DS: Titanium particles in tissues from peri-implant mucositis: an exfoliative cytology-based pilot study. *J Indian Soc Periodontol* 2017; 21: 192
31. Pettersson M, Pettersson J, Johansson A, Molin Thorén M: Titanium release in peri-implantitis. *J Oral Rehabil* 2019; 46: 179–188
32. Ramel CF, Lüssi A, Özcan M, Jung RE, Hämmerle CH, Thom DS: Surface roughness of dental implants and treatment time using six different implantoplasty procedures. *Clin Oral Implants Res* 2016; 27: 776–781
33. Rogers SD, Howie DW, Graves SE, Percy MJ, Haynes DR: In vitro human monocyte response to wear particles of titanium alloy containing vanadium or niobium. *J Bone Joint Surg Br* 1997; 79: 311–315
34. Safioti LM, Kotsakis GA, Pozhitkov AE, Chung WO, Daubert DM: Increased levels of dissolved titanium are associated with peri-implantitis – a cross-sectional study. *J Periodontol* 2017; 88: 436–442
35. Schiff N, Grosogoeat B, Lissac M, Dalard F: Influence of fluoride content and pH on the corrosion resistance of titanium and its alloys. *Biomaterials* 2002; 23: 1995–2002
36. Schmalz G, Hickel R, van Landuyt KL, Reichl FX: Nanoparticles in dentistry. *Dent Mater* 2017; 33: 1298–1314
37. Schmalz G, Hickel R, van Landuyt KL, Reichl FX: Scientific update on nanoparticles in dentistry. *Int Dent J* 2018; 68: 299–305
38. Schwarz F, Sahn N, Iglhaut G, Becker J: Impact of the method of surface debridement and decontamination on the clinical outcome following combined surgical therapy of peri-implantitis: a randomized controlled clinical study. *J Clin Periodontol* 2011; 38: 276–284
39. Schwarz F, John G, Becker J: The influence of implantoplasty on the diameter, chemical surface composition, and biocompatibility of titanium implants. *Clin Oral Investig* 2017; 21: 2355–2361
40. Senna P, Antonina De Bel Cury A, Kates S, Meirelles L: Surface damage on dental implants with release of loose particles after insertion into bone. *Clin Implant Dent Relat Res* 2015; 17: 681–692
41. Shi H, Magaye R, Castranova V, Zhao J: Titanium dioxide nanoparticles: a review of current toxicological data. *Particle and Fibre Toxicology* 2013; 10: 15
42. Skocaj M, Filipic M, Petkovic J, Novak S: Titanium dioxide in our everyday life; is it safe? *Radiol Oncol* 2011; 45: 227–247
43. Sridhar S, Wilson Jr TG, Valderrama P, Watkins-Curry P, Chan JY, Rodrigues DC: In vitro evaluation of titanium exfoliation during simulated surgical insertion of dental implants. *J Oral Implantol* 2016; 42: 34–40
44. Strietzel R, Hösch A, Kalbfleisch H, Buch D: In vitro corrosion of titanium. *Biomaterials* 1998; 19: 1495–1499
45. Suárez-López del Amo F, Rudek I, Wagner VP et al.: Titanium activates the DNA damage response pathway in oral epithelial cells: a pilot study. *Int J Oral Maxillofac Implants* 2017; 32: 1413–1420
46. Thomas P, Bandl WD, Maier S, Summer B, Przybilla B: Hypersensitivity to titanium osteosynthesis with impaired fracture healing, eczema, and T-cell hyperresponsiveness in vitro: case report and review of the literature. *Contact Dermatitis* 2006; 55: 199–202
47. Valente ML da C, Lepri CP, dos Reis AC: In vitro microstructural analysis of dental implants subjected to insertion torque and pullout test. *Braz Dent J* 2014; 25: 343–345
48. Valentini X, Deneufbourg P, Paci P et al.: Morphological alterations induced by the exposure to TiO<sub>2</sub> nanoparticles in primary cortical neuron cultures and in the brain of rats. *Toxicol Rep* 2018; 5: 878–889
49. Wachi T, Shuto T, Shinohara Y, Matono Y, Makihira S: Release of titanium ions from an implant surface and their effect on cytokine production related to alveolar bone resorption. *Toxicology* 2015; 327: 1–9
50. Wang J, Zhou G, Chen C et al.: Acute toxicity and biodistribution of different sized titanium dioxide particles in mice after oral administration. *Toxicol Lett* 2007; 168: 176–185
51. Warheit DB, Frame SR: Characterization and reclassification of titanium dioxide-related pulmonary lesions. *J Occup Environ Med* 2006; 48: 1308–1313
52. Wennerberg A, Ide-Ektessabi A, Hatkamata S et al.: Titanium release from implants prepared with different surface roughness: an in vitro and in vivo study. *Clin Oral Implants Res* 2004; 15: 505–512
53. Wilson TG, Valderrama P, Burbano M et al.: Foreign bodies associated with peri-implantitis human biopsies. *J Periodontol* 2015; 86: 9–15
54. Winkler HC, Notter T, Meyer U, Naegeli H: Critical review of the safety assessment of titanium dioxide additives in food. *J Nanobiotechnology* 2018; 16: 51

55. Yan Y: Bio-tribocorrosion in bio-materials and medical implants. Elsevier, Amsterdam 2013

56. Yu F, Addison O, Davenport AJ: A synergistic effect of albumin and H<sub>2</sub>O<sub>2</sub> accelerates corrosion of Ti6Al4V. Acta Biomater 2015; 26: 355–365

57. Zeman T, Loh EW, Čierný D, Šerý O: Penetration, distribution and brain toxicity of titanium nanoparticles in rodents' body: a review. IET nanobio-technology 2018; 12: 695–700

58. Zhang Y, Addison O, Yu F, Troconis BCR, Scully JR, Davenport AJ: Time-dependent enhanced corrosion of Ti6Al4V in the presence of H<sub>2</sub>O<sub>2</sub> and albumin. Scientific reports 2018; 8: 3185



(Photo: Atelier Heim, Flöha)

---

**DR. FRIEDRICH MÜLLER M.SC.  
M.SC.**

Dental practice Dres. Müller,  
Tannenring 76, 65207 Wiesbaden,  
Germany  
St. Elisabeth University  
Bratislava, Slovakia  
Johannes Gutenberg University  
Mainz, Germany  
Friedrich.Mueller@gmx.de

Silke Jacker-Guhr, Anne-Katrin Lührs

# Beware of contamination! Do hemostatic agents influence the microtensile bond strength of a universal adhesive to dentin?

**Introduction:** The aim of this study was to evaluate whether hemostatic agents containing aluminum chloride affect the microtensile bond strength of a universal adhesive to dentin.

**Materials and Methods:** The occlusal enamel of 50 human molars was removed to expose a flat dentin surface. A universal adhesive was applied either in self-etch (SE) or etch & rinse mode (ER), or a contamination with a “hemostatic agent” (Astringent; ARP or Racegel; RAC) was performed prior to the adhesive application. In the control group (control; C), no contamination in SE and ER mode was performed. A composite build-up was placed onto the adhesively pre-treated surface and specimens were cut to obtain 80 microsticks per group. Half of the specimens were stored for 24 hours before the microtensile bond strength test was performed, the other half was tested after thermocycling (TC, 5,000 cycles). The fractured surfaces were evaluated using a light-optical microscope in order to analyze the failure pattern.

**Results:** In the SE-mode, dentin contamination with both hemostatic agents prior to universal adhesive application led to a significant decrease in bond strength, compared to the controls before (SE\_ARP:  $5.67 \pm 7.64$  MPa; SE\_RAC:  $5.08 \pm 6.04$  MPa vs. SE\_C:  $24.91 \pm 12.06$  MPa) and after TC (SE\_ARP\_TC:  $2.38 \pm 4.43$  MPa; SE\_RAC\_TC:  $4.01 \pm 4.42$  MPa vs. SE\_C\_TC  $24.27 \pm 10.67$  MPa). Moreover, the SE-mode with prior contamination showed significantly lower bond strength values to dentin before (SE\_ARP  $5.67 \pm 7.64$  MPa vs. ER\_ARP  $20.90 \pm 10.91$  MPa and SE\_RAC  $5.08 \pm 6.04$  MPa vs. ER\_RAC  $25.62 \pm 9.41$  MPa) and after TC (SE\_ARP\_TC  $2.38 \pm 4.43$  MPa vs. ER\_ARP\_TC  $20.91 \pm 11.21$  MPa and SE\_RAC\_TC  $4.01 \pm 4.42$  MPa vs. ER\_RAC\_TC  $18.94 \pm 9.54$  MPa) compared to the ER-mode. In the ER-mode, only contamination with ARP led to a significantly lower bond strength compared to uncontaminated dentin before TC. The fracture analysis showed significant more adhesive fractures in the SE-mode than in the ER-mode.

**Conclusion:** Considering the limitations of this in-vitro study, the universal adhesive showed higher dentin bond strength when used in ER-mode after contamination with an aluminum chloride-based hemostatic agent.

**Keywords:** universal adhesive; hemostatic agent; microtensile bond strength; dentin

Department of Conservative Dentistry, Periodontology and Preventive Dentistry, Hannover: OÄ Dr. Silke Jacker-Guhr, PD Dr. Anne-Katrin Lührs

**Citation:** Jacker-Guhr S, Lührs AK: Beware of contamination! Do hemostatic agents influence the microtensile bond strength of a universal adhesive to dentin? Dtsch Zahnärztl Z Int 2021; 3: 167–175

**Peer-reviewed article:** submitted: 27.05.2020, revised version accepted: 08.11.2020

DOI.org/10.3238/dzz-int.2021.0019

## 1. Introduction

Basically, three different techniques can be used for adhesive bonding to enamel and dentin: etch & rinse, selective enamel etch, and self-etch. Universal adhesives can be used with simultaneous enamel and dentin etching, with selective enamel etching, or without prior phosphoric acid etching. Enamel etching with phosphoric acid is still considered the gold standard, and it is recommended when using universal adhesives [22]. Bonding to dentin usually requires three steps: etching of the dentin surface, application of an amphiphilic primer, and finally coating with a hydrophobic adhesive [24]. Universal adhesives combine all three steps in a one-step procedure. Like conventional adhesives, they require proper isolation to provide a sufficient bond [5]. The gingiva may bleed during treatment, especially in deep subgingival areas, and it is imperative that the bleeding has to be stopped before adhesive application [26]. In contrast to supra- and slightly subgingival defects, a rubber dam cannot be used for contamination control in all deep subgingival cases. However, gingival bleeding can be stopped using chemical (hemostatic agents) and mechanical (retraction cords or rings) methods separately or in combination [27]. The chemicals used for bleeding control and gingival retraction are divided into two main groups according to their pharmacology: group 1 comprises adrenergic (vasoconstrictive) substances, group 2 comprises astringent substances based on chloride or sulfate [19]. Most commonly, ferrous sulfate in concentrations of up to 20 % and aluminum chloride in concentrations of up to 25 % are used to stop gingival bleeding [14, 27]. Both belong to group 2. Ferrous sulfate very quickly forms a metal-protein complex upon contact with blood, mechanically occluding the vessels, whereas aluminum chloride has an astringent effect [14].

When using hemostatic agents in the gingival area, contamination of the tooth surface is usually inevitable. This is particularly true for very deep class-V and class-II cavities extending to root dentin, or during “proximal box elevation technique”. An over-

view of the most common cavity depths shows that 15 % of all proximal cavities in posterior teeth are deeper than 8 mm [9]. Besides, the fact that successful tooth preservation in elderly patients is associated with an increase in root caries poses new challenges to clinicians in terms of adhesively bonded restorations [10, 21]. The use of hemostatic agents can be helpful in these situations, but a risk of interaction with adhesion, especially when using self-etch adhesives, cannot be ruled out [3]. Since the use of universal adhesives is increasing in clinical practice due to their easy handling properties, hemostatic agents may also affect the bond strength of these products. The objective of this study was therefore to examine the bond strength of a universal adhesive to human dentin contaminated with hemostatic agents containing aluminum chloride.

The following null hypotheses were set:

1. The contamination of the dentin surface with hemostatic agents containing aluminum chloride does not influence the bond strength of a universal adhesive used in the self-etch mode.
2. The contamination of the dentin surface with hemostatic agents containing aluminum chloride does not influence the bond strength of a universal adhesive used in the etch & rinse mode.

## 2. Materials and methods

For this in-vitro study, 50 caries- and restoration-free permanent human molars were collected and cleaned from debris. The teeth were stored in chloramine-T solution (0.5 %) at 8°C until preparation for no longer than 6 months. All procedures performed in this study were in accordance with the ethical standards of the institutional research committee and with the 1964 Helsinki declaration and its later amendments. The use of extracted human teeth for bond strength testing was approved by the responsible ethical committee of the Hannover Medical School (no. 2092–2013). The teeth were randomly divided into 6 groups (Tab. 1) with at least 8 teeth per group. The teeth were kept moist throughout the

entire experimental procedure. In two groups, the number of teeth had to be enlarged to 9 teeth because of the size of the teeth (leading to less than 80 sticks without adjustment). The teeth were embedded in gypsum parallel to the tooth axis, then, the occlusal enamel was cut at a right angle to expose a flat dentin surface (IsoMet Low Speed Saw, Buehler, Esslingen am Neckar, Germany). In order to create a clinically relevant smear layer, all dentin surfaces were roughened using grinding paper (SiC Grinding Paper 600 Grit P, Buehler, Esslingen am Neckar, Germany), rinsed with water and carefully dried using a SPRAYVIT syringe (KaVo Dental GmbH, Biberach, Germany). Then, either the adhesive (Scotchbond Universal, 3M Oral Care, 3M Deutschland GmbH, Seefeld, Germany) was applied in self-etch or etch & rinse mode (control groups), or contamination with a hemostatic agent was performed prior to adhesive application (experimental groups, Tab. 1 and 2). Subsequently, a composite build-up (3M Z100 MP, 3M Oral Care, 3M Deutschland GmbH, Seefeld, Germany) was placed onto the adhesively pre-treated surface (6 mm in height, 4 layers, each 1.5 mm in thickness). Each layer was polymerized for 20 seconds with a light-emitting diode (LED) unit (Bluephase, Ivoclar Vivadent, Schaan, Liechtenstein) at 1100 mW/cm<sup>2</sup> from the top surface using a standardized protocol. Before each light curing cycle, the power output of the LED unit was checked with a testing device (Bluephase Meter, Ivoclar Vivadent, Schaan, Liechtenstein). The specimens for the microtensile bond strength test were cut with a high speed saw to obtain microsticks with a bonded area of approx. 1.66 mm<sup>2</sup> (IsoMet High Speed Pro, Buehler, Esslingen am Neckar, Germany). Before testing, all sticks were measured carefully with a digital gauge. Half of the sticks (n = 40) were stored for 24 hours in distilled water at 37°C before the microtensile bond strength ( $\mu$ TBS) test was performed. The other half (n = 40) was tested after thermocycling (5,000 cycles, dwell time 30 sec, changeover time 10 sec, 5°/55°C). Afterwards, the specimens

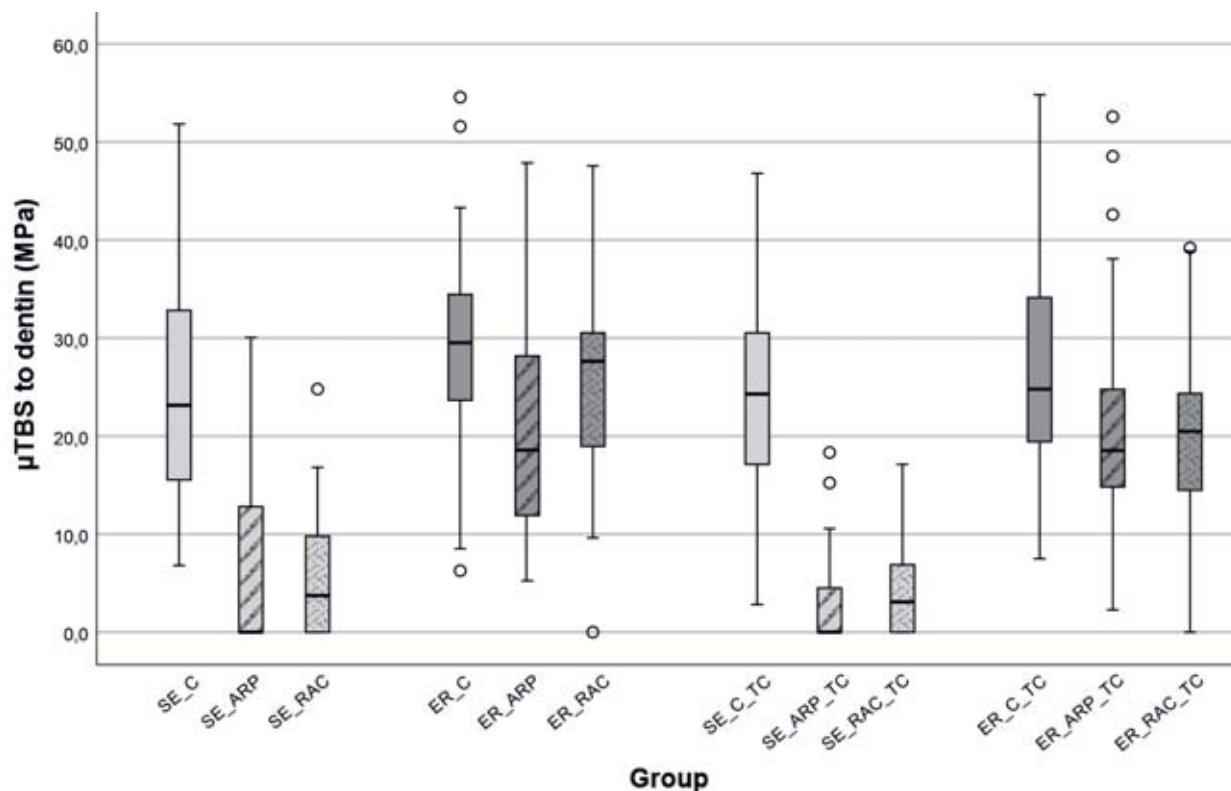
| Group     | Number of specimens (sticks) for $\mu$ TBS-testing in total | Number of specimens included into the statistical analyses | Number of zero bonds | Sticks excluded from statistical analyses | Surface pre-treatment and adhesive application   |
|-----------|---|--|----------------------|---|--|
| SE_C      | 40  | 36   | –                    | 4   | Application of Scotchbond Universal in self-etch mode  |
| SE_ARP    | 40  | 18   | 22                   | –   | Application of Astringent Retraction Paste prior to application of Scotchbond Universal in self-etch mode.         |
| SE_RAC    | 40  | 21   | 19                   | –   | Application of Racegel prior to application of Scotchbond Universal in self-etch mode.                             |
| ER_C      | 40  | 39   | –                    | 1   | Application of Scotchbond Universal in etch & rinse mode   |
| ER_ARP    | 40  | 39   | –                    | 1   | Application of Astringent Retraction Paste prior to application of Scotchbond Universal in etch & rinse mode       |
| ER_RAC    | 40  | 39   | 1                    | –   | Application Racegel prior to application of Scotchbond Universal in etch & rinse mode.                             |
| SE_C_TC   | 40  | 40   | –                    | –   | Application of Scotchbond Universal in self-etch mode + TC   |
| SE_ARP_TC | 40  | 13   | 27                   | –   | Application of Astringent Retraction Paste prior to application of Scotchbond Universal in self-etch mode + TC     |
| SE_RAC_TC | 40  | 23   | 17                   | –   | Application of Racegel prior to application of Scotchbond Universal in self-etch mode + TC.                        |
| ER_C_TC   | 40  | 39   | –                    | 1   | Application of Scotchbond Universal in etch & rinse mode + TC  |
| ER_ARP_TC | 40  | 37   | –                    | 3   | Application of Astringent Retraction Paste prior to application of Scotchbond Universal in etch & rinse mode + TC. |
| ER_RAC_TC | 40  | 35   | 3                    | 2   | Application of Racegel prior to application of Scotchbond Universal in etch & rinse mode + TC.                     |

**Table 1** Experimental and control groups, number of specimens (n) for  $\mu$ TBS-testing in total, specimens included into the statistical analyses, zero bonds, specimens excluded from statistical analyses, surface pre-treatment and adhesive application, SE: self-etch mode, ER: etch & rinse mode C: Control, ARP: Astringent Retraction Paste, RAC: Racegel, TC: thermocycling,

were mounted onto a special jig and loaded using a universal testing machine (MTD-500+, SD Mechatronik GmbH; Feldkirchen-Westerham, Germany) with a 500 N load cell traveling at a crosshead speed of 0.5 mm/

min. Force values were measured in N. The bond strength in MPa was calculated by dividing the force in N by the surface of the respective micro-stick. Sticks which fractured during the cutting process or during thermo-

cycling were included as zero bonds in the statistical analysis. Sticks which fractured far from the interface or during manipulation were excluded from the analyses. All fractured surfaces were evaluated using a



**Figure 1** Mean microtensile bond strength in MPa with and without TC using the self-etch or the etch & rinse mode. The horizontal line within the box indicates the median values for each group. The circles represent outliers, SE: self-etch mode, ER: etch & rinse mode C: Control, ARP: Astringent Retraction Paste, RAC: Racegel, TC: thermocycling.

light-optical microscope (Stemi SV 6, Zeiss, Jena, Germany) in order to analyze the failure pattern (50x magnification). Three different types of failure were defined:

- adhesive fracture at the resin/dentin interface,
- cohesive fracture (fracture in dentin or composite),
- mixed fracture (combination of adhesive and cohesive fracture).

### 2.1. Statistical analysis

For the statistical analysis, the mean values and the standard deviations were calculated. The normal distribution of the data was tested using the Shapiro-Wilk-test. The level of significance was set at  $p < 0.05$ . Mean values of the different groups were compared by one-way ANOVA. In order to identify significant differences between each group, the Tukey-HSD was used. The results from the fracture analysis were statistically analyzed using cross tabs and the Chi-square test (SPSS 23.0 IBM Deutschland GmbH, Ehningen, Germany).

## 3. Results

### 3.1. Microtensile Bond Strength Test

The analysis of variance showed significant differences between the experimental groups ( $p < 0.001$ ). The bond strength of the control groups, i.e. bonding to uncontaminated dentin in self-etch and etch & rinse mode, was not significantly different (SE\_C:  $24.91 \pm 12.06$  MPa vs. ER\_C:  $29.6 \pm 10.27$  MPa;  $p = 0.554$ ). Thermocycling (TC) did not significantly influence the results when compared to the control before TC, either (SE\_C\_TC:  $24.27 \pm 10.67$  MPa;  $p = 1.000$ ; and ER\_C\_TC:  $27.27 \pm 11.28$  MPa;  $p = 0.955$ , Tab. 3, Fig. 1). In the self-etch mode, dentin contamination with both hemostatic agents prior to universal adhesive application led to a significant decrease in bond strengths, compared to the controls (SE\_ARP:  $5.67 \pm 7.64$  MPa;  $p < 0.001$ ; and SE\_RAC:  $5.08 \pm 6.04$  MPa;  $p < 0.001$ ). The same applies to the results obtained after

thermocycling (SE\_ARP\_TC:  $2.38 \pm 4.43$  MPa;  $p < 0.001$ ; and SE\_RAC\_TC:  $4.01 \pm 4.42$  MPa;  $p < 0.001$ , Tab. 3, Fig. 1). In the etch & rinse mode, only contamination with Astringent Retraction Paste (ARP) led to a significantly lower bond strength compared to uncontaminated dentin (ER\_ARP:  $20.90 \pm 10.91$  MPa vs. ER\_C:  $29.60 \pm 10.27$  MPa;  $p = 0.002$ ). After thermocycling, however, experimental and control groups were no longer significantly different (ER\_ARP\_TC:  $20.91 \pm 11.21$  MPa vs. ER\_C\_TC:  $27.27 \pm 11.28$  MPa;  $p = 0.115$ ). Dentin contamination with Racegel initially did not have any significant influence on bond strength (ER\_RAC:  $25.62 \pm 9.41$  MPa vs. ER\_C:  $29.60 \pm 10.27$  MPa;  $p = 0.752$ ). After TC, however, there was a significant difference between the groups (ER\_RAC\_TC:  $18.94 \pm 9.54$  MPa vs. ER\_C\_TC:  $27.27 \pm 11.28$  MPa;  $p = 0.005$ , Tab. 3, Fig. 1). A direct comparison of the two etching modes (self-etch vs. etch & rinse) after contamination with Astringent or Race-

| Material                          | Batch-no         | Composition   | Manufacturer  | Manufacturer's instructions   |
|-----------------------------------|------------------|---|---|---|
| DeTrey Conditioner 36             | 1803001142       | Phosphoric acid, highly dispersed silicon dioxide, detergent, pigment, water              | Dentsply DeTrey GmbH, Konstanz, Germany                 | Etching of dentin for 15 sec  |
| Scotchbond Universal (SBU)        | 80912B           | 10-MDP, HEMA, Dimethacrylate, Vitrebond Copolymer, filler, ethanol, water, initiators     | 3M, 3M Oral Care, 3M Deutschland GmbH, Seefeld, Germany | <b>Self-Etch approach:</b> application of SBU and rubbing for 20 sec, air-thinning 5 sec, light curing for 10 sec<br><b>Etch &amp; Rinse approach:</b> Etching of dentin for 15 sec (35 % phosphoric acid), rinsing with water (15 sec) and immediately air-drying. Application and curing: see self-etch approach.   |
| Astringent Retraction Paste (ARP) | 4382643          | Aluminum chloride hexahydrate, mica-group minerals, water, kaolin, poly(dimethylsiloxane) | 3M, 3M Oral Care, 3M Deutschland GmbH, Seefeld, Germany | Application of Astringent Retraction Paste on dentin surface, contact time to dentin 2 minutes, complete removal of the paste with air-water spray and suction.   |
| Racegel (RAC)                     | B22819AE         | Aluminum chloride hexahydrate, ethanol  | Septodont GmbH, Niederkassel, Germany                   | Application of Racegel on dentin surface, contact time to dentin 2 minutes, complete removal of the paste with air-water spray and suction  |
| Z100 MP Restorative – shade A3    | N971244, N997767 | Silane treated ceramic, TEGDMA, BISGMA, 2-benzotriazolyl-4-methylphenol                   | 3M, 3M Oral Care, 3M Deutschland GmbH, Seefeld, Germany | Z100 restorative is intended to be cured by exposure to a halogen or LED light with a minimum intensity of 400 mW/cm <sup>2</sup> in the 400–500 nm range. Cure each increment by exposing its entire surface to a high intensity visible light source. Hold the light guide tip as close to the restorative as possible during light exposure. Shade A3: Thickness 2.5 mm à 40 sec |

**Table 2** Material, batch-number, composition, manufacturer, manufacturer's instruction

gel showed significantly higher bond strengths after phosphoric acid etching, compared to self-etching (SE\_ ARP: 5.67 ± 7.64 MPa vs. ER\_ ARP: 20.90 ± 10.91 MPa; p < 0.001; and SE\_ RAC: 5.08 ± 6.04 MPa vs. ER\_ RAC: 25.62 ± 9.41 MPa; p < 0.001). The same applies to the results obtained after thermocycling (SE\_ ARP\_ TC: 2.38 ± 4.43 MPa vs. ER\_ ARP\_ TC: 20.91 ± 11.21 MPa; p < 0.001; and SE\_ RAC\_ TC: 4.01 ± 4.42 MPa vs. ER\_ RAC\_ TC: 18.94 ± 9.54 MPa; p < 0.001, Tab. 3, Fig. 1).

### 3.2. Fracture analysis

When the universal adhesive was applied in the self-etch mode without prior contamination, 77.78 % of the

initial fractures were adhesive, 5.56 % cohesive, and 16.67 % mixed. After TC, there was an increase in mixed (42.5 %) and cohesive fractures (22.5 %) and a decrease in adhesive fractures (35 %) (p = 0.001). In the etch & rinse mode, no significant differences between the fracture types were observed, neither before TC (ER\_ C; adhesive 40 %, cohesive 20 %, mixed 40 %) nor after TC (ER\_ C\_ TC; adhesive 32.5 %, cohesive 25 %, mixed 42.5 %) (p < 0.755) (Fig. 2).

In the self-etch mode, dentin contamination with Astringent led to 100 % adhesive fractures, both before and after TC. Dentin contamination with Racegel showed

similar results: before TC, 94.87 % of the fractures were adhesive and after TC, all samples (100 %) fractured adhesively 100 % (p < 0.241) (Fig. 2). In the etch & rinse mode, dentin contamination with Astringent showed 74.36 % adhesive, 2.56 % cohesive and 23.08 % mixed fractures before TC. After TC, adhesive fractures decreased to 56.76 %; 8.11 % of the fractures were cohesive, and 35.16 % mixed (p < 0.228). In the case of Racegel, there were initially 42.50 % adhesive, 2.50 % cohesive and 55 % mixed fractures. After TC, mixed fractures increased to 68.42 %, and adhesive fractures decreased to 26.32 % (p < 0.296) (Fig. 2).

|     | SE                          | ER                          | SE_TC                       | ER_TC                        |
|-----|-----------------------------|-----------------------------|-----------------------------|------------------------------|
| C   | 24.91 ± 12.06 <sup>aA</sup> | 29.60 ± 10.27 <sup>aA</sup> | 24.27 ± 10.67 <sup>aA</sup> | 27.27 ± 11.28 <sup>aA</sup>  |
| ARP | 5.67 ± 7.64 <sup>bA</sup>   | 20.90 ± 10.91 <sup>bB</sup> | 2.38 ± 4.43 <sup>bA</sup>   | 20.91 ± 11.21 <sup>abB</sup> |
| RAC | 5.08 ± 6.04 <sup>bA</sup>   | 25.62 ± 9.41 <sup>abB</sup> | 4.01 ± 4.42 <sup>bA</sup>   | 18.94 ± 9.54 <sup>bB</sup>   |

**Table 3** Mean microtensile bond strength in MPa of the individual groups, second row: mean values of the control groups (Scotchbond Universal control; C) without prior contamination in self-etch and etch & rinse mode before and after TC, third and fourth row: mean values of the experimental groups (ARP and RAC) before and after TC. Values with different lowercase letters in vertical direction are statistically different. Values with different uppercase letters in horizontal direction are statistically different, SE: self-etch mode, ER: etch & rinse mode C: Control, ARP: Astringent Retraction Paste, RAC: Racegel, TC: thermocycling.

(Fig. 1 and 2, Tab. 1–3: S. Jacker-Guhr and A.-K. Lührs)

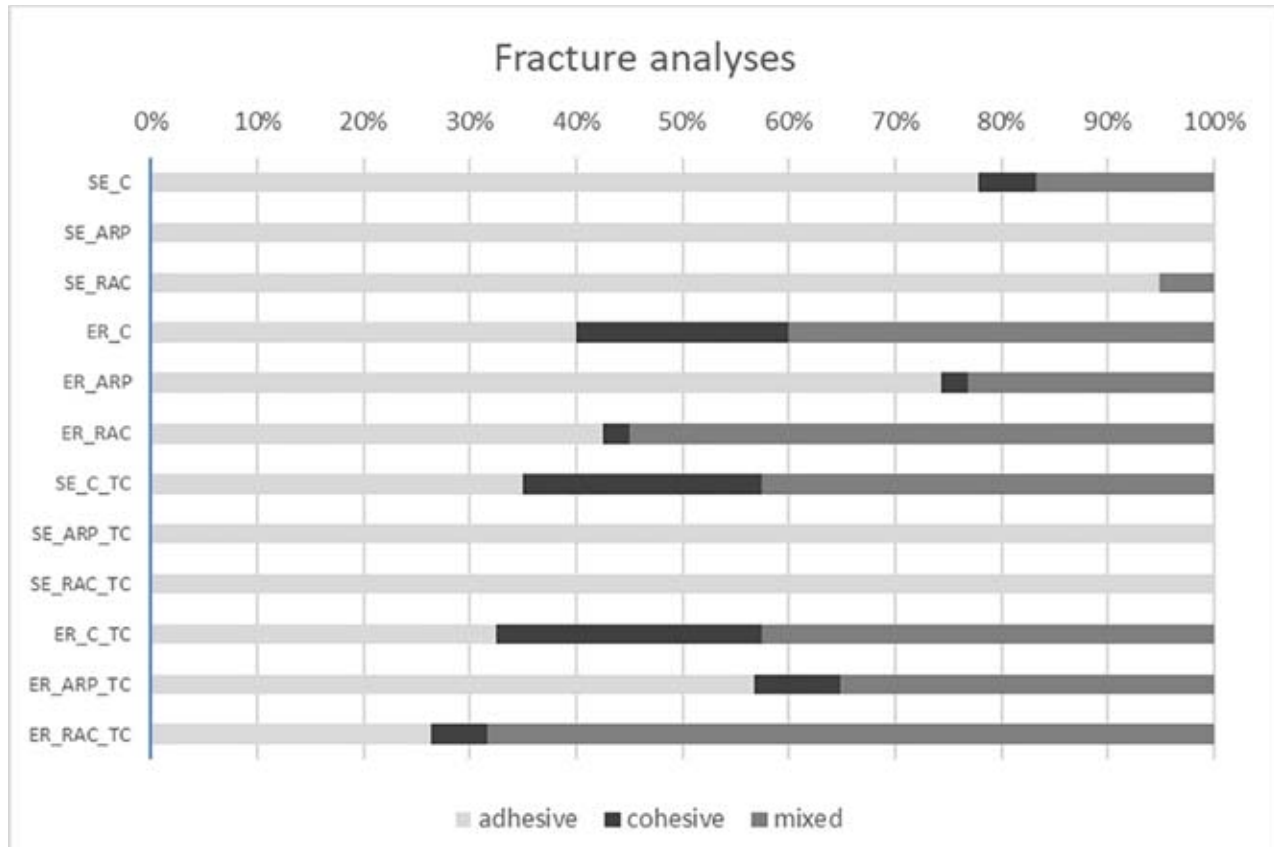
#### 4. Discussion

Astringents are, by definition, substances which precipitate proteins, but without penetrating cells, so that only the superficial layer of the mucosa is involved [17]. These substances can be used in various ways and are suitable for superficial, local bleeding control in sufficiently high concentrations [17]. Aluminum chloride and ferrous sulfate are often used to arrest bleeding prior to taking impressions or restoring subgingival cavities with direct composites, thanks to their beneficial properties and minimal tissue irritation. Previous studies already showed that hemostatic agents have a certain influence on the bond strength of adhesively bonded restorations; also, marginal gap formation increased in cervical areas [2, 16, 20, 25]. A two-step self-etch adhesive system provided lower bond strengths after the use of a hemostatic agent containing ferrous sulfate, as compared to the uncontaminated control group [5]. In contrast, a hemostatic containing aluminum chloride did not influence dentin bond strengths [25]. These results are inconsistent with the results of our study, which showed significantly lower bond strengths to dentin contaminated with an aluminum-based agent versus uncontaminated dentin in the self-etch mode. The same applies to the results obtained after thermocycling (see Tab. 3 and Fig. 1). In a previous study, Land et al. showed that hemostatic agents containing 15.5 % ferrous sulfate completely remove the smear layer from prepared dentin and, after pro-

longed application (5 min), cause demineralization of the dentin surface with partial loss of peritubular dentin [13]. The investigators attribute this effect to the low pH-value (0.8–0.9) of the hemostatic agent applied to the dentin surface [13]. Kuphasuk et al. showed similar effects for a hemostatic agents containing 25 % aluminum chloride (pH = 0.8), which partially removed the smear layer without completely exposing the dentinal tubules after an application time of 30 sec [12]. The hemostatics used in our in-vitro study had mild pH-values (Racegel pH = 2.3–3.5 and Astringent pH = 3.2–4.0; Safety Data Sheet, Racegel, Septodont; Safety Data Sheet, Astringent Retraction Paste, 3M Oral Care, 3M Deutschland GmbH). As a consequence, these agents would only incompletely, if at all, remove the smear layer from the dentin surface. Kuphasuk et al. also showed that the use of a hemostatic containing aluminum chloride resulted in lower bond strength of a two-step self-etch adhesive system, as compared to the uncontaminated control group; however, this effect was not present for an etch & rinse system [12]. Our study confirms these findings. Kuphasuk et al. demonstrated that doubling the application time of the self-etch primer from 20 to 40 sec led to a significant increase in bond strength to contaminated dentin [12]. The investigators attribute this to an enhanced etching effect, which not only completely removes the smear layer, but also removes peritubular dentin and completely exposes dentinal tubules

[12]. In scanning electron microscopic (SEM) imaging, this effect appeared to be similar to phosphoric acid etching [12]. We applied a universal adhesive with a relatively mild pH-value (Scotchbond Universal: pH = 2.7; Safety Data Sheet, Scotchbond Universal, 3M Oral Care, 3M Deutschland GmbH) for 20 sec in the self-etch mode; this may explain the low bond strengths obtained after contamination, in addition to the milder pH-values of the hemostatic agents used. Another explanation may be that a component of the hemostatic agents, namely aluminum, can replace the calcium contained in hydroxyapatite, which leads to the formation of insoluble calcium compounds [12, 15]. The weak acids of self-etch primers do not seem to be capable of dissolving these compounds, and as a result bond strengths are lower [12, 15]. Scotchbond Universal, the adhesive used in our study, has a pH-value of 2.7 and thus can be classified as an “ultra-mild” system (Safety Data Sheet, Scotchbond Universal, 3M Oral Care, 3M Deutschland GmbH). The above-mentioned interaction of the hemostatic with the dentin surface may considerably reduce monomer infiltration in the self-etch mode, as indicated by significantly lower bond strength of this group versus the control group (see Tab. 3 and Fig. 1). Hemostatic components remaining on the dentin surface may block dentinal tubules, preventing sufficient adhesive infiltration, and therefore negatively influencing the formation of a proper hybrid layer [1, 3, 20]. An





**Figure 2** Bar graph depicting the percentages of adhesive, cohesive and mixed fractures, SE: self-etch mode, ER: etch & rinse mode C: Control, ARP: Astringent Retraction Paste, RAC: Racegel, TC: thermocycling,

SEM examination showed that an amorphous surface layer was formed after contamination of the dentin surface with a hemostatic fluid for 1 to 2 min. Two of the hemostatic agents tested contained aluminum chloride, like the two products we examined, and the application time was also identical with the times we used. Therefore, the hemostatic agents used in our study may have caused a change in the dentin surface similar to the effect described by Ayo-Yusuf et al. [2]. Analysis by energy-dispersive x-ray spectroscopy (EDS) and SEM showed that phosphoric acid etching for 20 sec removed almost all calcium and phosphate from the dentin surface, due to the demineralizing effect of the acid. After hemostatic contamination, however, phosphoric acid etching did not result in the same degree of demineralization, because the use of hemostatic agents had led to the formation of granular deposits, which cannot be completely removed by etching [2]. In our study,

one group showed similar initial bond strengths as the control after hemostatic contamination and phosphoric acid etching (ER\_RAC), whereas the other group showed values that were significantly lower (ER\_ARP: -29 %, as compared to the control). An explanation may be that the two hemostatic agents interacted with dentin to different extents, causing that the etching effect differed as well. This was also shown in an EDS analyses by Ayo-Yusuf et al., in which the demineralizing effect of phosphoric acid differed significantly, depending on the hemostatic used [2]. However, thanks to its lower pH-value (< 2), phosphoric acid seems to more effectively remove residues or reaction products of hemostatic agents and dentin from the tubules and the surface during demineralization, as compared to adhesives used in the self-etch mode. Phosphoric acid allows adhesives to infiltrate the dentinal tubules and form a proper hybrid layer [3]. In addition to phosphoric acid, EDTA

seems to be highly effective in removing residues from dentin surfaces after aluminum chloride contamination [1]. Using EDTA, an increase in bond strengths to the level of an uncontaminated control group without any pretreatment was achieved; for phosphoric acid, this effect was weaker [1].

The effects described by Ayo-Yusuf et al. und Kuphasuk et al. are also relevant when using universal adhesives in the self-etch mode: the acidic monomers of universal adhesives etch dentin surfaces covered with the above-mentioned amorphous layer to a lesser extent [2, 12]. Besides, as a result of the replacement of calcium by aluminum, less calcium is available for the formation of chemical bonds [12]. The hydrophobic functional monomer 10-MDP has a high potential to interact with the tooth structure by forming a stable salt with the calcium contained in hydroxyapatite [4]. So the lower bond strength of the universal adhesive in the self-etch mode in our

study may also be attributed to the fact that calcium reacts with and is bound by components of the astringents used, and therefore the dentin surface contains less reactive calcium ions [2, 12]. Studies conducted by O’Keefe KL et al. and Ajami et al. also indicate a negative influence of dentin contamination with ferrous sulfate or aluminum chloride on the bond strength of adhesives used in the self-etch mode, as compared to uncontaminated dentin [1, 20].

A comparison of the two application modes (self-etch vs. etch & rinse) without dentin contamination shows high bond strength in the self-etch mode, not significantly different from the one obtained in the etch & rinse mode. This may be attributed to the presence of 10-MDP, which reacts with the calcium contained in hydroxyapatite, establishing a chemical bond to dentin [23].

Although hemostatic agents may negatively influence bond strength, it is advisable for clinicians to use them to control gingival bleeding. Blood contamination affects the bond strength of self-etch adhesive systems to a varying extent, depending on the time at which it occurs and also on the “decontamination measures” taken, e.g. reapplication of a self-etch primer with or without prior rinsing [5]. Due to this diversity of outcomes, there is no standardized “decontamination protocol”, which would reliably lead to an increase in bond strength to the level of the control group [5]. In addition to a decrease in bond strength to dentin, there is also an increase in adhesive fractures [3, 5]. In the present study, no blood contamination of the dentin surface was conducted. In the clinical situation, especially in deep cavities, a mixture of hemostatic agents and blood can be present on the dentin surface. Groddek et al. investigated the marginal adaptation of composite restorations in enamel and dentin using different adhesive systems (etch & rinse and self-etch) after blood contamination of the cavity and treatment with various hemostatic agents [8]. No significant effect on marginal adaptation after blood contamination and application of a hemostatic agent was

present [8]. The etch & rinse procedure showed no adverse effect on margins located in dentin [8]. The results of our fracture analysis may also, in addition to the low bond strength in our microtensile test, be indicative of impaired interaction of the universal adhesive with dentin when used in the self-etch mode: Microscopic analysis showed high percentages of adhesive fractures (94.9–100 %, see Fig. 1).

Thermocycling significantly influenced the bond strength only for the etch & rinse RAC groups. ISO Standard 11450 specifies that 500 thermocycles between 5 °C and 55 °C will be sufficient for artificial aging (International Standards Organization, 1994). However, dwell times and numbers of cycles vary greatly between different in-vitro studies [7]. The literature does not provide any standardized thermocycling protocol, so we used the most common method, i.e. 5,000 thermocycles between 5 °C and 55 °C [6, 18]. It has to be proven whether a higher number of cycles has any influence on the bond strength, but a certain tendency is clearly recognizable [11].

## 5. Conclusion

Contamination of dentin surfaces with hemostatic agents containing aluminum chloride should be avoided as far as possible when using a universal adhesive. If dentin is contaminated with an aluminum-based hemostatic during treatment, it seems preferable to use a universal adhesive in the etch & rinse mode. Phosphoric acid etching after contamination will then have a cleaning effect, leading to sufficient bonding. In order to prevent contamination of the cavity with either saliva or blood, the use of rubber dam is still the best clinical approach because hemostatic agents might not be required.

## Conflicts of Interest

The authors declare that there is no conflict of interest within the meaning of the guidelines of the International Committee of Medical Journal Editors.

## References

1. Ajami AA, Kahnemoii MA, Kimyai S et al.: Effect of three different contamination removal methods on bond strength of a self-etching adhesive to dentin contaminated with an aluminum chloride hemostatic agent. *J Contemp Dent Pract* 2013; 14: 26–33
2. Ayo-Yusuf OA, Driessen CH, Botha AJ: SEM-EDX study of prepared human dentine surfaces exposed to gingival retraction fluids. *J Dent* 2005; 33: 731–739
3. Bernades Kde O, Hilgert LA, Ribeiro AP, Garcia FC, Pereira PN: The influence of hemostatic agents on dentin and enamel surfaces and dental bonding: a systematic review. *J Am Dent Assoc* 2014; 145: 1120–1128
4. Carrilho E, Cardoso M, Marques Ferreira M, Marto CM, Paula A, Coelho AS: 10-MDP based dental adhesives: adhesive interface characterization and adhesive stability – a systematic review. *Materials* 2019; 12: 1–18
5. Chang SW, Cho BH, Lim RY et al.: Effects of blood contamination on microtensile bond strength to dentin of three self-etch adhesives. *Oper Dent* 2010; 35: 330–336
6. Ernst CP, Canbek K, Euler T, Willershausen B: In vivo validation of historical in vitro thermocycling temperature range for dental materials testing. *Clin Oral Invest* 2004; 8: 130–138
7. Gale MS, Darvell BW: Thermal cycling procedures for laboratory testing of dental restorations. *J Dent* 1999; 27: 89–99
8. Groddek S, Attin T, Tauböck TT: Effect of cavity contamination by blood and hemostatic agents on marginal adaptation of composite restorations. *J Adhes Dent* 2017; 19: 259–264
9. Hansen EK, Asmussen E: Visible-light curing units: correlation between depth of cure and distance between exit window and resin surface. *Acta Odontol Scand* 1997; 55: 162–166
10. Jordan AR, Micheelis W: Fünfte Deutsche Mundgesundheitsstudie (DMS V). Deutscher Zahnärzte Verlag DÄV, Köln 2016
11. Jurubeba JEP, Costa AR, Correr-Sobrinho L et al.: Influence of thermal cycles number on bond strength of metallic brackets to ceramic. *Braz Dent J* 2017; 28: 206–209
12. Kuphasuk W, Harnirattisai C, Senawongse P, Tagami J: Bond strengths of two adhesive systems to dentin contaminated with a hemostatic agent. *Oper Dent* 2007; 32: 399–405
13. Land MF, Rosenstiel SF, Sandrik JL: Disturbance of the dentinal smear layer

by acidic hemostatic agents. *J Prosthet Dent* 1994; 72: 4–7

14. Maischberger C, Stawarczyk B, von Hajmasy A, Liebermann A: Hemostatic gingival retraction agents and their impact on prosthodontic treatment steps: a narrative review. *Quintessence Int* 2018; 49: 719–732

15. Martin RB: The chemistry of aluminum as related to biology and medicine. *Clin Chem* 1986; 32: 1797–1806

16. Mohammadi N, Kimyai S, Bahari M, Pournaghi-Azar F, Mozafari A: Effect of aluminum chloride hemostatic agent on microleakage of class V composite resin restorations bonded with all-in-one adhesive. *Med Oral Patol Oral Cir Bucal* 2012; 17: 841–844

17. Mohan M, Gupta A, Shenoy V, Parolia A: Pharmacological agents in dentistry: a review. *Br J Pharm Res* 2011; 1: 66–87

18. Morresi AL, D’Amario M, Capogreco M et al.: Thermal cycling for restorative materials: does a standardized protocol exist in laboratory testing? A literature review. *J Mech Behav Biomed Mater* 2014; 29: 295–308

19. Nowakowska D: Classification of chemical retraction agents. *Prostet Stomatol* 2008; 58: 202–208

20. O’Keefe KL, Pinzon LM, Rivera B, Powers JM: Bond strength of composite to astringent-contaminated dentin using self-etching adhesives. *Am J Dent* 2005; 18: 168–172

21. Pentapati KC, Siddig H, Yeturu SK: Global and regional estimate of the prevalence of root caries – systematic review and meta-analysis. *Saudi Dent J* 2019; 31: 3–15

22. Perdigão J, Loguercio AD: Universal or multi-mode adhesives: why and how? *J Adhes Dent* 2014; 16: 193–194

23. Perdigão J, Sezinando A, Monteiro PC: Laboratory bonding ability of a multi-purpose dentin adhesive. *Am J Dent* 2012; 25: 153–158

24. Rosa WL, Piva E, Silva AF: Bond strength of universal adhesives: a systematic review and meta-analysis. *J Dent* 2015; 43: 765–776

25. Saad A, Inoue G, Nikaido T et al.: Effect of dentin contamination with two hemostatic agents on bond strength of resin-modified glass ionomer cement with different conditioning. *Dent Mater* 2019; 38: 257–263

26. Taneja S, Kumari M, Bansal S: Effect of saliva and blood contamination on the shear bond strength of fifth-, seventh-, and eighth-generation bonding agents: An in vitro study. *J Conserv Dent* 2017; 20: 157–160

27. Tarighi P, Khoroushi M: A review on common chemical hemostatic agents in restorative dentistry. *Dent Res J* 2014; 11: 423–428



(Photo: Med. Hochschule Hannover)

**DR. SILKE JACKER-GUHR**  
 Department of Conservative Dentistry,  
 Periodontology and Preventive  
 Dentistry, Hannover Medical School  
 Carl-Neuberg-Str. 1, 30625 Hannover,  
 Germany  
 Jacker-Guhr.Silke@mh-hannover.de



(Photo: Med. Hochschule Hannover)

**PD DR. ANNE-KATRIN LÜHRS**  
 Department of Conservative Dentistry,  
 Periodontology and Preventive  
 Dentistry, Hannover Medical School  
 Carl-Neuberg-Str. 1, 30625 Hannover,  
 Germany  
 Luehrs.Anne-Katrin@mh-hannover.de

Jaana-Sophia Kern, Taskin Tuna, Stefan Wolfart

# Update of the S3-Guideline “Implant-prosthetic rehabilitation in the edentulous maxilla” – What is new?

**Summary:** In 2013, the first version of the S3-guideline “Implant-prosthetic rehabilitation in the edentulous maxilla” was published [7]. The professional society that released the guideline (Deutsche Gesellschaft für Implantologie e.V.) invited participants to attend a new guideline conference in September 2019. The results from this conference, where representatives from a total of 15 professional societies participated, have now been published in the form of a recent update. In preparation for the update, a systematic literature search in the relevant databases was repeated and the retrieved literature was assessed; this resulted in the inclusion of 11 additional studies. Exclusively titanium implants were examined. The superstructures were fixed (one-piece, screw-retained) or removable (mostly bar-retained). The key recommendations relating to the number of implants were checked and confirmed. In total, 14 new recommendations and statements were included; many of these are related to fixed restorations on 4 implants.

**Keywords:** edentulous; implant-prosthetic rehabilitation; implant-supported; S3-Guideline; maxilla; number of implants

---

Department of Prosthodontics and Dental Materials, Center for Implantology, Medical Faculty, RWTH Aachen University: Dr. Jaana-Sophia Kern, M.Sc., Corresponding author  
Translation from German: Cristian Miron

**Citation:** Jaana-Sophia Kern, Taskin Tuna, Stefan Wolfart: Update of the S3-Guideline “Implant-prosthetic rehabilitation in the edentulous maxilla” – What is new? Dtsch Zahnärztl Z Int 2021; 3: 176–181

DOI.org/10.3238/dzz-int.2021.0020

## 1. What remains the same – what is new?

The aim of this guideline is to provide evidence-based treatment recommendations to dentists and specialists practicing implantology. These recommendations are based on both the latest scientific knowledge and the individual know-how (experience, expertise) of specialists in the domain.

The update of the systemic guideline and literature search was performed based on the keywords and search strings already used in the first version; the websites [www.awmf-online.de](http://www.awmf-online.de), [www.leitlinien.de](http://www.leitlinien.de), [www.g-i-n.net](http://www.g-i-n.net), and [www.guideline.gov](http://www.guideline.gov), in addition to the electronic databases PubMed, Cochrane Library and DIMDI, were used. A manual search was conducted in various German journals as well. After the assessment of the literature using methodology checklists according to "SIGN 50 – A guideline developer's handbook" [1], 7 prospective clinical trials [2–4, 6, 12, 13, 15] and 4 randomized controlled trials [8–11] were finally included. These further corroborated the results of the 16 already existing studies.

The included studies ranged in duration from 3 to 11 years. In total, 1093 patients who were treated with 2–8 implants and either a removable or fixed superstructure were examined. The majority of the restorations were one-piece, screw-retained implant-supported FPDs and bar-retained overdentures. In a few cases, telescopic or ball attachment systems were used; in only one study, patients were treated with multiple, separately cemented implant-supported FPDs. Details can be found in the evidence table of the guideline and methods report.

Work on the guideline began already in 2010. Since then, it has evolved considerably and grown in comprehensiveness over the course of a decade. Although the first version and the ensuing updates contained recommendations which mainly referred to the number of implants to be used, based on the type of restoration (fixed or removable), the updated version now offers both new and partly modified recommen-

|     |   |
|-----|---|
| 1++ | High quality meta-analyses, systematic reviews of RCTs or RCTs with a very low risk of bias   |
| 1+  | Well-conducted meta-analyses, systematic reviews or RCTs with a low risk of bias  |
| 1–  | Meta analyses, systematic reviews or RCTs with a low risk of bias   |
| 2++ | High quality systematic overviews of case control or cohort studies<br>High quality case control or cohort studies with a very low risk of confounding factors or bias and a high probability that the relationship is causal |
| 2+  | Well-conducted case control or cohort studies with a low risk of confounding factors or bias and a moderate probability that the relationship is causal   |
| 2–  | Case control or cohort studies with a high risk of confounding factors or bias and a significant risk that the relationship is not causal   |
| 3   | Non-analytical studies, e.g. case reports, series of cases  |
| 4   | Expert opinion  |

(Table 1. Source: SIGN (Scottish Intercollegiate Guidelines Network))

**Table 1** Level of evidence according to SIGN 50.

dations and statements on the following topics: timing of loading, treatment planning using digital volume tomography (DVT), patient compliance, (palate-free) prosthesis design/stabilization, selection of retention elements, full-arch restorations and oral health-related quality of life. All recommendations and statements were approved in an independently moderated, structured consensus process (details are available in the methods report).

The key recommendations regarding the number of implants were checked and confirmed in order to provide additional recommendations for fixed restorations on 4 implants.

## 2. Recommendations

The following section lists all of the recommendations and statements in a clinically relevant order. "Recommendations" refer to practically-oriented treatment recommendations; "statements" contain important information which is not recommendatory in nature. These are marked with the indications "checked", "modified" or "new" and the consensus level is specified. "Checked" means that adjustments were not necessary. Evidence-based recommendations are additionally specified with evidence and recommendation levels (Table 1). A distinction is made between consensus-based (gray) and

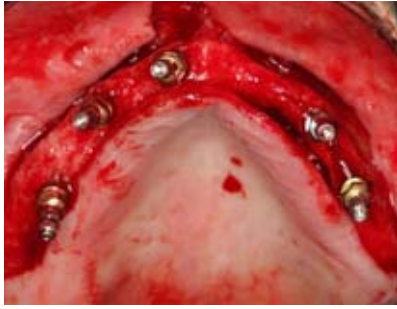evidence-based (blue) recommendations. Statements are marked in yellow.

The classification of consensus level according to the Association of the Scientific Medical Societies in Germany (AWMF) distinguishes between "strong consensus", "consensus", "majority agreement" and "no consensus". "Strong consensus" signifies that more than 95% of the participants are in agreement. "No consensus" denotes that less than 50% of the participants are in agreement.

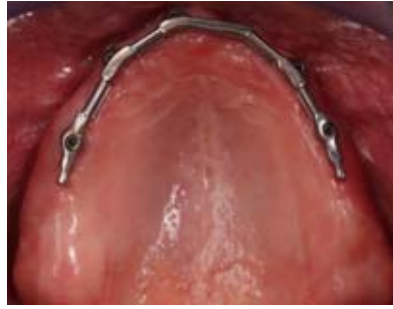The grading of recommendations is divided into 3 levels; it ranges from a "strong recommendation" (A) to a "recommendation" (B) to an "open recommendation" (C). "Strong recommendations" "should" be applied, while "recommendations" "may" be applied.

### 2.1. Recommendations for implant-prosthetic planning

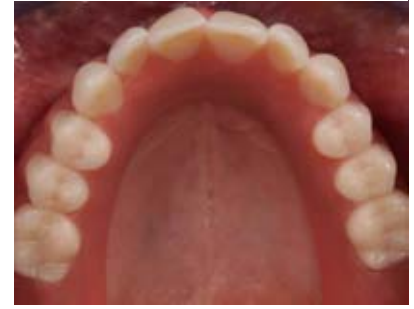The decision in favor of or against an implant-supported prosthetic restoration in the edentulous maxilla must always be made together with the patient. In this regard, when patients consider which restoration best suits their needs, they must be informed about the advantages and disadvantages of the various forms of treatment, as well as, the possible risks and complications associated



**Figure 1** Implant placement in regions 15, 13, 11, 23, 25.



**Figure 2** Screw-retained titanium bar on 5 implants in regions 15, 13, 11, 23, 25.



**Figure 3** Palate-free prosthesis design in situ.

(Figure 1–5, 8–10: Dr. Taskin Tuna; Figure 6, 7: Nizameddin Ayik)

with them. The prospective tooth positions are determined on this basis and the optimal implant positions can be derived accordingly. Moreover, necessary pre-prosthetic procedures are also derived based on this knowledge, especially with regard to bone augmentation forms, which in turn discloses important information for patient education and planning.

Another detail that should not be neglected is the patient's self-care requirements. This includes, among other things, the patient's ability to maintain an adequate oral hygiene and to attend regular follow-up appointments. An accurate assessment of whether the patient's motoric abilities permit the handling of a removable prosthesis is essential. The manual dexterity to insert the prosthesis as well as the existence of sufficient strength to remove the prosthesis should be considered.

| Consensus-based recommendation – modified  |                  |
|--|------------------|
| Detailed functional and esthetic planning is imperative, especially in the edentulous maxilla. Prosthetic planning should first take place in the sense of backward planning,<br>For this purpose, an existing prosthesis or a laboratory-fabricated prosthesis which reflects the future tooth set-up can be tried in and tested directly in the patient's mouth. | Strong consensus |
| Expert opinion   |                  |

| Consensus-based recommendation – new  |                  |
|---|------------------|
| In anatomically complex situations, it is usually advisable to take advantage of DVT imaging and to plan the treatment taking into account the tested tooth set-up. The transfer of the virtual planning using a guiding template for drilling can be useful in such cases. | Strong consensus |
| Expert opinion  |                  |

| Consensus-based recommendation – new   |                  |
|--|------------------|
| The patient's ability to handle any potential retention elements, to maintain an adequate oral hygiene and to attend regular follow-up appointments should be taken into account in the planning process. If there are reasonable doubts about the patient's compliance, implant-supported restorations should be questioned critically. | Strong consensus |
| Expert opinion   |                  |

| Statement – modified  |                  |
|---|------------------|
| The decision whether to use fixed or removable restorations depends on the specific patient-related circumstances and the patient's preference. | Strong consensus |
| Expert opinion  |                  |

| Consensus-based recommendation – new  |                  |
|---|------------------|
| An even anterior-posterior implant distribution in the sense of the largest possible support polygon in the area of the prosthesis should be aimed for. | Strong consensus |
| Expert opinion  |                  |

| Consensus-based recommendation – new  |                  |
|---|------------------|
| In patients with a fixed or removable implant-supported restoration in the edentulous maxilla, a regular check-up interval should be aimed for. Depending on the patient's compliance, and taking into account other individual patient-related factors, intervals between 3 and 12 months are generally considered reasonable. | Strong consensus |
| Expert opinion  |                  |

## 2.2. Recommendations regarding the number of implants and fixed or removable restoration concepts

The primary objective of the guideline was to answer the following key question: What is the appropriate number of implants for a given type of prosthesis in the edentulous maxilla? Due to the newly acquired evidence, the indications have been expanded, especially in the area of restorations on 4 implants. For more than 5 implants, the statements of the guideline have remained the same, but are included below for the sake of completeness.

Examples of clinical cases for a removable and a fixed restoration according to these recommendations can be found in Figures 1–10.

| Statement – new  |                  |
|--|------------------|
| The immediate loading of 4 or more implants with a provisional fixed restoration is possible if the primary stability of the implants is sufficient and the support polygon is sufficient according to strict indications. | Strong consensus |
| Expert opinion   |                  |

| Evidence-based recommendation – checked                               |  |
|---|--|
| Less than 4 implants should not be planned in the edentulous maxilla. |  |
| Level of evidence 2+/A  |  |

| Evidence-based recommendation – new  |                  |
|--|------------------|
| Both removable or fixed restorations are possible using 4 implants. (The recommendations are based on the currently available studies, which included fixed restorations with anterior axial and posterior angulated implant positions. The terminal implants were positioned in the premolar region or more posteriorly). | Strong consensus |
| Level of evidence 1+/A (removable); level of evidence 1+/B (fixed)   |                  |

| Statement – new   |                  |
|---|------------------|
| One of the concepts for immediate fixed restoration in the edentulous maxilla is a restoration using 4 implants with a combination of anterior axial and posterior angulated implants. This is a technique sensitive procedure, and in order for the procedure to be feasible, it requires strict patient selection, precise planning and clarifications that are specifically tailored to the procedure. | Strong consensus |
| Expert opinion  |                  |

| Evidence-based recommendation – checked                        |  |
|--|--|
| Removable or fixed restorations are possible using 5 implants. |  |
| Level of evidence: 2+/B  |  |
| Example, see Fig. 1–5  |  |

| Evidence-based recommendation – checked                        |  |
|--|--|
| Removable or fixed restorations are possible using 6 implants. |  |
| Level of evidence: 1+/A  |  |

| Consensus-based recommendation – checked   |  |
|--|--|
| Valid for 5 to 6 implants: In the case of fixed restorations, a one-piece implant-supported FPD can be screw-retained or cemented. |  |
| Expert opinion   |  |

| Evidence-based recommendation – checked                         |  |
|---|--|
| Removable or fixed restorations are possible using >6 implants. |  |
| Level of evidence 2+/B  |  |
| Example, see Fig. 6–10  |  |

| Consensus-based recommendation – checked  |  |
|---|--|
| For more than 6 implants, the following applies: if fixed restorations are used, single-unit or multi-unit restorations can be used. These can be screw-retained or cemented. |  |
| Expert opinion  |  |

### 2.3. Special recommendations for removable prostheses

In principle, as retaining elements for removable restorations, ball attachments, double crowns and bars can be used. In order to provide the practitioner with decision-making aids in this regard, the following consensus-based recommendations were made on the basis of the available literature.

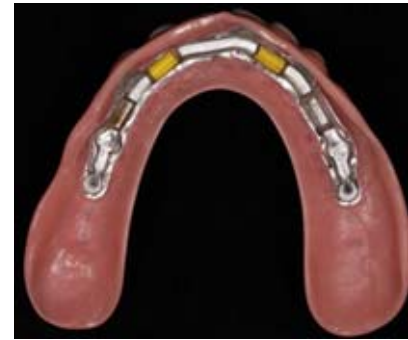

Figure 4 Basal view of the prosthesis with Preci-Horix attachments (yellow) and Preci-Vertex attachment units (white), both CEKA attachments, Preci-Line, Hannover.

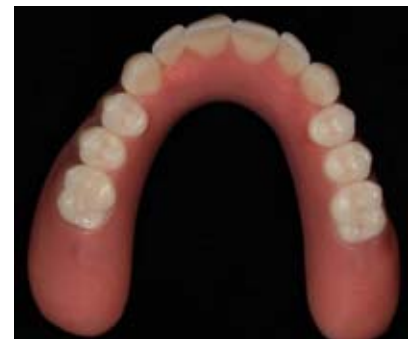

Figure 5 Occlusal view of the prosthesis.

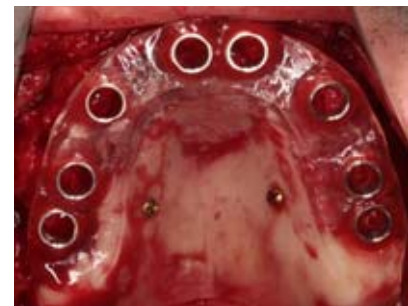

Figure 6 Drilling template fixed to the palate for fully guided implant placement.

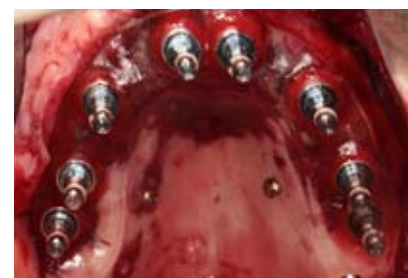
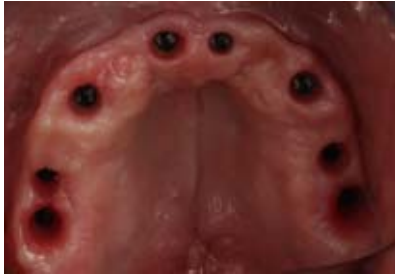
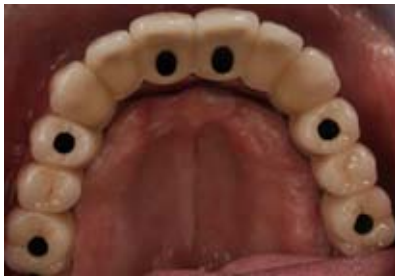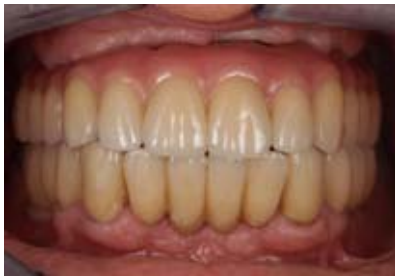Figure 7 Implant placement in regions 17, 16, 13, 11, 21, 23, 25, 26.



**Figure 8** View after removing the gingiva former; 8 implants in regions 17, 16, 13, 11, 21, 13, 25, 26.



**Figure 9** Screw-retained, one-piece FPD superstructure.



**Figure 10** Restoration placement in the maxilla and mandible.

**Consensus-based recommendation – new**

|  |                  |
|--|------------------|
| Ball-attachments, double crowns and bars are suitable retention elements for implant-supported removable prostheses. Due to the different properties of the retention elements, the respective advantages and disadvantages of these should be taken into account in designing a prosthesis. | Strong consensus |
|--|------------------|

Expert opinion

**Consensus-based recommendation – new**

|  |                  |
|--|------------------|
| In the case of strongly angulated implants, individually fabricated, implant-retained bar or double-crowns are particularly suitable as retention elements for removable prostheses. Ball attachments should only be used in these cases if they can compensate for physical angulation. | Strong consensus |
|--|------------------|

If additional stabilization of the implants by means of retention elements is desired, bar attachments are particularly suitable for this purpose due to primary splinting.

In the case of low or moderate vertical tissue loss and nearly parallel implant placement, standard ball attachments are also suitable for rehabilitating the edentulous maxilla.

Expert opinion

**Consensus-based recommendation (14) – new**

|   |                  |
|---|------------------|
| In order to reduce the complication rates of removable, implant-retained, palate-free prostheses in the maxilla, a framework should be integrated into every new prosthesis in order to ensure prosthesis stabilization (e.g. metal framework). | Strong consensus |
|---|------------------|

Expert opinion

**2.4. Special recommendations for fixed restorations**

When patients are rehabilitated using fixed restorations, one of the key decisions relates to the type of fixation that should be used, i.e. screw-retained or cemented. The current update also provides new consensus-based recommendations in order to give the practitioner an important decision-making aid in this regard (see also Fig. 6–10).

**Consensus-based recommendation – new**

|   |                  |
|---|------------------|
| Due to the risk of complications with fixed, one-piece, full-arch, implant-supported restorations, a safe and predictable removal and reinsertion of these restorations should be achieved. | Strong consensus |
|---|------------------|

Expert opinion

**Consensus-based recommendation – new**

|  |                  |
|--|------------------|
| For this reason, screw-retained fixation should be used for this (full-arch) type of restorations if it is technically feasible. | Strong consensus |
|--|------------------|

Expert opinion

**2.5. Recommendations regarding oral health-related quality of life**

An increasing number of studies take into account patient satisfaction, chewing ability and the change in the oral health-related quality of life which results after each respective treatment. As part of the 2019 update, the authors of the guideline used the chance to include the studies mentioned in the evidence table, provided that they supplied information relating to the above-mentioned points. Also, 2 noteworthy studies on the topic of patient satisfaction were identified [5, 14]. The existing clinical studies strongly support the fact that edentulous patients, who have been rehabilitated with implant-supported superstructures in the maxilla, are generally very satisfied with the restorative treatment.



| Consensus-based recommendation – new  |                  |
|---|------------------|
| In relation to the oral health-related quality of life, speech function (articulation ability), sensory function, and taste perception should be improved; this can be achieved by means of a palate-free design of the implant-retained removable prosthesis, provided that the implant distribution is favorable. | Strong consensus |
| Expert opinion  |                  |

| Statement – new   |                  |
|---|------------------|
| Rehabilitation using implant-retained removable or fixed restorations in the edentulous maxilla results in demonstrable improvements in the oral health-related quality of life of patients in comparison to the initial situation. | Strong consensus |
| Expert opinion  |                  |

### 3. Conclusion

The updated version of the guideline contains partly new, partly modified recommendations and statements regarding the following topics: required number of implants, timing of loading, treatment planning using DVT, patient compliance, prosthesis design/stabilization, selection of retention elements, full-arch restorations and oral health-related quality of life.

The rehabilitation of the edentulous maxilla with fixed or removable restorations, supported on 4 or more implants, is a reliable treatment option with high implant survival rates. The updated guideline substantiates the statement that no fewer than 4 implants should be placed in the edentulous maxilla.

### Conflicts of Interest

Jaana-Sofia Kern has received honoraria from the DGI for lead authorship

on the guideline. Stefan Wolfart has received honorarium and travel reimbursement from DGI for the functions and tasks of the guideline coordinator. Taskin Tuna has no conflict of interest within the meaning of the guidelines of the International Committee of Medical Journal Editors.

### References

1. SIGN 50: A line developer's handbook. <https://www.sign.ac.uk>: Health Care Improvement Scotland
2. Boven GC, Slot JWA, Raghoobar GM et al.: Maxillary implant-supported overdentures opposed by (partial) natural dentitions: a 5-year prospective case series study. *J Oral Rehabil* 2017; 44: 988–995
3. Cassetta M: Immediate loading of implants inserted in edentulous arches using multiple mucosa-supported stereolithographic surgical templates: a 10-year prospective cohort study. *Int J Oral Maxillofac Surg* 2016; 45: 526–534
4. Eerdekens L, Schols M, Coelst L et al.: A 5-year prospective study on cone-anchored implants in the edentulous maxilla. *Clin Implant Dent Relat Res* 2015; 17 (Suppl 2): e621–632
5. Erkapers M, Segerstrom S, Ekstrand K et al.: The influence of immediately loaded implant treatment in the atrophic edentulous maxilla on oral health related quality of life of edentulous patients: 3-year results of a prospective study. *Head Face Med* 2017; 13: 21
6. Gherlone EF, Sannino G, Rapanelli A et al.: Prefabricated bar system for immediate loading in edentulous patients: a 5-year follow-up prospective longitudinal study. *Biomed Res Int* 2018; 2018: 7352125
7. Kern JS, Wolfart S (2021): Implantatprothetische Versorgung des zahnlosen Oberkiefers. Stand: 30.11.2020 edn. [www.awmf.org](http://www.awmf.org).
8. Ma S, Waddell JN, Atieh MA et al.: Maxillary three-implant overdentures opposing mandibular two-implant overdentures: 10-year prosthodontic outcomes. *Int J Prosthodont* 2016; 29: 327–336
9. Slot W, Raghoobar GM, Cune MS et al.: Maxillary overdentures supported by four or six implants in the anterior region: 5-year results from a randomized controlled trial. *J Clin Periodontol* 2016; 43: 1180–1187
10. Slot W, Raghoobar GM, Cune MS et al.: Four or six implants in the maxillary posterior region to support an overdenture: 5-year results from a randomized controlled trial. *Clin Oral Implants Res* 2019; 30: 169–177
11. Tallarico M, Meloni SM, Canullo L et al.: Five-year results of a randomized controlled trial comparing patients rehabilitated with immediately loaded maxillary cross-arch fixed dental prosthesis supported by four or six implants placed using guided surgery. *Clin Implant Dent Relat Res* 2016; 18: 965–972
12. Tealdo T, Menini M, Bevilacqua M et al.: Immediate versus delayed loading of dental implants in edentulous patients' maxillae: a 6-year prospective study. *Int J Prosthodont* 2014; 27: 207–214
13. Toljanic JA, Ekstrand K, Baer RA et al.: Immediate loading of implants in the edentulous maxilla with a fixed provisional restoration without bone augmentation: a report on 5-year outcomes data obtained from a prospective clinical trial. *Int J Oral Maxillofac Implants* 2016; 31: 1164–1170
14. Zembic A, Tahmaseb A, Jung RE et al.: Patient-reported outcomes of maxillary edentulous patients wearing overdentures retained by two implants from insertion to 4 years. *Int J Oral Maxillofac Implants* 2019; 34: 481–488
15. Zhang XX, Shi JY, Gu YX, Lai HC: Long-term outcomes of early loading of Straumann implant-supported fixed segmented bridgeworks in edentulous maxillae: a 10-year prospective study. *Clin Implant Dent Relat Res* 2016; 18: 1227–1237



(Photo: Jaana-Sophia Kern)

Corresponding author:  
**DR. JAANA-SOPHIA KERN, M.SC.**  
 Department of Prosthodontics and  
 Dental Materials, Center for Implantology,  
 Medical Faculty,  
 RWTH Aachen University,  
 Pauwelsstr. 30  
 D-52074 Aachen  
 E-Mail: [jkern@ukaachen.de](mailto:jkern@ukaachen.de)

Edgar Schäfer, Bijan Vahedi, Bernard Bengs, Gabriel Krastl

# Endodontic pain management

## Position Paper of the German Society of Endodontology and Dental Traumatology

**Summary:** Pain of endodontic origin usually requires dental intervention as soon as possible. In the ideal case, this should represent the first step of regular dental treatment afterward.

Full pulpotomy without root canal instrumentation is the first-line therapy for managing pain in symptomatic irreversible pulpitis. In exceptional cases, complete root canal preparation with the placement of intracanal dressings can be performed. Both treatment approaches reliably result in freedom from pain within 24 hours. In the case of symptomatic apical periodontitis, the mechanical root canal preparation up to a size that permits irrigation of the canals over their entire length is required. If orthograde access to the periradicular tissue appears impossible or very risky (e.g. root canal filled tooth with an intracanal post or instrument fragment), the administration of analgesics with additional long-term anesthesia may be indicated in order to enable causal treatment the following day with sufficient treatment time. For acute periradicular abscesses, the primary goal of pain management is to ensure the adequate drainage of pus. A simple incision without the trepanation of the affected tooth does not represent an adequate causal therapy. In exceptional circumstances, when the trepanation of the tooth is not possible, it should ensue promptly (ideally within 24 hours) after the incision.

In the management of endodontic pain, medication can be considered as an adjunct to, but not a substitute for, the causal therapy indicated in each case.

**Keywords:** irreversible pulpitis, apical periodontitis, periradicular abscess, pulpotomy, trepanation

---

Central Interdisciplinary Outpatient Clinic, Münster University Hospital: Prof. Dr. Edgar Schäfer

Dental Clinic for Endodontics, Augsburg: Dr. Bijan Vahedi

Dental Clinic for Endodontics Berlin-Mitte: Dr. Bernard Bengs

Department for Conservative Dentistry and Periodontology, University Hospital Würzburg: Prof. Dr. Gabriel Krastl

Translation from German: Cristian Miron

**Citation:** Schäfer E, Vahedi B, Bengs B, Krastl G: Endodontic pain management. Dtsch Zahnärztl Z Int 2021; 3: 182–187

**Peer-reviewed article:** submitted: 29.04.2021, accepted: 03.05.2021

DOI.org/10.3238/dzz-int.2021.0021

## 1. Introduction

In principle, patients who experience tooth pain are legally entitled to dental treatment. Strictly speaking, pain of endodontic origin, with the exception of acute periradicular abscesses with the tendency to spread, does not represent an emergency, but it usually requires dental intervention as soon as possible [48].

Toothache is the most common pain presenting in the orofacial region [26]. Approximately 60% of toothaches are attributable to endodontic causes [51], and in 90% of cases, toothaches are caused by symptomatic pulpitis or apical periodontitis [8, 14]. Carious lesions are the main cause of these pathologies.

Pain afferents consist of slow, unmyelinated C- and fast, myelinated A $\beta$ -fibers [5], which are transmitted via the spinothalamic tract to the reticular formation. At this level, reflex responses of the body are triggered. In general, pain can be triggered by thermal, mechanical or chemical stimuli; in addition, so-called spontaneous pain also exists.

The treatment of the cause of pain should always be the primary focus of pain management. For this purpose, the cause of pain must be carefully determined and other possible causes must be excluded based on differential diagnoses (e.g. non-odontogenic pain). Moreover, in the management of pain, invasive treatment should not be performed without a reliable and well-founded diagnosis. Preferably, the diagnoses for the condition of the pulp and the periradicular tissue should be recorded separately. In general, a causal therapy should be chosen to alleviate the symptoms. The frequently observed practice of prescribing antibiotics alone without further corresponding treatment [22] is not indicated. Ideally, causal pain management should be the first step of the regular dental treatment afterward. Subsequent to pain management, if the definitive restoration was not placed on the affected tooth during the treatment of pain, the patient should be informed that further treatment will be required in the near future. The fact that the patient has been informed should be recorded.

In general, rubber dam should be used consistently to maintain aseptic working conditions, even in the context of pain management [43]. For the treatment concepts described below, the application of rubber dam provides protection against the aspiration or ingestion of instruments and/or irrigation solutions [4]. It also reduces the chance that invading microorganisms from the oral cavity spread into the endodontic space, thus contributing to an improved likelihood of treatment success [2, 16]. Furthermore, rubber dam reduces the average bacterial load in the aerosols due to treatment by 90–98% [9]. In this respect, rubber dam is considered one of the most effective methods for germ reduction in dental practice [12].

## 2. Symptomatic pulpitis

If the clinical and radiologic diagnoses indicate that vital pulp therapy appears possible [11, 25], trepanation of the affected tooth should not be considered a first-line therapy option, even in the context of pain management. Treatment measures in cases of “reversible pulpitis”, according to the classical system for diagnosing pulpal diseases, aim to remove the irritating noxa (mostly carious lesions and/or defective coronal restorations), while simultaneously preserving pulp vitality. In contrast, pulpal diseases that are classified as “irreversible pulpitis” require root canal treatment according to previous concepts.

### 2.1. Preservation of pulp vitality

#### Diagnosis:

- Pulp sensitivity test to cold: positive
- Stimuli that trigger pain: thermal, osmotic and tactile
- Pain duration corresponds to stimulus duration; no spontaneous pain
- Sharp, throbbing pain, mostly well localized

#### Treatment:

- Anesthesia
- Removal of irritating noxa: caries excavation, removal of leaky coronal restorations, sealing of exposed dentinal tubules [43]
- Covering of the deep dentin layer close to the pulp or vital pulp ther-

apy in case of pulp exposure using aqueous calcium hydroxide suspensions or a hydraulic calcium silicate cement [11, 13]

- Bacteria-tight coronal seal with definitive or provisional restoration

### 2.2. Preservation of pulp vitality is no longer possible

#### Diagnosis:

- Pulp sensitivity test to cold: positive; sometimes intensely positive
- Stimuli that trigger pain: heat
- Pain outlasts the duration of the stimulus; spontaneous pain, possibly permanent pain
- Pulsating, throbbing pain; frequently, its precise localization is difficult
- Pain at night
- Cold alleviates the pain

#### Basic emergency treatment:

- Anesthesia (ensure sufficient degree of anesthesia)
- Excavation of carious dentin if necessary [40]
- Trepanation of the affected tooth and full pulpotomy (removal of the coronal pulp) under aseptic conditions [29]
- No root canal instrumentation or extirpation of the radicular pulp [35]
- Irrigation of the pulp chamber with sodium hypochlorite and hemostasis
- Application of anti-inflammatory and pain-relieving medicament (corticosteroid & antibiotic paste; pure corticosteroid) [23]. The maximum time interval until further treatment is 4–6 weeks in the case of an adequate coronal seal [29].
- Bacteria-tight coronal seal; adhesive restoration is preferable if the maximum time interval until further treatment may be reached
- With regard to the effectiveness of pulpotomy as a definitive treatment, reference should be made to the current position paper of the German Society of Endodontology and Dental Traumatology (DGET) “Is pulpotomy a valid treatment option for irreversible pulpitis?” [25].

#### Enhanced emergency treatment:

In exceptional cases, complete root canal treatment with the placement of intracanal dressings can be performed [43, 48].

- Anesthesia; additional injection techniques (e.g. intraligamentary or intrapulpal anesthesia) may be required in order to achieve a sufficient level of anesthesia.
- Rubber dam
- Excavation of carious dentin if necessary [40]
- Trepanation and visualization of the root canal orifices
- Determination of the working length
- Complete extirpation of the radicular pulp and mechanical preparation of all root canals up to a size that allows irrigation of the canals over their entire working length (using hand instruments at least up to ISO size 30/35; using engine-driven nickel-titanium instruments at least up to size 25/4% taper) [52].
- Root canal irrigation and application of an intracanal dressing (preferably an aqueous calcium hydroxide suspension)
- Bacteria-tight coronal seal
- Reduction of occlusal contacts if necessary [3, 32]
- Analgesics if necessary (see below)

Using either treatment option, freedom from pain can be achieved in the patient within 24 hours in approximately 98–99% of cases [51].

### 3. Symptomatic apical periodontitis

#### Diagnosis:

- Pulp sensitivity test to cold: mostly negative
- Palpation: sometimes tenderness to pressure at the level of the root apex
- Radiologic imaging: mostly periradicular lesion or widened periodontal space
- Percussion test: positive
- Tooth mobility: sometimes increased in acute cases; tooth may be elongated.
- Pain anamnesis: pain on biting and on touch; sometimes constant pain

#### 3.1. Teeth with apical periodontitis and no root canal filling

Symptomatic apical periodontitis is a purulent inflammation that is caused by an infection of the root canal sys-

tem. In this respect, causal treatment must aim to immediately eliminate the cause (infected necrotic pulp tissue) [43].

- Anesthesia if necessary (if the tooth is very sensitive to touch)
- Rubber dam
- Excavation of carious dentin if necessary [40]
- Trepanation and visualization of root canal orifices
- Determination of the working length
- Mechanical preparation of all root canals up to a size that allows irrigation of the root canals over their entire working length (using hand instruments at least up to ISO size 30/35; using engine-driven nickel-titanium instruments at least up to size 25/4% taper) [52].
- Root canal irrigation and application of an intracanal dressing (preferably an aqueous calcium hydroxide suspension)
- Bacteria-tight coronal seal
- Reduction of the occlusal contacts if necessary [3, 32, 41]
- Analgesics if necessary (see below)

#### 3.2. Teeth with already filled root canals and apical periodontitis

Even in the case of an already root canal filled tooth, the cause is either a persistent or newly occurring (re)infection of the root canal system. In this respect, causal treatment is no different than the procedure described previously [43].

- Anesthesia if necessary (if the tooth is very sensitive to touch)
- Rubber dam
- Complete excavation of carious dentin if necessary [40]
- Repeated trepanation and visualization of the root canal filling
- Removal of the root canal filling: if the root canal system responsible for the acute symptoms can be identified with sufficient probability based on radiologic imaging (e.g. only one root is associated with a periradicular lesion), only the retreatment of all of the canal systems in the respective root may be sufficient as the first-line pain treatment.
- Further procedure analogous to first-line treatment

If orthograde access to the periradicular tissue appears impossible or too risky (e.g. intracanal posts, instrument fragments), the administration of an analgesic (see below) with additional long-term anesthesia (e.g. bupivacaine) may be indicated in order to permit causal treatment the following day along with sufficient treatment time [23, 30, 37, 39].

### 4. Acute periradicular abscess

#### Diagnosis:

- Pulp sensitivity test to cold: negative
- Extraoral and/or intraoral swelling
- Radiologic imaging: mostly periradicular lesion or widened periodontal space
- Percussion test: positive
- Tooth mobility: sometimes increased; tooth may be extruded
- Pain anamnesis: pain on biting and on touch; persistent and tense pain
- Restricted mouth opening is possible, complaints when swallowing
- The patient's general health condition is possibly impaired (fever, circulatory system complaints)

#### 4.1. Teeth with acute periradicular abscess and no root canal filling

#### Treatment:

Besides causal treatment to eliminate the cause (infected necrotic pulp tissue), drainage to ensure adequate pus discharge constitutes a primary goal of pain management [42]. A meta-analysis indicates that immediate drainage is the first-line treatment [28]. Drainage can be established through the affected tooth and/or through an incision. An exclusive incision without the trepanation of the affected tooth does not represent adequate causal therapy. If the tooth's trepanation is not possible immediately, in exceptional cases (e.g. severely restricted mouth opening), it should be performed promptly (ideally within 24 hours) after the incision [48].

- Anesthesia because of the mostly pronounced sensitivity of the tooth to touch [8]
- Rubber dam
- Excavation of carious dentin if necessary [40]

- Trepanation and access to the root canal orifices: often, pus spontaneously flows out of the endodontium afterward. If the pus does not drain, thin, sterile instruments (ISO sizes 08 to 15) can be used to widen the apical root canal segment, so as to allow the pus to flow out. However, deliberate over-instrumentation should be avoided [7, 8].
- Determination of the working length
- Mechanical preparation of all root canals up to a size that allows irrigation of the root canals over their entire working length (using hand instruments at least up to ISO size 30/35; using engine-driven nickel-titanium instruments at least up to size 25/4% taper) [52]. The crown-down technique of preparation is preferable in order to reduce the incidence of undesired extrusion of infected canal contents into the periradicular tissue [43].
- Large-volume root canal irrigation (cave: the high risk of apical extrusion of irrigants should be taken into account)
- Drying of the root canal to check if exudation from the endodontium has subsided. An intracanal dressing is applied (preferably an aqueous calcium hydroxide suspension).
- Bacteria-tight coronal seal
- Reduction of the occlusal contacts [3, 32, 41].
- Adjunctive analgesics if necessary (see below)

In exceptional cases, in which the exudation of pus or secretions from the endodontium does not subside within approximately 15–20 minutes, consideration may be given to leave the tooth open for a maximum of 24 hours notwithstanding the general recommendations [40, 48]. In order to avoid the problem of biofilm formation in the endodontium due to the migration of microorganisms from the oral cavity, which is subsequently difficult or impossible to remove, chemo-mechanical preparation of all root canals in combination with the necessary bacteria-tight coronal seal should be performed within the subsequent 24 hours. Routinely leaving a tooth open or leaving it open for a longer period of time must be avoided at all costs [42].

Trephination (so-called Schröder ventilation) does not represent an adequate pain management solution for non-vital teeth associated with periradicular inflammation [21, 33].

Extensive odontogenic abscesses, especially in combination with the patient's general feeling of malaise (e.g. fever), may be an indication for hospitalization [40, 42].

#### 4.2. Teeth with already filled root canals and acute periradicular abscess

Also in this scenario, the primary therapeutic goal is the need to establish drainage. If, as described in 3.2, orthograde access to the periapical tissue appears to be possible with an acceptable amount of effort – again limited to the canal system responsible for the periradicular abscess if necessary – the further treatment procedure after removal of the root canal filling corresponds to that of first-line treatment.

In exceptional cases which are well-warranted, an initial incision of the abscess may be considered. The treatment can then be continued within the next 24 hours in the form of an orthograde retreatment or necessary surgical measures (e.g., apicoectomy, extraction) [15, 43]. Since the cause is not treated immediately in these exceptional cases, care must be taken to ensure adequate incision depth and length; if necessary, additional drainage of the incision via strips, rubber bands, or tubes is recommendable. In the maxilla, care should be taken to ensure that the incision does not hinder any plastic covering that may potentially be required after a subsequent extraction of the affected tooth. In addition, the administration of analgesics (see below) with supplementary long-term anesthesia (e.g., bupivacaine) may be indicated to bridge the short time interval until the initiation of causal treatment [23, 30, 37, 39].

#### 5. Adjunctive drug therapy

Any adjunctive drug therapy – even under the greatest time pressure – must not be regarded as a substitute for the causal treatment that is indicated in each respective case. In endodontic pain management, drugs

can be a supplement, but never the sole treatment [23, 48].

#### 5.1. Antibiotics

Pain per se is never an indication for antibiotic administration [18]. There is no evidence to support that antibiotics relieve pain in the treatment of symptomatic pulpitis [20] or symptomatic apical periodontitis [10].

Localized odontogenic infections with no tendency to spread, in which drainage of the pus could be established, are not an indication for antibiotic administration, as long as general health-related risk factors do not exist [42]. If the risk for abscessing infections to disseminate along communicating spaces exists (e.g. fossa canina, perimandibular, submandibular or perimandibular space abscesses), the additional use of systemic antibiotics in endodontic pain management is warranted [1, 42, 44]. This also applies when fever (temperature >38 °C), trismus, swallowing difficulties, or general health-related risk factors are present [42, 44].

The antibiotics of choice are penicillin or amoxicillin, whereas in cases of a penicillin allergy, clindamycin may be used [42]. In severe cases or abscesses with the tendency to spread, the combination of an aminopenicillin and a beta-lactamase inhibitor (amoxicillin/clavulanic acid) is the drug of choice [42]. This preparation should also be prescribed when an odontogenic infection has already been treated previously with a penicillin or aminopenicillin and no beta-lactamase inhibitor [42].

#### 5.2. Analgesics

As part of adjuvant therapy in causal pain management, nonsteroidal anti-inflammatory drugs (NSAIDs) represent the analgesics of first choice for several reasons [6, 19, 47]. In both symptomatic pulpitis as well as symptomatic apical periodontitis, prostaglandins in particular are considered to be the chief inflammatory mediators responsible for the development of pain. NSAIDs are very effective at inhibiting prostaglandin synthesis [19]. Ibuprofen seems to have the greatest efficacy of all NSAIDs when it comes to the management of pain [36].

When metamizole (Novalgin) is administered, it should be taken into consideration that agranulocytosis can occur in 1:1439 prescriptions, with a lethality of approximately 23% [24].

The administration of 400–600 mg ibuprofen 30–60 minutes before performing an inferior alveolar nerve block significantly increases the depth of anesthesia according to several meta-analyses [31, 38, 46]. It has been suggested that the administration of 600 mg appears to be superior to 400 mg [31].

### 5.3. Glucocorticoids

Meta-analyses have corroborated that the systemic administration of corticosteroids (e.g. dexamethasone p.o. or as a local injection) is suitable for preventing postoperative pain in symptomatic pulpitis, as corticosteroids reduce pain significantly for up to 24 hours after treatment [34, 45, 49]. Moreover, a randomized double-blind study demonstrates a significant reduction of pain for up to 24 hours after the treatment of symptomatic apical periodontitis [50].

It is important to note that glucocorticoids are not allowed to be administered in combination with NSAIDs since their combination significantly increases the side effects of glucocorticoids and results in an increased risk of gastrointestinal bleeding and ulceration [17, 27].

### Conflicts of Interest

The authors declare that there is no conflict of interest within the meaning of the guidelines of the International Committee of Medical Journal Editors.

### References

- AAE: AAE Position Statement: AAE Guidance on the Use of Systemic Antibiotics in Endodontics. *J Endod* 2017; 43: 1409–1413
- Ahmad IA: Rubber dam usage for endodontic treatment: a review. *Int Endod J* 2009; 42: 963–972
- Ahmed YE, Emara RS, Sarhan SM et al.: Post-treatment endodontic pain following occlusal reduction in mandibular posterior teeth with symptomatic irreversible pulpitis and sensitivity to percussion: a single-centre randomized controlled trial. *Int Endod J* 2020; 53: 1170–1180
- Alrahabi M, Zafar MS, Adanir N: Aspects of Clinical Malpractice in Endodontics. *Eur J Dent* 2019; 13: 450–458
- Bender IB: Pulpal pain diagnosis – a review. *J Endod* 2000; 26: 175–179
- Biddle C: Meta-analysis of the effectiveness of nonsteroidal anti-inflammatory drugs in a standardized pain model. *AANA J* 2002; 70: 111–114
- Borges Silva EA, Guimaraes LS, Kuchler EC et al.: Evaluation of Effect of Foraminal Enlargement of Necrotic Teeth on Postoperative Symptoms: A Systematic Review and Meta-analysis. *J Endod* 2017; 43: 1969–1977
- Carrotte P: Endodontics: Part 3. Treatment of endodontic emergencies. *Br Dent J* 2004; 197: 299–305
- Cochran MA, Miller CH, Sheldrake MA: The efficacy of the rubber dam as a barrier to the spread of microorganisms during dental treatment. *J Am Dent Assoc* 1989; 119: 141–144
- Cope AL, Francis N, Wood F, Chestnutt IG: Systemic antibiotics for symptomatic apical periodontitis and acute apical abscess in adults. *Cochrane Database Syst Rev* 2018; 9: CD010136
- Dammaschke T, Galler KM, Krastl G: Aktuelle Empfehlungen zur Vitalerhaltung der Pulpa. *Dtsch Zahnärztl Z* 2019; 74: 40–49
- Day CJ, Sandy JR, Ireland AJ: Aerosols and splatter in dentistry – a neglected menace? *Dent Update* 2006; 33: 601–602, 604–606
- Duncan HF, Galler KM, Tomson PL et al.: European Society of Endodontology position statement: Management of deep caries and the exposed pulp. *Int Endod J* 2019; 52: 923–934
- Estrela C, Guedes OA, Silva JA et al.: Diagnostic and clinical factors associated with pulpal and periapical pain. *Braz Dent J* 2011; 22: 306–311
- European Society of Endodontology: Qualitätsrichtlinien endodontischer Behandlungen. *Endodontie* 2006; 15: 387–401
- Frangenberg F, Schäfer E: Gibt es Evidenz für die Anwendung von Kofferdam? Eine Literaturrecherche. *Endodontie* 2012; 21: 287–297
- Gelbe\_Liste (2021): <https://www.gelbe-liste.de/wirkstoffgruppen/nichtsteroidale-antiphlogistika-antirheumatika>
- Henry M, Reader A, Beck M: Effect of penicillin on postoperative endodontic pain and swelling in symptomatic necrotic teeth. *J Endod* 2001; 27: 117–123
- Holstein A, Hargreaves K, Niederman R: Evaluation of NSAIDs for treating post-endodontic pain. A systematic review. *Endodontic Topics* 2002; 3: 3–13
- Hoskin E, Veitz-Keenan A: Antibiotics are not useful to reduce pain associated with irreversible pulpitis. *Evid Based Dent* 2016; 17: 81–82
- Houck V, Reader A, Beck M et al.: Effect of trephination on postoperative pain and swelling in symptomatic necrotic teeth. *Oral Surg Oral Med Oral Pathol Oral Radiol Endod* 2000; 90: 507–513
- Hussein R, Krohn R, Wilms G: Systemische adjuvante Antibiotikagabe bei Wurzelkanalbehandlungen, Zahnextraktionen und Notfallleistungen in der zahnärztlichen Versorgung bei gesetzlich Versicherten in Deutschland. *Dtsch Zahnärztl Z* 2018; 73: 22–28
- Keiser K, Hargreaves K: Building effective strategies for the management of endodontic pain. *Endodontic Topics* 2002; 3: 93–105
- Kötter T, da Costa BR, Fassler M et al.: Metamizole-associated adverse events: a systematic review and meta-analysis. *PLoS One* 2015; 10: e0122918
- Krastl G, Galler K, Dammaschke T, Schäfer E: Ist die Pulpotomie eine valide Behandlungsoption bei irreversibler Pulpitis? Wissenschaftliche Mitteilung der Deutschen Gesellschaft für Endodontology und zahnärztliche Traumatologie (DGET). *Dtsch Zahnärztl Z* 2021; 76: 20–28
- Lipton JA, Ship JA, Larach-Robinson D: Estimated prevalence and distribution of reported orofacial pain in the United States. *J Am Dent Assoc* 1993; 124: 115–121
- Marshall J: Consideration of steroids for endodontic pain. *Endodontic Topics* 2002; 3: 41–51
- Matthews DC, Sutherland S, Basrani B: Emergency management of acute apical abscesses in the permanent dentition: a systematic review of the literature. *J Can Dent Assoc* 2003; 69: 660
- Molander A, Nilsson A, Reit C: Ergebnisse endodontischer Schmerzbehandlung. *Endodontie* 2004; 13: 337–346
- Moradi S, Naghavi N: Comparison of bupivacaine and lidocaine use for postoperative pain control in endodontics. *Iran Endod J* 2010; 5: 31–35
- Nagendrababu V, Pulikkotil SJ, Veettil SK et al.: Effect of Nonsteroidal Anti-inflammatory Drug as an Oral Premedication on the Anesthetic Success of Inferior Alveolar Nerve Block in Treatment of Irreversible Pulpitis: A Systematic Re-

view with Meta-analysis and Trial Sequential Analysis. *J Endod* 2018; 44: 914–922 e912

32. Nguyen D, Nagendrababu V, Pulikkotil SJ, Rossi-Fedele G: Effect of occlusal reduction on postendodontic pain: A systematic review and meta-analysis of randomised clinical trials. *Aust Endod J* 2020; 46: 282–294

33. Nist E, Reader A, Beck M: Effect of apical trephination on postoperative pain and swelling in symptomatic necrotic teeth. *J Endod* 2001; 27: 415–420

34. Nogueira BML, Silva LG, Mesquita CRM et al.: Is the Use of Dexamethasone Effective in Controlling Pain Associated with Symptomatic Irreversible Pulpitis? A Systematic Review. *J Endod* 2018; 44: 703–710

35. Oguntebi BR, DeSchepper EJ, Taylor TS et al.: Postoperative pain incidence related to the type of emergency treatment of symptomatic pulpitis. *Oral Surg Oral Med Oral Pathol* 1992; 73: 479–483

36. Oxford League Table of Analgesic Efficacy: <http://www.bandolier.org.uk/booth/painpag/Acutrev/Analgesics/lftab.html>. 2021

37. Parirokh M, Yosefi MH, Nakhaee N et al.: Effect of bupivacaine on postoperative pain for inferior alveolar nerve block anesthesia after single-visit root canal treatment in teeth with irreversible pulpitis. *J Endod* 2012; 38: 1035–1039

38. Pulikkotil SJ, Nagendrababu V, Veettil SK et al.: Effect of oral premedication on the anaesthetic efficacy of inferior alveolar nerve block in patients with irreversible pulpitis – A systematic review and network meta-analysis of randomized controlled trials. *Int Endod J* 2018; 51: 989–1004

39. Reader A, Nusstein J: Local anesthesia for endodontic pain. *Endod Topics* 2002; 3: 14–30

40. Rosenberg PA: Clinical strategies for managing endodontic pain. *Endodontic Topics* 2002; 3: 78–92

41. Rosenberg PA, Babick PJ, Schertzer L, Leung A: The effect of occlusal reduction on pain after endodontic instrumentation. *J Endod* 1998; 24: 492–496

42. S3-Leitlinie Odontogene Infektionen 2017 10 17: <https://secure.owidi.de/documents/10165/1373255/odontinfektlang.pdf/26cf350e-5930-4a65-a71b-00dd8abea402>

43. Schäfer E: Die Therapie endodontischer Notfälle. Quintessenz, Berlin 2008

44. Segura-Egea JJ, Gould K, Sen BH et al.: European Society of Endodontology position statement: the use of antibiotics in endodontics. *Int Endod J* 2018; 51: 20–25

45. Shamszadeh S, Shirvani A, Eghbal MJ, Asgary S: Efficacy of Corticosteroids on Postoperative Endodontic Pain: A Systematic Review and Meta-analysis. *J Endod* 2018; 44: 1057–1065

46. Shirvani A, Shamszadeh S, Eghbal MJ et al.: Effect of preoperative oral analgesics on pulpal anesthesia in patients with irreversible pulpitis – a systematic review and meta-analysis. *Clin Oral Investig* 2017; 21: 43–52

47. Smith EA, Marshall JG, Selph SS et al.: Nonsteroidal Anti-inflammatory Drugs for Managing Postoperative Endodontic Pain in Patients Who Present with Preoperative Pain: A Systematic Review and Meta-analysis. *J Endod* 2017; 43: 7–15

48. Sonntag D. Sonntag D und der Vorstand der AGET: Behandlung endodontischer Schmerzfälle. Gemeinsame Stellungnahme der Arbeitsgruppe Endodontologie und Traumatologie/AGET der Deutschen Gesellschaft für Zahnerhaltung/DGT und der Deutschen Gesellschaft für Zahn-, Mund- und Kieferheil-

kunde/DGZMK. *Dtsch Zahnärztl Z* 2007; 62: 536–538

49. Suneelkumar C, Subha A, Gogala D: Effect of Preoperative Corticosteroids in Patients with Symptomatic Pulpitis on Postoperative Pain after Single-visit Root Canal Treatment: A Systematic Review and Meta-analysis. *J Endod* 2018; 44: 1347–1354

50. Suresh N, Nagendrababu V, Koteeswaran V et al.: Effect of preoperative oral administration of steroids in comparison to an anti-inflammatory drug on postoperative pain following single-visit root canal treatment – a double-blind, randomized clinical trial. *Int Endod J* 2021; 54: 198–209

51. Tronstad L: Endodontic emergency treatment. In: Tronstad L (Hrsg): *Clinical Endodontics*. Thieme, Stuttgart 2003, 141–145

52. Zehnder M: Root canal irrigants. *J Endod* 2006; 32: 389–398



(Photo: UKM)

**PROF. DR. EDGAR SCHÄFER**  
University Clinic for Dental Medicine  
Polyclinic for Dental Preservation  
Waldeyerstr. 30, 48149 Münster,  
Germany  
[eschaef@uni-muenster.de](mailto:eschaef@uni-muenster.de)



(Photo: Bijan Vahedi)

**DR. BIJAN VAHEDI**  
Dental Clinic for Endodontics  
Philippine-Welser-Straße 19  
86150 Augsburg  
Germany  
E-Mail: [info@vahedi.de](mailto:info@vahedi.de)



(Photo: Hoffotografen, Berlin)

**DR. BERNARD BENGS**  
Dental Clinic for Endodontics  
Berlin-Mitte  
Voxstraße 1, 10785 Berlin  
Germany  
[dr.bengs@endodontie-berlin-mitte.de](mailto:dr.bengs@endodontie-berlin-mitte.de)



(Photo: Gabriel Krastl)

**PROF. DR. GABRIEL KRASTL**  
Department for Conservative Dentistry  
and Periodontology  
University Hospital Würzburg  
Pleicherwall 2, 97070 Würzburg  
Germany  
[Krastl\\_G@ukw.de](mailto:Krastl_G@ukw.de)

**DZZ International**  
**German Dental Journal International**

**Publishing Institution**

International Journal of the German Society of Dentistry and Oral Medicine/Deutsche Gesellschaft für Zahn-, Mund- und Kieferheilkunde e.V. (Zentralverein, gegr. 1859), Liesegangstr. 17a, 40211 Düsseldorf, Phone: +49 211 610198-0, Fax: +49 211 610198-11

**Affiliations**

German Society of Periodontology (DG PARO)  
 German Society for Prosthetic Dentistry and Biomaterials  
 German Association for Conservative Dentistry  
 German Society of Craniomandibular Function and Disorders in the DGZMK  
 German Society of Paediatric Dentistry  
 German Academy of Oral and Maxillofacial Surgery  
 German Association of Dento-Maxillo-Facial Radiology (GSDOM)  
 German Academy of Dental Ergonomics  
 Group of Basic Science in Dentistry

**Editors**

Prof. Dr. Guido Heydecke  
 Editor in Chief | DZZ International  
 Chairman Department of Prosthetic Dentistry  
 University Medical Center Hamburg-Eppendorf  
 Martinistraße 52 | 20246 Hamburg  
 Phone +49 (0) 40 7410-53261  
 Fax +49 (0) 40 7410-54096

Prof. Dr. Werner Geurtsen  
 Editor | DZZ International  
 Chairman, Department of Conservative Dentistry, Periodontology and Preventive Dentistry  
 Hannover Medical School  
 Carl-Neuberg-Str. 1 | 30625 Hannover  
 Phone +49 (0) 511 532481-6  
 Fax +49 (0) 511 532481-1

**Associate Editors**

Prof. Nico H.J. Creugers, D.D.S., PH.D., Nijmegen/NL  
 Prof. Dr. Henrik Dommisch, Berlin/GER

Prof. Dr. Dr. Marco Rainer Kesting, Erlangen/GER  
 Prof. Dr. Torsten Mundt, Greifswald/GER  
 Prof. Dr. Falk Schwendicke, Berlin/GER  
 Univ.-Prof. Dr. med. dent. Michael Wolf, M.Sc., Aachen/GER

**Publisher**

Deutscher Ärzteverlag GmbH  
 Dieselstr. 2, 50859 Köln;  
 Postfach 40 02 65, 50832 Köln  
 Phone: +49 2234 7011-0; Fax: +49 2234 7011-6508  
 www.aerzteverlag.de

**Executive Board**

Jürgen Führer, Patric Tongbhoyai

**Product Management**

Carmen Ohlendorf, Phone: +49 02234 7011-357;  
 Fax: +49 2234 7011-6357;  
 ohlendorf@aerzteverlag.de

**Editorial Office**

Susanne Neumann, Phone: +49 2234 7011-219,  
 neumann.extern@aerzteverlag.de  
 Thomas Volmert, Phone: +49 2234 7011-253,  
 volmert@aerzteverlag.de

**Frequency**

6 times a year

**Layout**

Larissa Arts

**Account**

Deutsche Apotheker- und Ärztebank, Köln,  
 Kto. 010 1107410 (BLZ 370 606 15),  
 IBAN: DE 2830 0606 0101 0110 7410,  
 BIC: DAAEEDDD,  
 Postbank Köln 192 50-506 (BLZ 370 100 50),  
 IBAN: DE 8337 0100 5000 1925 0506,  
 BIC: PBNKDEFF

3. Volume  
 ISSN 2627-3489

**Copyright and Right of Publication**

Diese Publikation ist urheberrechtlich geschützt und alle Rechte sind vorbehalten. Diese Publikation darf daher außerhalb der Grenzen des Urheberrechts ohne vorherige, ausdrückliche, schriftliche Genehmigung des Verlages weder vervielfältigt noch übersetzt oder transferiert werden, sei es im Ganzen, in Teilen oder irgendeiner anderen Form. Die Wiedergabe von Warenbezeichnungen, Handelsnamen und sonstigen Kennzeichen in dieser Publikation berechtigt nicht zu der Annahme, dass diese frei benutzt werden dürfen. Zumeist handelt es sich dabei um Marken und sonstige geschützte Kennzeichen, auch wenn sie nicht als solche bezeichnet sind.

**Disclaimer**

Die in dieser Publikation dargestellten Inhalte dienen ausschließlich der allgemeinen Information und stellen weder Empfehlungen noch Handlungsanleitungen dar. Sie dürfen daher keinesfalls ungeprüft zur Grundlage eigenständiger Behandlungen oder medizinischer Eingriffe gemacht werden. Der Benutzer ist ausdrücklich aufgefordert, selbst die in dieser Publikation dargestellten Inhalte zu prüfen, um sich in eigener Verantwortung zu versichern, dass diese vollständig sind sowie dem aktuellen Erkenntnisstand entsprechen und im Zweifel einen Spezialisten zu konsultieren. Verfasser und Verlag übernehmen keinerlei Verantwortung oder Gewährleistung für die Vollständigkeit, Richtigkeit und Aktualität der in dieser Publikation dargestellten Informationen. Haftungsansprüche, die sich auf Schäden materieller oder ideeller Art beziehen, die durch die Nutzung oder Nichtnutzung der in dieser Publikation dargestellten Inhalte oder Teilen davon verursacht werden, sind ausgeschlossen, sofern kein nachweislich vorsätzliches oder grob fahrlässiges Verschulden von Verfasser und/oder Verlag vorliegt.

© Copyright by Deutscher Ärzteverlag GmbH, Köln